



HAL
open science

First case of subcutaneous cystic phaeohyphomycosis due to *Phialophora chinensis* in a kidney transplant recipient in Martinique

Clément Pruvot, Anne Laure Messagier, Dea Garcia-Hermoso, Frédéric Lebailly, Cédric Aglae, Nicole Desbois-Nogard

► To cite this version:

Clément Pruvot, Anne Laure Messagier, Dea Garcia-Hermoso, Frédéric Lebailly, Cédric Aglae, et al.. First case of subcutaneous cystic phaeohyphomycosis due to *Phialophora chinensis* in a kidney transplant recipient in Martinique. *Medical Mycology Case Reports*, 2023, 39, pp.18-22. 10.1016/j.mmcr.2022.12.003 . pasteur-04173128

HAL Id: pasteur-04173128

<https://pasteur.hal.science/pasteur-04173128>


Submitted on 28 Jul 2023

HAL is a multi-disciplinary open access archive for the deposit and dissemination of scientific research documents, whether they are published or not. The documents may come from teaching and research institutions in France or abroad, or from public or private research centers.

L'archive ouverte pluridisciplinaire **HAL**, est destinée au dépôt et à la diffusion de documents scientifiques de niveau recherche, publiés ou non, émanant des établissements d'enseignement et de recherche français ou étrangers, des laboratoires publics ou privés.



Distributed under a Creative Commons Attribution - NonCommercial - NoDerivatives 4.0 International License



First case of subcutaneous cystic phaeohyphomycosis due to *Phialophora chinensis* in a kidney transplant recipient in Martinique

Clément Pruvot^{a,*}, Anne Laure Messagier^{a,1}, Dea Garcia-Hermoso^{b,1}, Frédéric Lebailly^c, Cédric Aglae^d, Nicole Desbois-Nogard^e

^a Dermatology Department, Pierre-Zobda-Quitman Hospital, CHU Martinique, BP 636, 927261, Fort de France, cedex, Martinique

^b Institut Pasteur, Université Paris Cité, CNRS UMR2000, Unité de Mycologie Moléculaire, F-75015, Paris, France

^c Orthopedic Surgery Department, Clinique Saint-Paul, 97200, Fort de France, Martinique

^d Department of Nephrology, CHU Martinique, BP 636, 927261, Fort de France, cedex, Martinique

^e Parasitology-Mycology Laboratory, Pierre-Zobda-Quitman Hospital, CHU Martinique, BP 636, 927261, Fort de France, cedex, Martinique

ARTICLE INFO

Handling Editor: Adilia Warris

Keywords:

Phaeohyphomycosis
Phialophora chinensis
 Subcutaneous cyst
 Martinique
 Immunosuppression
 Kidney transplant

ABSTRACT

We report a case of subcutaneous mycosis in the form of a subcutaneous cyst of the index finger, successfully treated by surgery and posaconazole in an 84-year-old female kidney transplant patient. Intra-operative mycological analysis enabled the diagnosis of *Phialophora chinensis* phaeohyphomycosis. *Phialophora chinensis* is an environmental mold recently described in human pathology in cases of chromoblastomycosis. This is the first case of subcutaneous phaeohyphomycosis due to *Phialophora chinensis* in an immunocompromised patient.

1. Introduction

Some opportunistic fungi for humans are melanized, known as “dematiaceae”. These fungi are distinguished by the presence of melanin in their cell wall, which is thought to act as a virulence factor [1]. These fungi can be responsible for a spectrum of heterogeneous diseases ranging from localized skin diseases to potentially lethal infections involving the central nervous system [2]. The subcutaneous form of infection is the most common clinical presentation. It mimics benign skin and soft tissue tumors such as lipomas, sebaceous cysts or neurofibromas [3,4]. The incidence of phaeohyphomycosis is increasing, especially in solid organ transplant patients [5,6]. The most frequently involved genus is *Alternaria*, but many other species can be isolated (e.g. *Exophiala* spp., *Phialophora* spp., coelomycetes) [7,8]. We present the first documented case of subcutaneous phaeohyphomycosis due to *Phialophora chinensis*.

2. Case

An 84 year-old female patient from Martinique, in good general condition, was referred to a dermatology consultation for the management of a finger nodule recurring despite surgical excision (Fig. 1).

Her primary history was end-stage kidney disease due to nephropathy of unknown origin. She had undergone kidney transplantation in 2017, and was receiving anti-rejection immunosuppressive therapy with tacrolimus (5mg twice daily), mycophenolate (360mg twice daily), and prednisone (5mg once daily). Her medical history reported a wound on the right index finger after being pricked with a thorn from a plant while gardening. The wound did not heal despite local care, and a digital X-ray was performed, showing no particular abnormality. Three months later (day 0), a painless, non-inflammatory nodule appeared, and was surgically removed. The intraoperative appearance was a well-limited “cold” abscess containing a purulent brownish fluid. The biopsy fragments were sent to the pathology and bacteriology laboratories, with the hypothesis of a bacterial or mycobacterial infection. Histological examination revealed an suppurative inflammatory granuloma rich in

* Corresponding author. Service de dermatologie, CHU Lille, 2 Avenue Oscar Lambret, 59000 Lille, France.

E-mail address: clement.pruvot.etu@univ-lille.fr (C. Pruvot).

¹ These authors contributed equally.

<https://doi.org/10.1016/j.mmcr.2022.12.003>

Received 15 November 2022; Received in revised form 10 December 2022; Accepted 15 December 2022

Available online 25 December 2022

2211-7539/© 2022 The Authors. Published by Elsevier B.V. on behalf of International Society for Human and Animal Mycology. This is an open access article under the CC BY-NC-ND license (<http://creativecommons.org/licenses/by-nc-nd/4.0/>).

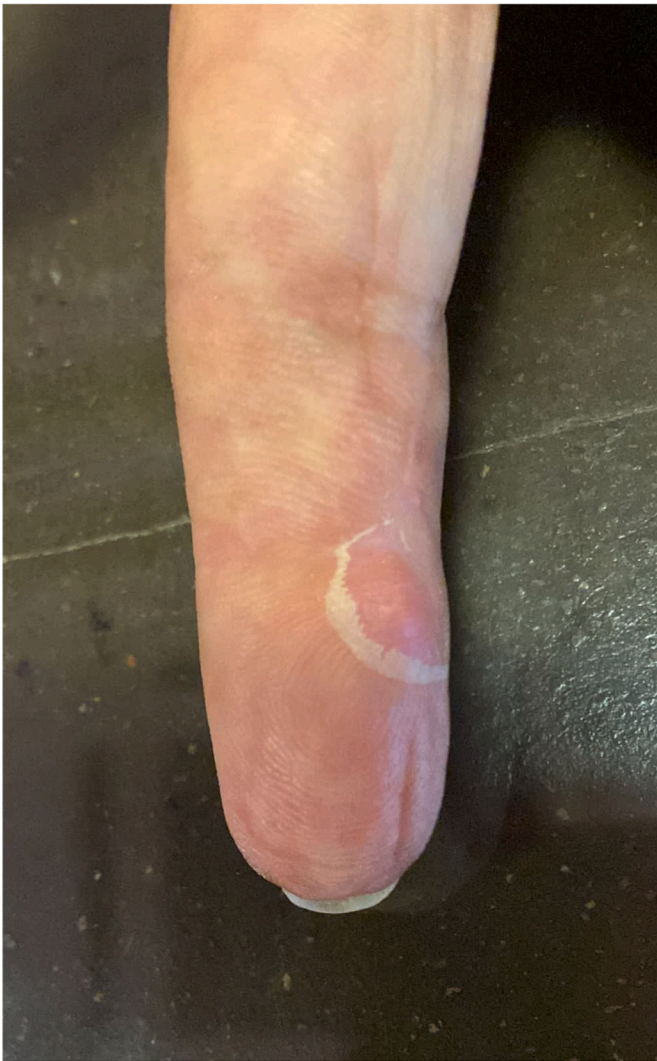

Fig. 1. Second recurrence of the subcutaneous nodule in front of the distal interphalangeal joint of the right index finger.

epithelioid macrophages and plurinucleated giant cells with sheets of neutrophils (Fig. 2), containing numerous fungal elements (conidia and hyphae) on Periodic acid–Schiff (PAS) staining (Fig. 3).

In the bacteriology laboratory, after culture on Lowenstein medium, a melanized fungus and a yeast were isolated. The biopsy sample was

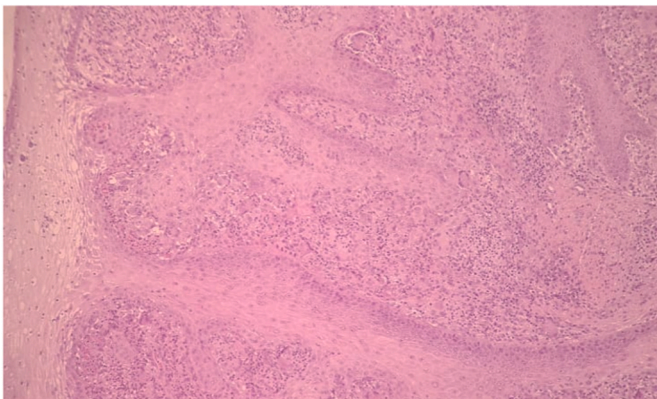


Fig. 2. Histological examination from the finger nodule biopsy in HES stain, 100X. Granuloma rich in macrophage and giant cells.

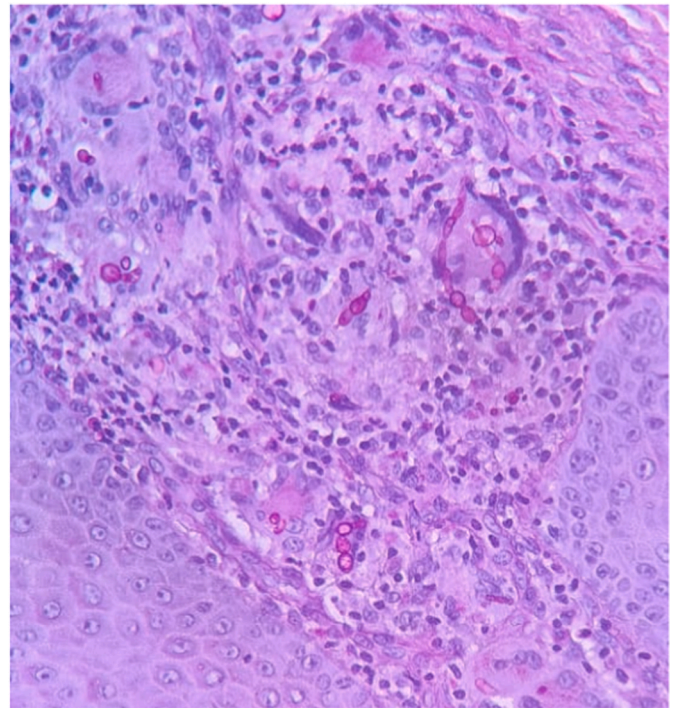


Fig. 3. Histological examination from the finger nodule biopsy in PAS stain, 400X. Numerous filaments and spores within the giant cells.

sent to the mycology laboratory for direct examination, which revealed the presence of numerous septate and branched melanized hyphae with terminal and intercalary chlamydospores (Figs. 4–8).

The yeast culture was then identified as *Candida parapsilosis* by using of Matrix Assisted Laser Desorption/Ionization/Time of Flight Mass Spectrometry (MALDI-TOF-MS, Bruker®). The mold was sent to the French National Reference Center for Mycosis & Antifungals (NRCMA) for polyphasic identification. On malt extract agar (MEA) at 30 °C colonies were olivaceous black, restricted with a woolly texture. Microscopic examination of the slide culture revealed brown septate hyphae with no conidiophores. The flask-shaped phialides with funnel-shaped collarettes and hyaline smooth ellipsoidal conidia were suggestive of the *Phialophora verrucosa* species complex. In parallel, multilocus analysis based on sequencing of the ITS1-5.8S-ITS2 region of the ribosomal



Fig. 4. Olivaceous grey to black colonies of *Phialophora chinensis* on Sabouraud-chloramphenicol-gentamycine medium - 20 days at 30 °C.

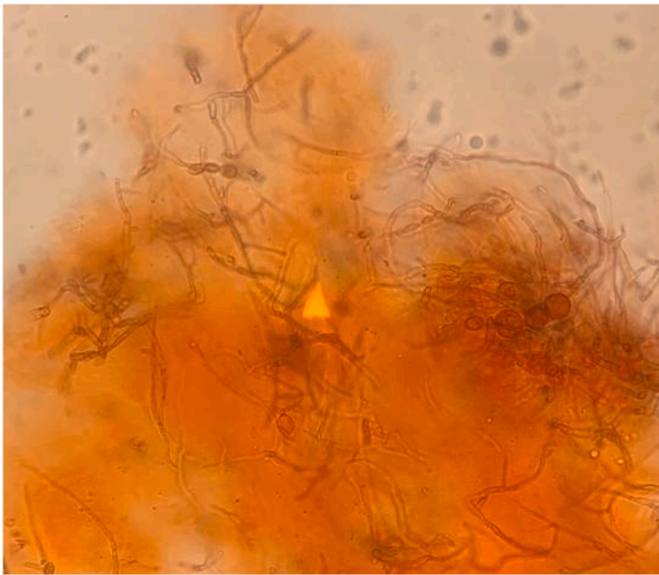


Fig. 5. Direct examination: clearing and staining with congo red (Mycet color®), 40X. Numerous septate and branched mycelia and some terminal and intercalary chlamydo spores.

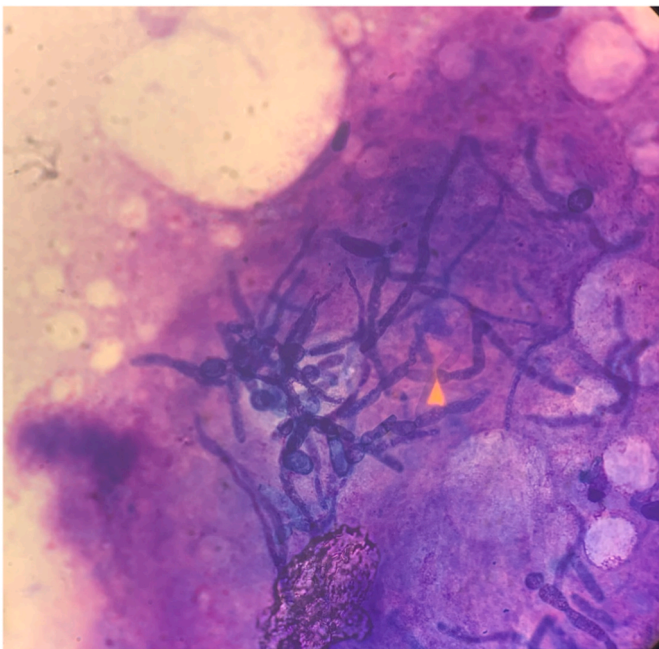


Fig. 6. Direct examination: stained with MGG (May Grunwald Giemsa), 40X. Numerous septate and branched hyphae and some terminal and intercalary chlamydo spores.

DNA, the D1-D2 domain of the large subunit rDNA (28S), and a small region of the β -tubulin (TUB) genes resulted in the identification of *Phialophora chinensis*. Antifungal susceptibility testing was performed using the concentration gradient diffusion assay (Etest, bioMérieux SA, France) and acquired values (mg/L) were as follows: amphotericin B 3, 5-fluorocytosine >32, itraconazole 0.032, posaconazole 0.047, voriconazole 0.094. At the NCRMA, *in vitro* susceptibility testing was also performed according to the European Committee on Antimicrobial Susceptibility Testing [9] with some modifications [10]. Minimum inhibitory concentrations (MICs) were as follows (mg/L): itraconazole 0.25, posaconazole 0.03, voriconazole 0.25, isavuconazole 0.125,

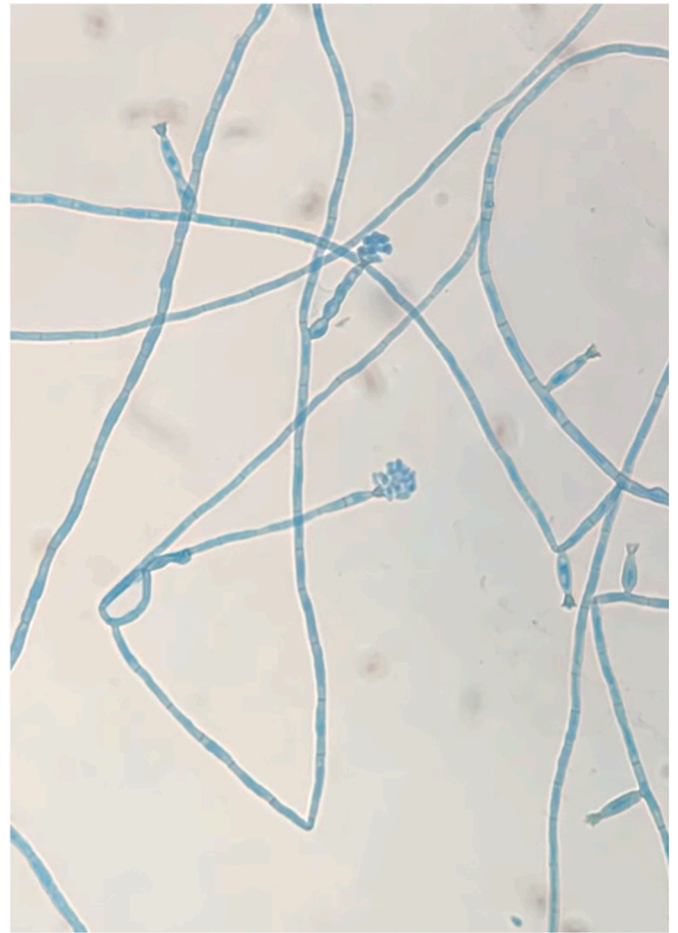


Fig. 7. Microscopic examination of the colony: lactophenol blue, 40X. Septate and branched hyphae, phialides with collarettes, conidia organized in false head.




Fig. 8. Micromorphology of phialides, collerettes and hyaline conidia of *Phialophora chinensis*, 100 X, scale bar 10 μ m.

casposfungin 1 and micafungin 0.125. No MIC value for amphotericin B was obtained due to the absence of growth in the corresponding well on the microplate. As this is a mold that is rarely isolated in human medicine, the E-test technique was performed for evaluation, but the results of the microdilution technique were used as a reference for the choice of

antifungal treatment.

Two months after surgery (day + 60), a recurrence was noted at the same location, confirmed by ultrasound, and a second operation was performed. The content of the cyst was sent to the mycology laboratory, where fungal elements were detected by direct examination and *P. chinensis* was isolated in pure culture after 7 days of incubation at 30 and 37 °C on Sabouraud medium chloramphenicol gentamycin with and without cycloheximide. During the post-operative check-up, one and a half months later (day + 105), a second sub-centimeter recurrence was noted, still in the distal phalanx, and another excision was performed. The mycological examination performed on this new sample confirmed the diagnosis again.

The clinical examination (day + 120) revealed a clean excisional scar without any sign of recurrence and no transit or distant subcutaneous lesions, adenopathy or lymphangitis were found. No extracutaneous symptoms were reported. Biologically, there was normocytic anemia at 10.3 g/dL and known stage IV chronic kidney disease with an estimated glomerular filtration rate of 22 mL/min/1.73m² (using the CKD-EPI equation). There was no inflammatory syndrome (C-Reactive Protein 0.9 mg/L) or hyperleukocytosis. The β-D-1,3-Glucan was positive at 85 pg/mL (norm < 60pg/mL). A thoracic-abdominal-pelvic CT scan did not reveal any bone or organ lesions. Treatment with posaconazole was initiated (day + 127), with a loading dose of 600 mg on day 1, then decreased to 300 mg per day from day 2. Anticoagulant therapy with apixaban was followed by enoxaparin at a curative dose. A drug-drug interaction with tacrolimus led to a clinical and biological overdose, requiring half dose reduction of the calcineurin inhibitor. Tolerance of the antimycotic treatment was moderate with some persistent digestive disorders. The β-D-1,3-Glucan assay was negative after 6 weeks of treatment. Magnetic resonance imaging of the hand was performed at the end of April 2022 and revealed a 6-mm long-axis formation in the distal phalanx of the right index finger in T1 hyposignal and T2 hyper-signal that did not enhance after injection of gadolinium. In order to characterize this bone lesion, a bone scintigraphy was performed, and found no fixation at this level, and the CT examination did not show osteolysis. All these examinations were therefore in favour of a non-infectious degenerative origin.

Treatment with posaconazole was therefore stopped after multidisciplinary discussion between the infectious diseases specialists, dermatologists and nephrologists, after 12 weeks of treatment (day +212) (extended pending further investigations).

3. Discussion

The *Phialophora* genus includes ascomycetous molds, subdivision *Pezizomycotina*, order *Chaetothyriales* and family *Herpotrichiellaceae* [11]. *Phialophora verrucosa* was first described as a pathogen in 1915 and is regularly described in infections such as chromoblastomycosis, phaeoerythromycosis and mycetoma [12]. This cosmopolitan species has been isolated in the environment [13,14]. Phenotypic study is insufficient for correct identification of the species. As morphological characteristics are very similar from one species to another, sequenced-based analysis as well as mass spectrometry (for known species) is indispensable for the identification at the species level. Studies have shown that molecular techniques have a higher accuracy in segregating phenotypically similar species that may differ in pathogenicity [15]. With the use of molecular identification tools for pathogenic fungi, the number of species and genera recognized as causing phaeoerythromycosis has increased substantially [16].

Thanks to the application of molecular methods, *Phialophora chinensis* was identified as the causative agent in this clinical case. Li et al. differentiated seven different species of *Phialophora* based on morphological, phylogenetic and taxonomic data. Their analyses corrected the species identification of several strains of *Phialophora verrucosa* to *Phialophora chinensis*. *Phialophora chinensis* was found mainly in the environment in China (wood, bark, soil, wheat, bamboo) [12].

P. chinensis was first reported as a pathogen in the form of chromoblastomycosis in a 53-year-old immunocompetent farmer in Mexico. The lesion started as a small papule following trauma with a plant during labor. It evolved as a well-limited painless erythematous plaque covered with black dots, localized only on the left arm [17]. In that article, four cases of *Phialophora chinensis* chromoblastomycosis were reported. Three men, aged 39–53 years, presented with exclusive nodular and verrucous skin involvement dating from between 2 and 3 years prior, localized on the arm. Two were treated with itraconazole for 1 year with complete cure. One of them was lost to follow-up at 3 months. The fourth patient was a 74-year-old man with a cystic and tumorous form and the information concerning treatment was not collected.

In our case, the clinical aspect of the lesions and the absence of fumagoid cells on direct examination of the biopsy fragment, totally exclude a chromomycosis.

Phaeoerythromycosis are rare pathologies, and their treatment is poorly defined. It depends on the dermatological lesion and the patient's comorbidities, and may consist in surgical removal, with or without antifungal treatment, or antifungal treatment alone [18]. The European Confederation of Medical Mycology and the European Society of Clinical Microbiology and Infectious Diseases have published guidelines for the treatment of phaeoerythromycosis suggesting itraconazole, voriconazole and posaconazole as first line drugs [19].

4. Conclusion

To the best of our knowledge, this is the first case of dermal phaeoerythromycosis due to *Phialophora chinensis* by probable inoculation after microtrauma by a plant thorn, in a kidney transplant patient. The outcome was favorable after treatment associating surgery with prolonged antifungal treatment with posaconazole.

Conflict of interest

There are none.

Acknowledgements

The authors thank Dr Turmel, Dr Emal and Dr Jouanelle-Sulpicy for their help in diagnostic and therapeutic management.

The authors thank Mr Heriniaina Daddy, for help in taking the histology photographs.

References

- [1] J.T. Arcobello, S.G. Revankar, Phaeoerythromycosis. *Semin Respir Crit Care Med.* févr 41 (1) (2020) 131–140.
- [2] V. Litchevski, A. Goldschmidt, D. Nass, G. Rahav, Z.R. Cohen, Cerebral phaeoerythromycosis in an immunocompetent patient: a case report and literature summary, *Clin Neurol Neurosurg.* sept 124 (2014) 179–181.
- [3] S.R. Jinkala, D. Basu, S. Neeliah, N. Stephen, S. Bheemanati Hanuman, R. Singh, Subcutaneous phaeoerythromycosis: a clinical mimic of skin and soft tissue neoplasms-A descriptive study from India, *World J. Surg. déc 42 (12) (2018) 3861–3866.*
- [4] B. Behera, E. Thomas, R. Kumari, D.M. Thappa, S. Jinkala, Polymorphous presentation of subcutaneous phaeoerythromycosis: a rare occurrence, *Int. J. Dermatol.* févr 57 (2) (2018) e1-3.
- [5] K.E. Ginting, M. Caparelli, N. Kundu, Necrotizing soft tissue infection after intravenous drug injection: a multidisciplinary approach to surgical management at a community hospital, *sept, Am. Surg.* 86 (9) (2020) 1215–1217.
- [6] E. Amazan, N. Desbois, G. Fidelin, E. Baubion, C. Derancourt, S. Thimon, et al., [First case of phaeoerythromycosis due to *Pleurostoma otheica* in a kidney transplant recipient in Martinique (French West Indies)], *Med. Sante Trop.* sept. 24 (3) (2014) 323–325.
- [7] C. Dutriaux, I. Saint-Cyr, N. Desbois, D. Calès-Quist, A. Diedhou, A.M. Boisseau-Garsaud, [Subcutaneous phaeoerythromycosis due to *Exophiala spinifera* in a renal transplant recipient], *Ann. Dermatol. Venereol.* mars 132 (3) (2005) 259–262.
- [8] S. Guégan, D. Garcia-Hermoso, K. Sitbon, S. Ahmed, P. Moguelet, F. Dromer, et al., Ten-year experience of cutaneous and/or subcutaneous infections due to coelomycetes in France, *avr, Open Forum Infect Dis* 3 (2) (2016) ofw106.
- [9] Subcommittee on Antifungal Susceptibility Testing of the Escmid European Committee for Antimicrobial Susceptibility Testing, EUCAST Technical Note on the

- method for the determination of broth dilution minimum inhibitory concentrations of antifungal agents for conidia-forming moulds, *Clin. Microbiol. Infect.* oct 14 (10) (2008) 982–984.
- [10] D. Garcia-Hermoso, D. Hoinard, J.C. Gantier, F. Grenouillet, F. Dromer, E. Dannaoui, Molecular and phenotypic evaluation of *Lichtheimia corymbifera* (formerly *Absidia corymbifera*) complex isolates associated with human mucormycosis: rehabilitation of *L. ramosa*, *déc.*, *J. Clin. Microbiol.* 47 (12) (2009) 3862–3870.
- [11] de Hoog GS, Guarro J, Gené J, Ahmed SA, Al-Hatmy AMS, Figueras MJ, et al. *Atlas of Clinical Fungi* fourth ed..
- [12] Y. Li, J. Xiao, G.S. de Hoog, X. Wang, Z. Wan, J. Yu, et al., Biodiversity and human-pathogenicity of *Phialophora verrucosa* and relatives in Chaetothyriales, *Persoonia.* juin 38 (2017) 1–19.
- [13] E. Gezuele, J.E. Mackinnon, I.A. Conti-Díaz, The frequent isolation of *Phialophora verrucosa* and *Phialophora pedrosoi* from natural sources, *Sabouraudia.* nov 10 (3) (1972) 266–273.
- [14] K. Takizawa, T. Hashizume, K. Kamei, Occurrence and characteristics of group 1 introns found at three different positions within the 28S ribosomal RNA gene of the dematiaceous *Phialophora verrucosa*: phylogenetic and secondary structural implications, *BMC Microbiol.* 8 mai 11 (2011) 94.
- [15] R. Marimon, J. Gené, J. Cano, L. Trilles, M. Dos Santos Lazéra, J. Guarro, Molecular phylogeny of *Sporothrix schenckii*, *J. Clin. Microbiol.* 44 (9) (2006) 3251–3256.
- [16] S.A. Ahmed, N. Desbois, D. Quist, C. Miossec, C. Atoche, A. Bonifaz, et al., Phaeohiphomycosis caused by a novel species, *pseudochaetosphaeronema martinelli*, *J. Clin. Microbiol.* 53 (9) (2015) 2927–2934.
- [17] S.A. Ahmed, A. Bonifaz, G.M. González, L.F. Moreno, N. Menezes da Silva, V. A. Vicente, et al., Chromoblastomycosis caused by *phialophora*—proven cases from Mexico, *J. Fungi.* févr 7 (2) (2021) 95.
- [18] AC. de C. Lima, DW. de CL. Santos, S.H. Hirata, A.S. Nishikaku, M.M.S.E. S. Enokihara, M.M. Ogawa, Therapeutic management of subcutaneous phaeohiphomycosis and chromoblastomycosis in kidney transplant recipients: a retrospective study of 82 cases in a single center, *Int. J. Dermatol.* mars 61 (3) (2022) 346–351.
- [19] A. Chowdhary, J.F. Meis, J. Guarro, G.S. de Hoog, S. Kathuria, M.C. Arendrup, et al., ESCMID and ECMM joint clinical guidelines for the diagnosis and management of systemic phaeohiphomycosis: diseases caused by black fungi, *Clin. Microbiol. Infect.* avr 20 (Suppl 3) (2014) 47–75.