



HAL
open science

Combined High-Dose Caspofungin and Liposomal Amphotericin B for Treatment of Azole-Resistant Cerebral Aspergillosis

A. Pouvaret, A. Duréault, D. Garcia-Hermoso, A. Serris, J. Cohen, R. Guery, F. Lanternier, O. Lortholary

► **To cite this version:**

A. Pouvaret, A. Duréault, D. Garcia-Hermoso, A. Serris, J. Cohen, et al.. Combined High-Dose Caspofungin and Liposomal Amphotericin B for Treatment of Azole-Resistant Cerebral Aspergillosis. *Antimicrobial Agents and Chemotherapy*, 2021, 65 (10), pp.e00474-21. 10.1128/AAC.00474-21 . pasteur-04173103

HAL Id: pasteur-04173103

<https://pasteur.hal.science/pasteur-04173103>

Submitted on 28 Jul 2023

HAL is a multi-disciplinary open access archive for the deposit and dissemination of scientific research documents, whether they are published or not. The documents may come from teaching and research institutions in France or abroad, or from public or private research centers.

L'archive ouverte pluridisciplinaire **HAL**, est destinée au dépôt et à la diffusion de documents scientifiques de niveau recherche, publiés ou non, émanant des établissements d'enseignement et de recherche français ou étrangers, des laboratoires publics ou privés.

Copyright



Combined High-Dose Caspofungin and Liposomal Amphotericin B for Treatment of Azole-Resistant Cerebral Aspergillosis

A. Pouvaret,^a A. Duréault,^a D. Garcia-Hermoso,^b A. Serris,^a J. F. Cohen,^a R. Guery,^a F. Lanternier,^{a,b} O. Lortholary^{a,b}

^aParis University, Necker-Pasteur Center for Infectious Diseases and Tropical Medicine, Necker-Enfants Malades Hospital, AP-HP, IHU Imagine, Paris, France

^bInstitut Pasteur, CNRS, National Reference Center for Invasive Mycoses and Antifungals (NRCMA), Molecular Mycology Unit, UMR2000, Paris, France

KEYWORDS azole resistance, central nervous system, invasive aspergillosis

The prevalence of azole-resistant aspergillosis is increasing and represents a public health issue in some countries, with an excess mortality of 25% (1). The advent of voriconazole improved the management of central nervous system (CNS) aspergillosis (2), but there is no consensual alternative in the case of azole resistance. We report the first case of successful treatment of CNS pan-azole-resistant aspergillosis.

A 79-year-old woman presented with right central facial palsy, hemiparesis, and aphasia. Her medical history included high blood pressure and ovarian adenocarcinoma treated by radical surgery followed by chemotherapy, and she achieved a complete response 2 months earlier.

Cerebral computed tomography revealed left cerebral infarctions with complete occlusion of the internal carotid artery by a mass with erosion of the carotid canal and the sphenoid bone wall. Subsequently, her neurological condition deteriorated with cranial nerve dysfunctions. In the absence of improvement, a transsphenoidal biopsy specimen of a lesion of the cavernous sinus revealed the presence of acute septate hyphae, and culture grew *Aspergillus fumigatus sensu stricto*. The fungal strain was identified using a polyphasic approach, including nucleotide sequencing and phenotypic characteristics. There was no extracerebral involvement.

Intravenous voriconazole (4 mg/kg every 12 h) combined with liposomal amphotericin B (L-amB) 5 mg/kg/day were administered. L-amB was then reduced to 3 mg/kg/d after 1 month due to mild kidney failure.

Despite antifungal treatment with close drug monitoring, the patient experienced seizure. Cerebral magnetic resonance imaging (MRI) revealed extension of the fungal lesion to the left prepontine cistern, causing mass effect on vascular structures (Fig. 1A and C).

Antifungal susceptibility testing using EUCAST methodology expressed as MICs revealed voriconazole, 2 mg/liter; isavuconazole, 4 mg/liter; itraconazole, 16 mg/liter; posaconazole, 0.5 mg/liter; amphotericin B, 0.125 mg/liter; caspofungin, 0.5 mg/liter; and micafungin, 0.007 mg/liter. Sequence analysis of the *cyp51A* gene revealed three amino acid substitutions, F46Y, M172V, and E427K. Voriconazole was then switched to caspofungin 100 mg/day in combination with L-amB. Caspofungin was increased to 150 mg/day as soon as L-amB dosage was reduced. After adaptation of antifungal therapy, the patient showed slow improvement in her condition. She remained in the hospital for 6 months. She was then discharged to the West Indies, her birthplace. We dispose of an imaging control performed 3 years later that confirms the successful outcome (Fig. 1B and D). She is currently alive 34 months after the diagnosis of aspergillosis, facing ovarian cancer relapse. She is able to walk; she did not experience any seizure.

We report the first isolation of a pan-azole-resistant *A. fumigatus* isolate harboring the mutation F46Y/M172V/E427K in the *cyp51A* gene, recovered from an azole-naïve patient with CNS aspergillosis, with favorable outcome after 34 months of L-amB and high-dose caspofungin.

Citation Pouvaret A, Duréault A, Garcia-Hermoso D, Serris A, Cohen JF, Guery R, Lanternier F, Lortholary O. 2021. Combined high-dose caspofungin and liposomal amphotericin B for treatment of azole-resistant cerebral aspergillosis. *Antimicrob Agents Chemother* 65:e00474-21. <https://doi.org/10.1128/AAC.00474-21>.

Copyright © 2021 American Society for Microbiology. All Rights Reserved.

Address correspondence to A. Pouvaret, anne.pouvaret@aphp.fr.

Accepted manuscript posted online 12 July 2021

Published 17 September 2021

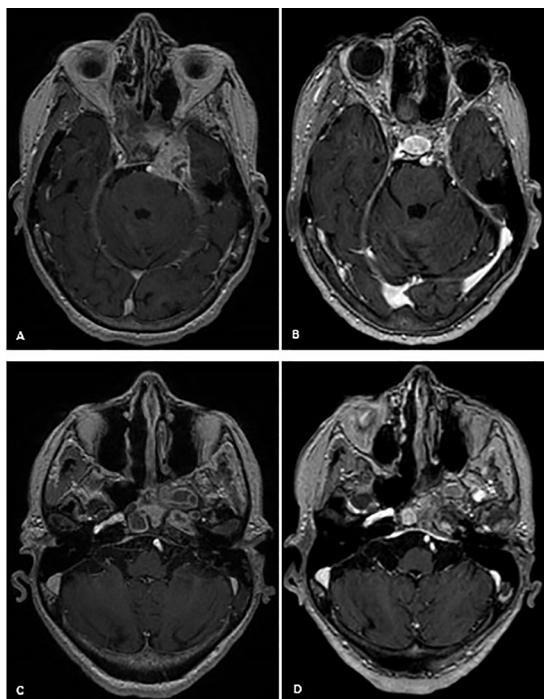


FIG 1 (A and C) Cerebral MRI axial T1-weighted imaging with gadolinium demonstrates complete occlusion of the left carotid artery, erosion of carotid canal and sphenoid bone wall by a tissular mass, and the extension to the left prepontine cistern with mass effect. (B and D) Cerebral MRI evaluation performed 3 years later displayed significant improvement, with complete regression of cerebral involvement.

Since the 2000s, reports of azole resistance in *A. fumigatus*, resulting in therapeutic failure, have increased. Most resistance mutations are due to alterations on the *cyp51A* gene encoding sterol 14 α -demethylase, an enzyme involved in cell membrane synthesis. Typical mutations are those combining a tandem repeat (TR) in the gene promoter and amino acid substitutions such as TR34/L98H or TR46/Y121F/T289A (3). Antifungal susceptibility testing of *Aspergillus* isolates is recommended in individuals with invasive aspergillosis except in triazole-naïve patients in regions without resistance described in an epidemiologic surveillance program (4, 5). Our patient had no azole preexposure. She only reported travel in the Netherlands 4 years earlier.

Voriconazole is the recommended first-line therapy in CNS aspergillosis due to azole-susceptible isolates (2, 4). In the case of azole resistance, international experts may prefer L-amB at high doses, although its limited efficacy as single therapy has been emphasized (6). Combination therapy may be justified in this situation (5). Combined L-amB and high-dose caspofungin have proven effectiveness in murine models of CNS aspergillosis (7) and should be considered for pan-azole-resistant CNS aspergillosis (8).

ACKNOWLEDGMENTS

This research received no specific grant from any funding agency in the public, commercial, or not-to-profit sectors.

A.P., A.D., D.G.-H., J.F.C., A.S., and R.G. have no conflict of interest to declare. O.L. has disclosed the following relevant financial relationships: served as an advisor or consultant for Gilead Sciences Inc., Neteos, and F2G and served as speaker or member of a speakers bureau for Gilead Sciences Inc., Pfizer Inc., MSD, and Astellas Pharma Inc. F.L. served as member of speakers bureaus for Gilead Sciences Inc. and Basilea.

REFERENCES

- Resendiz-Sharp A, Mercier T, Lestrade PPA, van der Beek MT, von Dem Borne PA, Cornelissen JJ, De Kort E, Rijnders BJA, Schouwvlieghe A, Verweij PE, Maertens J, Lagrou K. 2019. Prevalence of voriconazole-resistant invasive aspergillosis and its impact on mortality in haematology patients. *J Antimicrob Chemother* 74:2759–2766. <https://doi.org/10.1093/jac/dkz258>.

2. Schwartz S, Ruhnke M, Ribaud P, Corey L, Driscoll T, Cornely OA, Schuler U, Lutsar I, Troke P, Thiel E. 2005. Improved outcome in central nervous system aspergillosis, using voriconazole treatment. *Blood* 106:2641–2645. <https://doi.org/10.1182/blood-2005-02-0733>.
3. Wiederhold NP, Gil VG, Gutierrez F, Lindner JR, Albataineh MT, McCarthy DI, Sanders C, Fan H, Fothergill A, Sutton DA. 2016. First Detection of TR34 L98H and TR46 Y121F T289A Cyp51 mutations in *Aspergillus fumigatus* isolates in the United States. *J Clin Microbiol* 54:168–171. <https://doi.org/10.1128/JCM.02478-15>.
4. Ullmann AJ, Aguado JM, Arkan-Akdagli S, Denning DW, Groll AH, Lagrou K, Lass-Flörl C, Lewis RE, Munoz P, Verweij PE, Warris A, Ader F, Akova M, Arendrup MC, Barnes RA, Beigelman-Aubry C, Blot S, Bouza E, Brüggemann RJM, Buchheidt D, Cadranet J, Castagnola E, Chakrabarti A, Cuenca-Estrella M, Dimopoulos G, Fortun J, Gangneux JP, Garbino J, Heinz WJ, Herbrecht R, Heussel CP, Kibbler CC, Klimko N, Kullberg BJ, Lange C, Lehrnbecher T, Löffler J, Lortholary O, Maertens J, Marchetti O, Meis JF, Pagano L, Ribaud P, Richardson M, Roilides E, Ruhnke M, Sanguinetti M, Sheppard DC, Sinko J, Skiada A, Vehreschild MJGT, Viscoli C, Cornely OA. 2018. Diagnosis and management of *Aspergillus* diseases: executive summary of the 2017 ESCMID-ECMM-ERS guideline. *Clin Microbiol Infect* 24(Suppl 1):e1–e38. <https://doi.org/10.1016/j.cmi.2018.01.002>.
5. Verweij PE, Ananda-Rajah M, Andes D, Arendrup MC, Brüggemann RJ, Chowdhary A, Cornely OA, Denning DW, Groll AH, Izumikawa K, Kullberg BJ, Lagrou K, Maertens J, Meis JF, Newton P, Page I, Seyedmousavi S, Sheppard DC, Viscoli C, Warris A, Donnelly JP. 2015. International expert opinion on the management of infection caused by azole-resistant *Aspergillus fumigatus*. *Drug Resist Updat* 21–22:30–40. <https://doi.org/10.1016/j.drup.2015.08.001>.
6. Schwartz S, Ruhnke M, Ribaud P, Reed E, Troke P, Thiel E. 2007. Poor efficacy of amphotericin B-based therapy in CNS aspergillosis. *Mycoses* 50:196–200. <https://doi.org/10.1111/j.1439-0507.2007.01345.x>.
7. Clemons KV, Espiritu M, Parmar R, Stevens DA. 2005. Comparative efficacies of conventional amphotericin B, liposomal amphotericin B (AmBisome), caspofungin, micafungin, and voriconazole alone and in combination against experimental murine central nervous system aspergillosis. *Antimicrob Agents Chemother* 49:4867–4875. <https://doi.org/10.1128/AAC.49.12.4867-4875.2005>.
8. van der Linden JWM, Jansen RR, Bresters D, Visser CE, Geerlings SE, Kuijper EJ, Melchers WJG, Verweij PE. 2009. Azole-resistant central nervous system aspergillosis. *Clin Infect Dis* 48:1111–1113. <https://doi.org/10.1086/597465>.

