



HAL
open science

Monkeypox

Antoine Gessain, Emmanuel Nakoune, Yazdan Yazdanpanah

► **To cite this version:**

Antoine Gessain, Emmanuel Nakoune, Yazdan Yazdanpanah. Monkeypox. *New England Journal of Medicine*, 2022, 387 (19), pp.1783-1793. 10.1056/NEJMra2208860 . pasteur-04079351

HAL Id: pasteur-04079351

<https://pasteur.hal.science/pasteur-04079351v1>

Submitted on 24 Apr 2023

HAL is a multi-disciplinary open access archive for the deposit and dissemination of scientific research documents, whether they are published or not. The documents may come from teaching and research institutions in France or abroad, or from public or private research centers.

L'archive ouverte pluridisciplinaire **HAL**, est destinée au dépôt et à la diffusion de documents scientifiques de niveau recherche, publiés ou non, émanant des établissements d'enseignement et de recherche français ou étrangers, des laboratoires publics ou privés.

Copyright

REVIEW ARTICLE

C. Corey Hardin, M.D., Ph.D., *Editor*

Monkeypox

Antoine Gessain, M.D., Emmanuel Nakoune, Ph.D.,
and Yazdan Yazdanpanah, M.D.

MONKEYPOX VIRUS WAS FIRST ISOLATED IN LATE 1958 IN COPENHAGEN during two outbreaks of a smallpox-like disease in a colony of cynomolgus monkeys.¹ No clinical signs were noted before the eruptive phase of the disease, which was characterized by a maculopapular rash. The virus was named monkeypox virus because of its close similarity to other known poxviruses.¹

Between 1960 and 1968, several other outbreaks of monkeypox were reported in colonies of captive monkeys in the United States and the Netherlands.² No cases were detected in humans during these outbreaks, despite the deaths of many affected animals, which suggested that humans were not susceptible to monkeypox.²

The first case of monkeypox in a human was reported in 1970,³ as part of the national smallpox surveillance and eradication program then under way in Africa. This case occurred in a 9-month-old boy, in whom fever developed, followed 2 days later by a centrifugal rash (i.e., a rash with the majority of lesions on the arms and legs). On September 1, 1970, he was admitted to a hospital in Basankusu, in the Democratic Republic of Congo (DRC). The patient presented with otitis, mastoiditis, and painful cervical lymph nodes, and monkeypox virus was isolated from his skin lesions. He recovered from monkeypox, but before discharge, measles developed, which led to his death.³ Between September 1970 and March 1971, six additional cases of monkeypox were identified in humans in West African countries. Most of these patients were young children, and none had been vaccinated against smallpox.⁴

Monkeypox in humans remained an exclusively African disease, with sporadic cases diagnosed in forested areas of Central or West Africa and small outbreaks mainly in the DRC,^{5,6} until 2003, when the first cases outside Africa were reported. These cases occurred in the United States and were linked to the importation of Gambian pouched rats from Ghana to Texas. The rodents transmitted the virus to prairie dogs housed in the same exotic-animal facility, and the prairie dogs then infected humans, mostly young adults and children.⁷ In 2018, five infected patients were identified: three in the United Kingdom, one in Israel, and one in Singapore.^{6,8} These imported cases were linked to persons from Nigeria, where a large outbreak occurred in 2017–2018.^{9–11} The disease has continued to be common in Africa, with very rare sporadic cases in the United Kingdom and the United States.^{12,13}

In May 2022, a series of monkeypox cases was identified in the United Kingdom, Portugal, and Italy, mostly involving men who have sex with men (MSM).^{14–16} Health authorities rapidly established that this series was the start of a new outbreak.¹⁷

From Institut Pasteur, Université de Paris Cité, Centre National de la Recherche Scientifique, UMR3569, Unité d'Épidémiologie et Physiopathologie des Virus Oncogènes, Département de Virologie (A.G.), and Assistance Publique–Hôpitaux de Paris, Department of Infectious and Tropical Diseases, Bichat-Claude Bernard University Hospital, INSERM, ANRS Maladies Infectieuses Émergentes (Y.Y.) — both in Paris; and Institut Pasteur de Bangui, Bangui, Central African Republic (E.N.). Dr. Gessain can be contacted at agessain@pasteur.fr or at Unité d'Épidémiologie et Physiopathologie des Virus Oncogènes, CNRS UMR3569, Département de Virologie, Institut Pasteur, F-75015 Paris, France.

This article was published on October 26, 2022, at [NEJM.org](https://www.nejm.org).

N Engl J Med 2022;387:1783–93.

DOI: 10.1056/NEJMra2208860

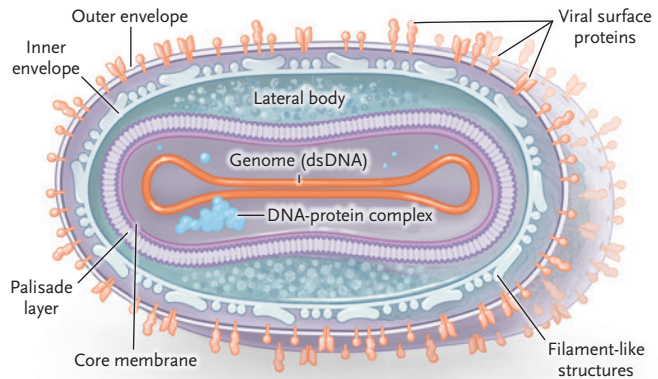
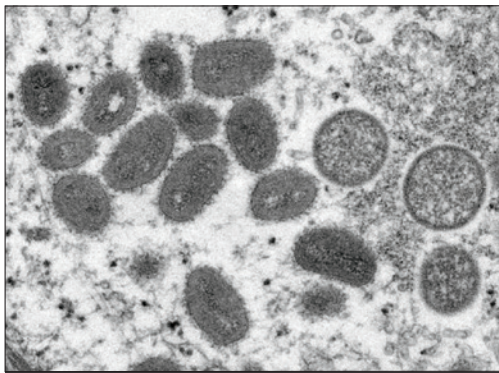
Copyright © 2022 Massachusetts Medical Society.

CME
at [NEJM.org](https://www.nejm.org)

VIROLOGY

Monkeypox virus belongs to the family Poxviridae, subfamily Chordopoxvirinae, and genus orthopoxvirus^{18,19} (Fig. 1). The genus encompasses many other poxviruses, including the smallpox, vaccinia, cowpox, and camelpox viruses, as well as

A Virus Structure



B Geographic Distribution and Nomenclature

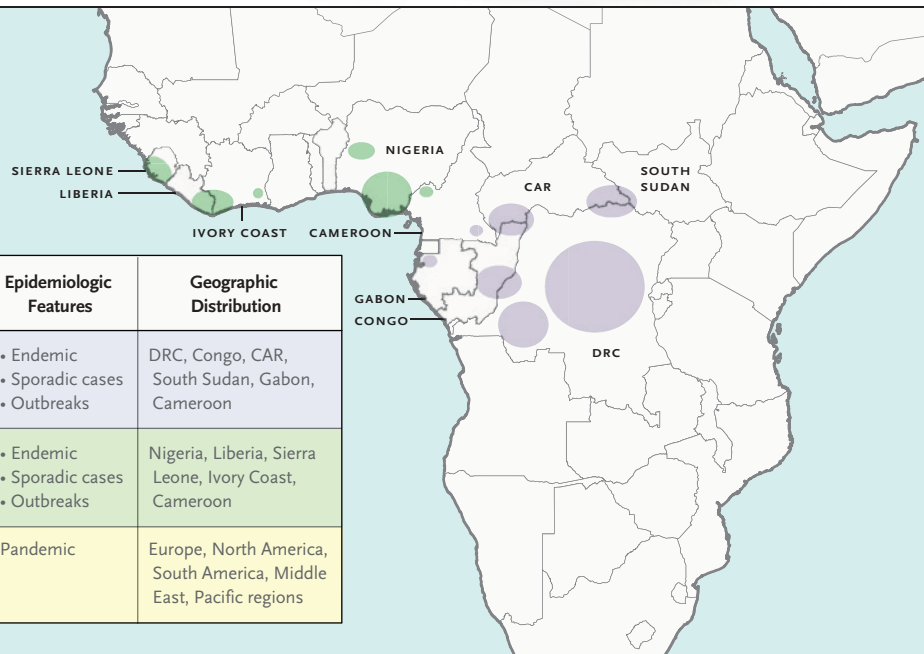


Figure 1. Viral Structure, Geographic Distribution in Africa, and Nomenclature of Monkeypox Viral Lineages.

An electron micrograph of several monkeypox viruses (Panel A, left) shows their characteristic rectangular or ovoid, bricklike shape. The monkeypox virus is a large, enveloped virus (Panel A, right). Each virion encapsulates a core that contains a linear, double-stranded DNA (dsDNA) genome of 200 kilobase pairs encoding about 200 proteins, including the various enzymes required for replication, viral assembly, control over host range, and pathogenesis. The viral cycle takes place exclusively in the cytoplasm of infected cells. The virion contains two lipoprotein envelopes: an internal envelope surrounding the capsid and an external envelope covered with viral surface proteins for attachment to the cell surface. The map (Panel B) shows regions of Africa with reported sporadic cases and outbreaks of monkeypox. The lavender spots denote Central African (clade 1) viral strains and the green spots West African (clade 2) viral strains. The spots range in size from smaller to larger, with larger spots indicating more cases of monkeypox. The table next to the map shows the original and newly proposed taxonomies and epidemiologic features of the three clades of monkeypox virus. CAR denotes Central African Republic, and DRC Democratic Republic of Congo. The electron micrograph is courtesy of the Centers for Disease Control and Prevention.

more recently isolated poxviruses.^{18,20} These double-stranded DNA viruses are very similar genetically and antigenically, which accounts for cross-immunity. Vaccination against smallpox generally

provides some protection against monkeypox.^{21,22} Since the cessation of smallpox vaccination in 1980, herd immunity has steadily declined. This phenomenon is one of the factors favoring the

emergence of monkeypox.²² There are two genetic clades, with genomes differing by less than 1%. The first clade is endemic in Central Africa, and the second in West Africa.^{23,24} With the emergence of monkeypox viruses outside Africa and the need to destigmatize the disease and prevent discrimination, discussions about a possible name change and the definition of three clades are under way (Fig. 1).²⁵ We use this revised nomenclature here. The monkeypox genome sequences of the 2022 cases (which we refer to as clade 3) originated from the West African clade (lineage B.1).

RESERVOIR FOR MONKEYPOX TRANSMISSION TO HUMANS

Monkeypox is a zoonotic disease, but its animal reservoir remains unknown. Various rodent species from Central and West African tropical rainforests, including tree squirrels and Gambian pouched rats, are currently considered to be strong candidates²⁶⁻²⁹ (Fig. 2). African apes and monkeys can be infected and are thought to be intermediate hosts.²⁸ Many animals, such as rabbits, prairie dogs, other rodents, and monkeys, are susceptible to infection in captivity, including laboratory animals.^{30,31}

OUTBREAKS IN AFRICAN COUNTRIES

CLINICAL FEATURES

These data are based primarily on the description of cases from the 1980 epidemic in the DRC,^{32,33} the 2017–2018 epidemic in Nigeria,^{10,11} and epidemics in the Republic of Congo^{34,35} and Central African Republic since 2000.³⁶⁻³⁸ Monkeypox epidemics frequently occur in small, remote villages in forested rural areas that are difficult to reach. Several epidemics have occurred in the context of armed conflict or population movements. These conditions are often associated with an inadequate medical infrastructure and limited public health and health care staff, which lead to poor patient care and follow-up. The available clinical and epidemiologic data are therefore often obtained retrospectively and may be incomplete.

Monkeypox affects both children and adults and typically has three phases: incubation, prodrome, and the eruptive stage.^{32,33,39-41} After primary infection, which may be difficult to date

precisely, especially in the context of a zoonotic origin, the mean incubation period is 13 days (range, 3 to 34). The prodromal phase lasts for 1 to 4 days and is characterized by a high temperature, headache, fatigue, and often, lymphadenopathy, especially in the cervical and maxillary regions (Table 1). The lymphadenopathy distinguishes monkeypox from chickenpox. During the eruptive phase, which lasts for 14 to 28 days, skin lesions appear in a centrifugal distribution and progress through several stages: macules, papules, vesicles, and finally, pustules. The lesions are firm and well delimited and display umbilication (Fig. 3).

The lesions develop crusts that desquamate, leaving areas of hypopigmentation, followed by hyperpigmentation. A patient may have from a few to several thousand lesions, located principally on the face, trunk, arms, and legs (Fig. 3). Lesions frequently occur on the palms and soles, a feature that distinguishes monkeypox from chickenpox. More rarely, skin lesions affect other areas, such as the genitals, or are associated with oral ulcers and conjunctival damage. Usually, all lesions are at the same stage of development, another feature that differentiates monkeypox from other illnesses with skin manifestations, such as chickenpox. Patients often have pruritus and myalgia.

Symptom severity and disease duration are proportional to the density of skin lesions. The disease is most severe in children and pregnant women. Monkeypox usually follows a self-limiting course, but clinical sequelae, including pitted facial scars, are common. Corneal ulceration may occur, followed by scarring and opacities, which lead to vision loss. The most frequent complications are cutaneous bacterial infections. Bronchopneumonia and respiratory distress may occur, particularly late in the course of the disease. In case series from the 1980s in the DRC, complications were less common in patients who had been vaccinated against smallpox than in unvaccinated patients.^{32,33} Monkeypox appears to be more severe in immunocompromised patients infected with human immunodeficiency virus (HIV) than in patients without HIV infection. Four of the seven people who died in the 2017–2018 epidemic in Nigeria had HIV coinfection and were not receiving antiretroviral therapy.¹¹ The overall case fatality rate appears to be lower among patients infected with West African

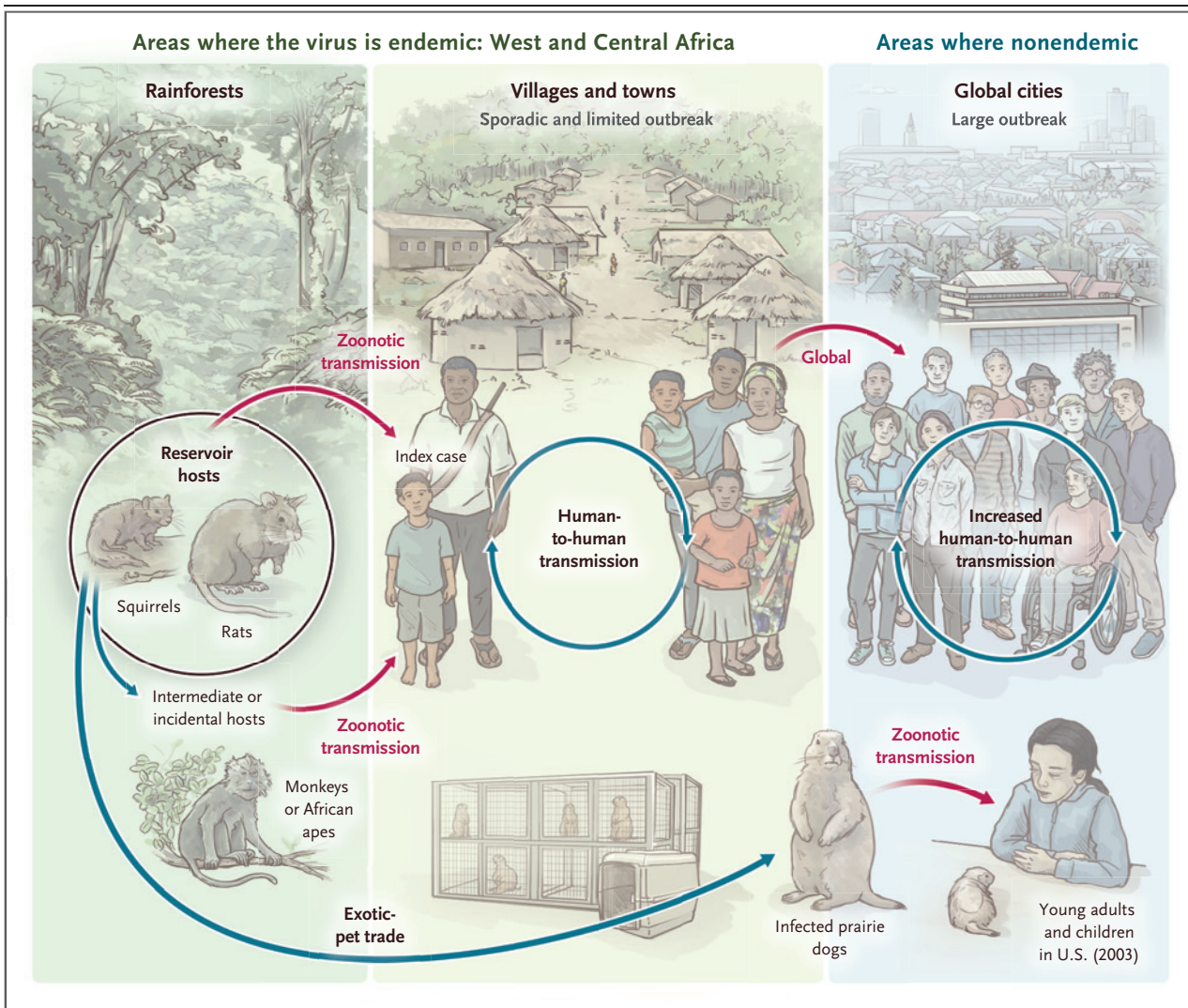


Figure 2. Natural History of Monkeypox.

The reservoir of the monkeypox virus has yet to be clearly identified. Rodents, including various species of squirrels and rats living in the rainforests of Central and West Africa, are among the most likely candidates. Monkeypox virus is transmitted through contact between the biologic fluids, lesions, or both of a reservoir animal or an incidentally infected host, such as a monkey, and a human being, the index patient. The precise conditions of this viral spillover remain unclear, but contamination is thought to be most likely during hunting, as a result of bites from an infected animal, and during the transport, butchering, or consumption of infected animals. Human-to-human transmission subsequently occurs, primarily among family members, but it may also occur in a nosocomial setting, at a clinic or hospital. This human-to-human transmission can lead to sporadic cases of infection or epidemics, generally of moderate magnitude, which die out naturally within a few weeks or months, given the relatively low transmissibility of the virus in regions where it is endemic. On rare occasions, the monkeypox virus has emerged outside Africa. The first time this is known to have occurred was in 2003, as a result of the importation into the United States of various rodents, including Gambian rats, from Ghana. The rodents infected prairie dogs, which then infected young persons (young adults and children) in the United States. Since 2017, the virus has again been escaping from Africa, this time in infected people, which resulted in the introduction of the virus into the gay, bisexual, and MSM community in 2022. The rapid and extensive spread of monkeypox in this community, due to multiple contacts in the context of connected sexual networks, has contributed to the occurrence of the largest monkeypox epidemic ever observed.

strains (clade 2) than among those infected with Central African strains (clade 1). The case fatality rate was 6% in Nigeria but ranges from 10 to 15% in the DRC and the Central African Republic, depending on the study considered.^{11,32,38,39} The main infection in the differential diagno-

Table 1. Features of the Classic Form of Monkeypox and the New Clinical–Epidemiologic Form.

Variable	Classic Form, 1970s to the Present	New Clinical–Epidemiologic Form, 2022
Location	Central and West Africa	Countries where monkeypox is not endemic (Europe, North and South America, Middle East, Australia)
Affected population	Children and young adults (age at diagnosis increasing since 1980)	Young men who have sex with men (age, 31–40 yr)
Epidemiologic features	Sporadic cases and epidemics	Pandemic under way since May 2022
Transmission	Contact with infected animal reservoir (probably rodents), followed by human-to-human transmission	Exclusively human-to-human transmission
Dissemination	Mostly intrafamilial and limited nosocomial dissemination	Mostly sexual networking, condomless sex with multiple male partners
Clinical phase	Incubation, prodromal stage, eruption phase with skin lesions	Incubation, prodromal stage (not always present), eruption phase with lesions in an unusual distribution, especially on the genitals
Symptoms	Lesions on the face and extremities, with centrifugal distribution, often associated with cervical or axillary lymphadenopathy	Penile rash, perianal lesions, ulcerative lesions and vesicular rash, painful inguinal lymphadenopathy, pharyngitis, proctitis
Viruses	Central African and West African clades (clades 1 and 2, respectively)	West African variant (clade 3)
Case fatality rate (%)	1–15	0.025

sis is chickenpox.⁴² Chickenpox and monkeypox epidemics can occur simultaneously, and coinfections are frequent.^{43,44} In a study in the DRC from 2009 to 2014, of 1107 suspected monkeypox cases, 134 were found to be monkeypox and chickenpox coinfections.⁴⁵

EPIDEMIOLOGIC FEATURES

Human monkeypox infection has been reported in 10 African countries, with a very large increase in case numbers over the past three decades.^{5,6,22} The DRC is, by far, the most affected country, with national surveillance data showing a steady increase in suspected cases from fewer than 500 cases in 2001 to more than 2500 in 2018.^{6,46} Nigeria, Republic of Congo, and the Central African Republic are the other countries most affected, each with a few hundred cases reported.

The median age at diagnosis has increased significantly over time.⁶ In the 1970s and 1980s, most cases occurred in young children, whereas the median age at diagnosis was 29 years in the 2017–2018 epidemic in Nigeria.¹¹

In Africa, both animal-to-person and person-to-person transmissions have been documented (Fig. 2). Zoonotic transmission occurs through contact with the lesions or biologic fluids of an infected animal. Several African studies have reported contact between the index patient and

an animal thought to be the source of interspecies transmission (a rodent in most cases).⁴⁷ These contacts occur during hunting, butchering, or game consumption. However, there has been no virologic confirmation of interspecies transmission to date. Human-to-human transmission occurs primarily through contact with the biologic fluids and infected skin lesions of patients. Contaminated materials, such as bedding, can also be infectious. In Africa, the origin of transmission is often unknown, and the suspected proportions of person-to-person and animal-to-person transmissions vary considerably among studies. In Nigeria, 36 of 122 patients had contact with people with similar skin lesions, and 10 had contact with animals.¹¹ Intrafamilial and nosocomial transmissions have been reported for viral clades 1 and 2^{37,38,48} (Fig. 2). Sexual transmission has been documented in rare cases in African countries.⁴⁹ The household attack rate is highly variable, ranging from 3 to 11% on the basis of historical data to 50% in more recent studies.⁴⁸ This increase may reflect waning immunity to smallpox. Transmission chains are generally short, but up to seven transmission events within a single family have been reported.⁴⁸ The reproduction number (R₀) is estimated to be between 0.6 and 1 for the Central African clade but is lower for West African viruses.^{21,50}

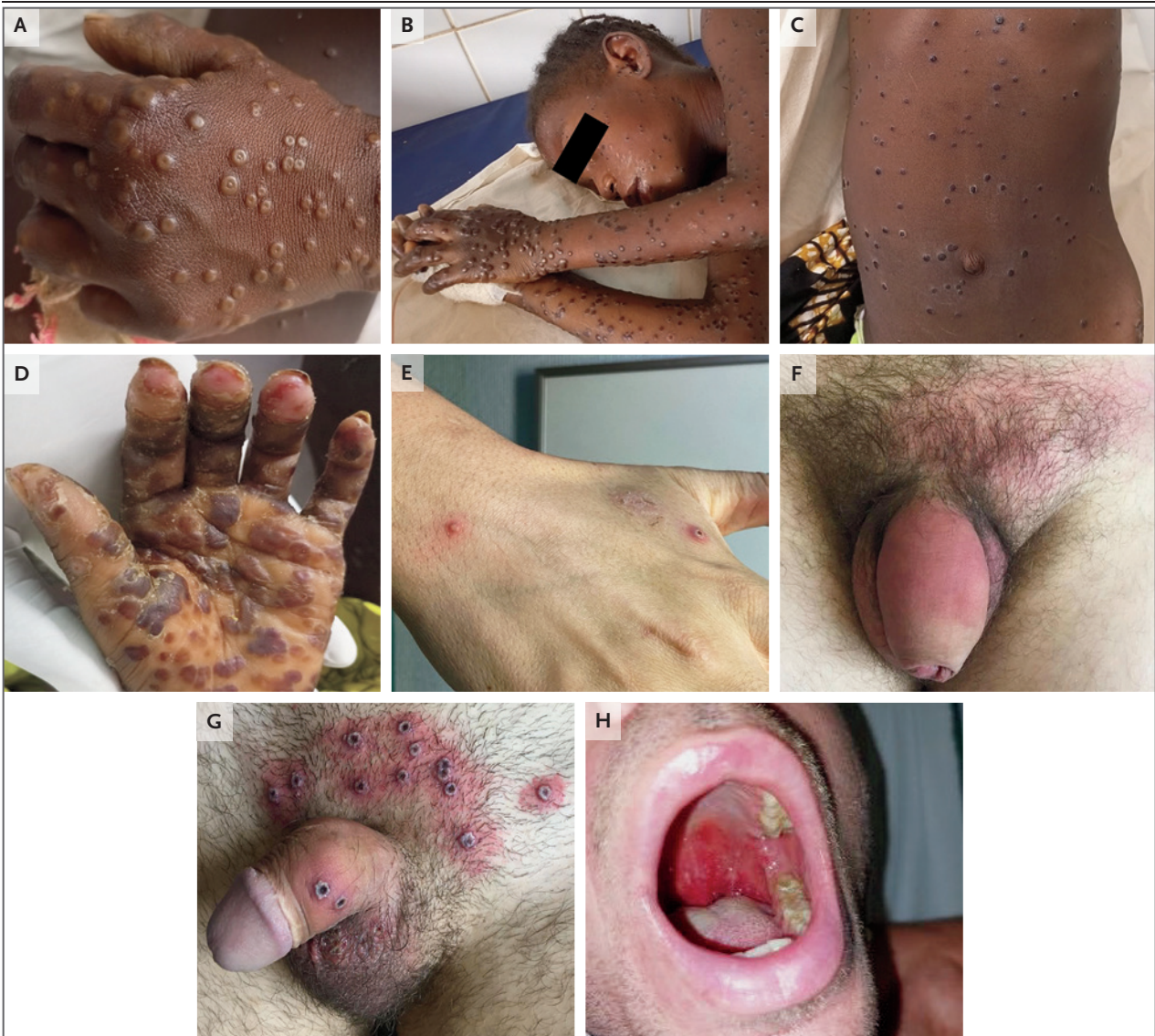

Figure 3. Characteristic Cutaneous and Mucosal Manifestations of Monkeypox.

Panel A shows numerous skin lesions with umbilicated papules on the left hand of a young girl with confirmed monkeypox infection in the Central African Republic. In Panel B, extensive, disseminated papular lesions are present on the hands, arms, and face of a young girl. Panel C shows disseminated skin lesions at different stages of evolution, including papules and crusts, on the abdomen of a young girl. In Panel D, numerous skin lesions with hyperpigmentation, crusts, and desquamation are evident on the left hand of a woman with confirmed monkeypox infection. Panel E shows synchronous skin lesions on the right hand of a man who had sex with a man with confirmed monkeypox infection. A fresh pustular lesion is present, as well as an umbilicated papule with progressive central ulceration. Panel F shows penile edema in a man who had sex with a man who had confirmed monkeypox infection; erythema and swelling extend to the left inguinal region. In Panel G, genital lesions, including scrotal and penile lesions, are present in a man who had sex with a man. Panel H shows pharyngitis in a man who had sex with a man.

CURRENT OUTBREAK

The first monkeypox case in the current multi-country outbreak was confirmed in the United Kingdom on May 6, 2022, in a man traveling

from Nigeria. Extensive contact tracing identified other cases in his household. However, over the next few days, unlinked cases with no documented history of travel to countries where monkeypox is endemic were reported in the

United Kingdom, suggesting undetected local transmission. New cases were rapidly detected in Portugal and the United States, as well as several other countries. The first confirmed case in the United Kingdom was initially considered to be the likely index case, but this hypothesis was rejected as earlier symptom-onset dates, in late April, were reported for other confirmed cases in Portugal and the United Kingdom. Furthermore, the detection of monkeypox in apparently unconnected persons suggests asymptomatic spread.⁵¹ Given the unusual geographic distribution of cases, the World Health Organization (WHO) and other public health institutions raised the alert as early as May 16, 2022. The current outbreak is due to what we have termed clade 3 monkeypox viruses (derived from the West African clade).⁵² The WHO declared a global health emergency on July 23, 2022.

EPIDEMIOLOGIC FEATURES

By October 7, 2022, a total of 71,096 cases of monkeypox infection had been reported in 107 locations worldwide, with 70,377 of the cases in countries that have not historically reported monkeypox.⁵³ The largest numbers of cases have been reported in the United States, followed by Brazil and Spain. An analysis of 24,677 cases of monkeypox performed by the European Centre for Disease Prevention and Control (ECDC) and the WHO, as of October 4, 2022, showed disproportionate numbers of cases in men (24,235 of 24,616 cases, 98.5%) and especially men between the ages of 31 and 40 years (9725 of 24,638, 39.5%) (<https://monkeypoxreport.ecdc.europa.eu/>). Sexual orientation was known for 10,729 of the male patients, of whom 10,300 (96.0%) identified themselves as MSM.

As of this writing, the current monkeypox outbreak appears to be mainly transmitted in defined gay, bisexual, or MSM sexual networks, although there is some evidence of transmission beyond these groups. Indeed, an increasing number of cases have been reported in women and children. A large proportion of cases have links to health services providing preexposure prophylaxis for HIV infection (74% of HIV-negative cases in the United Kingdom),⁵⁴ and patients frequently report a history of a sexually transmitted infection (STI) in the past year (54.2% of patients in the United Kingdom) and have had 10 or more sexual partners in the past 3 months

(31.8% of patients in the United Kingdom), suggesting that until now, monkeypox has been transmitted mainly in interconnected sexual networks that sustain STI transmission. However, an ascertainment bias cannot be ruled out because of the established relationship between this population and clinical providers with robust services and a broad knowledge of infectious diseases. Thus, the epidemiologic determinants of the outbreak may change markedly in the coming months.

The epidemiologic characteristics of this outbreak are particularly unusual. Not only does the number of monkeypox cases far exceed the numbers previously detected outside areas where the disease is endemic, but also transmission is not linked to travel to such areas and is mostly human-to-human transmission. A pattern of transmission linked to sexual contact is currently predominant in newly affected countries. Higher rates of infection among persons reporting multiple sexual partners and an unusual distribution of lesions, frequently in genital, anal, and perianal areas, may reflect viral transmission through close contact during sex or actual sexual transmission. Finally, monkeypox DNA has been detected in the seminal fluid of affected persons.^{14,55} This finding cannot be considered definitive evidence of infectivity, but it does indicate viral shedding that could potentially contribute to transmission. It remains unclear whether these unusual characteristics reflect changes in the transmission of monkeypox virus.

The potential genetic evolution of the virus was considered even before the current outbreak. An analysis of viral genome diversity in 60 samples from primary and secondary infections in patients from Sankuru District, DRC, led to the detection of four distinct lineages within the Central African clade and revealed gene loss in 17% of the samples that appeared to be correlated with human-to-human transmission.^{6,56} Isidro et al. performed phylogenomic characterization of the first monkeypox viral genome sequences obtained in this epidemic.⁵² They found that the monkeypox virus (lineage B.1) responsible for the epidemic clustered with 2018–2019 cases linked to a country where the infection is endemic (Nigeria) but that the lineage segregated to a different phylogenetic branch, probably reflecting continuous accelerated evolution.

CLINICAL FEATURES

It is probably too early to provide a precise description of the clinical aspects of this monkeypox outbreak. However, they seem to mostly match the clinical features of classic outbreaks, described above, with some differences, a combination that has led to a new pattern. A U.K. Health Security Agency analysis of national cases in this outbreak estimated the mean incubation period at 9.22 days.⁵⁴ An ECDC-WHO analysis of data from 660 patients with at least one type of classic prodromal symptoms showed that 71.4% of the patients presented with systemic symptoms (e.g., fever and headache), and 49.0% had a localized lymphadenopathy. In the same analysis, 97.7% of the patients had a rash during the eruptive phase, 70.5% had anogenital skin and mucosal lesions, and 7.0% had oral skin and mucosal lesions (Table 1). In the current outbreak, however, lesions are also being observed without a prodromal phase in a large proportion of patients.⁵⁷ In one analysis, 13.7% of patients presented with mucocutaneous manifestations in the absence of systemic features.⁵⁸

The number of skin lesions is highly variable, with some patients presenting with only a few painless lesions. The skin lesions also appear to be asynchronous, ranging from single or clustered spots to umbilicated papules with progressive central ulceration and, finally, scabs,¹⁴ in contrast to the previously described pattern of simultaneous progression (Fig. 3). In addition, the pattern of skin lesions is unusual, often in genital, anal, and perianal areas, without the typical centrifugal distribution^{15,55,57-60} (Table 1), and cases of proctitis and pharyngitis have also been described (Fig. 3). In one study, mucosal lesions were reported in 41% of the patients.⁵⁵ Involvement of the anorectal mucosa was reported as the presenting symptom in 12% of cases, with anorectal pain, proctitis, tenesmus, diarrhea, or a combination of these symptoms. Rectal pain or pain on defecation is commonly reported. Oropharyngeal symptoms, including pharyngitis,odynophagia, epiglottitis, and oral or tonsillar lesions, were reported as the initial symptoms in 5% of cases in that study. In another study,⁶¹ reported from Spain, 43.1% of patients had lesions in the oral and perioral region.

Previous studies have shown that the clade 2 monkeypox virus causes mild disease, with a case fatality ratio of less than 1%,⁶² which is

consistent with the low rates of hospitalization and death reported to date in this outbreak. The hospitalization rate is estimated to be 5 to 10%.⁵⁸ Hospitalizations are related to cellulitis, in particular involving the genital and perineal region; severe anal and digestive involvement with rectal pain, penile edema, severe angina, and epiglottitis; and ocular involvement with blepharitis, conjunctivitis, and keratitis (Fig. 3). Two fatal cases that were recently reported in young, healthy, nonimmunocompromised MSM appeared to be related to encephalitis; these cases are still under investigation.

VACCINATION AND TREATMENT

The treatments currently authorized for monkeypox are tecovirimat in the United States and Europe and brincidofovir in the United States alone. Tecovirimat inhibits the orthopoxvirus protein p37, blocking cell-to-cell viral transmission. Although tecovirimat is approved for the treatment of smallpox in the United States, its use for monkeypox is based on an investigational new drug application, and the agent has not received full regulatory approval. The efficacy of tecovirimat has been shown in preclinical studies, including four pivotal studies in nonhuman primates showing that the drug provided 95% protection from death, as compared with placebo.⁶³ Phase 1 and 2 clinical trials^{64,65} have assessed the safety and side-effect profile of tecovirimat in humans. A recent observational study involving a very small number of patients with monkeypox suggested that tecovirimat may reduce the duration of viral shedding and illness.⁶⁶

Brincidofovir inhibits the viral DNA polymerase.⁶⁷ The efficacy of this agent in improving survival after infection has been shown in mice and rabbits.⁶⁸ Its safety in humans was assessed in clinical trials for cytomegalovirus disease in recipients of hematopoietic stem-cell transplants.⁶⁹ Brincidofovir has gastrointestinal and hepatic toxic effects, and its safety profile is inferior to that of tecovirimat.

Randomized clinical trials are needed to evaluate the efficacy of these drugs, regardless of their authorization status. The WHO and several countries are implementing such trials, especially with tecovirimat.^{70,71} This evaluation should be performed not only in the countries affected

by the current outbreak but also in areas where the disease is endemic. Availability for second-line treatment may be important, given the potential occurrence of resistance with first-line treatments.

Vaccinia immune globulin, purified plasma gamma globulins retrieved from persons vaccinated with live vaccinia virus vaccine,⁷² is licensed in the United States for the treatment of complications of smallpox vaccination. Other treatments currently under development include chemical compounds and monoclonal antibodies. NIOCH-14, a synthetic analogue of tecovirimat, has passed phase 1 trials.⁷³ Several laboratories are currently developing monoclonal antibodies, with preclinical trials already under way.⁷³

The vaccines available for dealing with the current outbreak are ACAM2000 and MVA-BN. ACAM2000 (Emergent BioSolutions) is a second-generation live, attenuated vaccinia virus vaccine with Food and Drug Administration (FDA) approval for use before or after exposure to monkeypox. It is effective but associated with a risk of cardiac complications.⁷⁴ MVA-BN is a third-generation live, attenuated, nonreplicating, modified vaccinia Ankara vaccine developed by Bavarian Nordic. The vaccine is approved for smallpox prevention in the United States and Europe and was licensed by the FDA in 2019 for monkeypox prevention.⁷⁵ LC16m8 (KM Biologics),⁷⁶ a third-generation, highly attenuated vaccinia virus vaccine, is also licensed for use against smallpox, but it is not currently authorized for monkeypox prevention.

MVA-BN has received emergency approval from several national health authorities, notably in France,⁷⁷ for the postexposure prevention of monkeypox infection, allowing ring-vaccination strategies for contacts at high risk for infection in the current outbreak. Given the increase in

the incidence of the disease and difficulties diagnosing cases and tracing contacts, some countries, including the United Kingdom and France, are now recommending offering third-generation smallpox vaccines to men considered to be at high risk for exposure.⁷⁸

CONCLUSIONS

The gradual decline in immunity to smallpox may partly explain an increase in the incidence of monkeypox in some regions where the disease is endemic. However, the current epidemic reminds us that viral emergence is a permanent phenomenon without boundaries and is often unpredictable in its nature, target, and magnitude. This outbreak illustrates how a disease affecting one region of the world can have a strong effect on areas where it is not endemic, with different target populations and new clinical presentations. To thwart the continuation of the current monkeypox epidemic, both in the African areas where it is endemic and in newly affected regions, the priorities are clear: first, increase awareness and education of populations, especially at-risk groups, to prevent infection and reduce transmission and spread; second, develop rapid, sensitive point-of-care detection tests to improve diagnosis and, consequently, prevention; and third, evaluate the effectiveness of existing treatments, vaccines, and vaccination strategies and improve efforts to make vaccination and treatment available to all affected groups and regions.

Disclosure forms provided by the authors are available with the full text of this article at NEJM.org.

We thank Marina Moroli-Gessain and Olivier Cassar for help with earlier versions of the figures, Erica Telford and Morgane Mailhe for assistance in preparing an earlier version of the manuscript, and patients for their permission to include clinical photographs.

REFERENCES

1. von Magnus P, Andersen EK, Petersen KB, Birch-Andersen A. A pox-like disease in cynomolgus monkeys. *Acta Pathol Microbiol Scand* 1959;46:156-76.
2. Arita I, Henderson DA. Smallpox and monkeypox in non-human primates. *Bull World Health Organ* 1968;39:277-83.
3. Ladnyj ID, Ziegler P, Kima E. A human infection caused by monkeypox virus in Basankusu Territory, Democratic Republic of the Congo. *Bull World Health Organ* 1972;46:593-7.
4. Lourie B, Bingham PG, Evans HH, Foster SO, Nakano JH, Herrmann KL. Human infection with monkeypox virus: laboratory investigation of six cases in West Africa. *Bull World Health Organ* 1972;46:633-9.
5. Beer EM, Rao VB. A systematic review of the epidemiology of human monkeypox outbreaks and implications for outbreak strategy. *PLoS Negl Trop Dis* 2019; 13(10):e0007791.
6. Bunge EM, Hoet B, Chen L, et al. The changing epidemiology of human monkeypox — a potential threat? A systematic review. *PLoS Negl Trop Dis* 2022;16(2): e0010141.
7. Reed KD, Melski JW, Graham MB, et al. The detection of monkeypox in humans in the Western Hemisphere. *N Engl J Med* 2004;350:342-50.
8. Mauldin MR, McCollum AM, Nakazawa YJ, et al. Exportation of monkeypox virus from the African Continent. *J Infect Dis* 2022;225:1367-76.
9. Nguyen PY, Ajisegiri WS, Costantino V, Chughtai AA, MacIntyre CR. Reemergence of human monkeypox and declin-

- ing population immunity in the context of urbanization, Nigeria, 2017–2020. *Emerg Infect Dis* 2021;27:1007-14.
10. Ogoina D, Izbewule JH, Ogunleye A, et al. The 2017 human monkeypox outbreak in Nigeria — report of outbreak experience and response in the Niger Delta University Teaching Hospital, Bayelsa State, Nigeria. *PLoS One* 2019;14(4): e0214229.
 11. Yinka-Ogunleye A, Aruna O, Dalhat M, et al. Outbreak of human monkeypox in Nigeria in 2017-18: a clinical and epidemiological report. *Lancet Infect Dis* 2019; 19:872-9.
 12. Hobson G, Adamson J, Adler H, et al. Family cluster of three cases of monkeypox imported from Nigeria to the United Kingdom, May 2021. *Euro Surveill* 2021; 26:2100745.
 13. Rao AK, Schulte J, Chen T-H, et al. Monkeypox in a traveler returning from Nigeria — Dallas, Texas, July 2021. *MMWR Morb Mortal Wkly Rep* 2022;71: 509-16.
 14. Antinori A, Mazzotta V, Vita S, et al. Epidemiological, clinical and virological characteristics of four cases of monkeypox support transmission through sexual contact, Italy, May 2022. *Euro Surveill* 2022;27:2200421.
 15. Perez Duque M, Ribeiro S, Martins JV, et al. Ongoing monkeypox virus outbreak, Portugal, 29 April to 23 May 2022. *Euro Surveill* 2022;27:2200424.
 16. Vivancos R, Anderson C, Blomquist P, et al. Community transmission of monkeypox in the United Kingdom, April to May 2022. *Euro Surveill* 2022;27:2200422.
 17. Kluge H, Ammon A. Monkeypox in Europe and beyond — tackling a neglected disease together. *Euro Surveill* 2022; 27:2200482.
 18. Moss B. Poxviridae: the viruses and their replication. In: Knipe DM, Howley PM, eds. *Fields' virology* 5th ed. New York: Lippincott Williams and Wilkins, 2007:2905-46.
 19. Damon IK. Poxviruses. In: Knipe DM, Howley PM, eds. *Fields' virology* 5th ed. New York: Lippincott Williams and Wilkins, 2007:2947-76.
 20. Cardeti G, Gruber CEM, Eleni C, et al. Fatal outbreak in tonkean macaques caused by possibly novel orthopoxvirus, Italy, January 2015. *Emerg Infect Dis* 2017;23:1941-9.
 21. Fine PE, Jezek Z, Grab B, Dixon H. The transmission potential of monkeypox virus in human populations. *Int J Epidemiol* 1988;17:643-50.
 22. Rimoin AW, Mulembakani PM, Johnston SC, et al. Major increase in human monkeypox incidence 30 years after smallpox vaccination campaigns cease in the Democratic Republic of Congo. *Proc Natl Acad Sci U S A* 2010;107:16262-7.
 23. Chen N, Li G, Liszewski MK, et al. Virulence differences between monkeypox virus isolates from West Africa and the Congo basin. *Virology* 2005;340:46-63.
 24. Likos AM, Sammons SA, Olson VA, et al. A tale of two clades: monkeypox viruses. *J Gen Virol* 2005;86:2661-72.
 25. Happi C, Adetifa I, Mbala P, et al. Urgent need for a non-discriminatory and non-stigmatizing nomenclature for monkeypox virus. *PLoS Biol* 2022;20(8): e3001769.
 26. Doty JB, Malekani JM, Kalemba LN, et al. Assessing monkeypox virus prevalence in small mammals at the human-animal interface in the Democratic Republic of the Congo. *Viruses* 2017;9:283.
 27. Khodakevich L, Jezek Z, Kinzanzka K. Isolation of monkeypox virus from wild squirrel infected in nature. *Lancet* 1986;1: 98-9.
 28. Radonić A, Metzger S, Dabrowski PW, et al. Fatal monkeypox in wild-living sooty mangabey, Côte d'Ivoire, 2012. *Emerg Infect Dis* 2014;20:1009-11.
 29. Tice MS, Harrigan RJ, Thomassen HA, Smith TB. Ghosts of infections past: using archival samples to understand a century of monkeypox virus prevalence among host communities across space and time. *R Soc Open Sci* 2018;5:171089.
 30. Reynolds MG, Doty JB, McCollum AM, Olson VA, Nakazawa Y. Monkeypox re-emergence in Africa: a call to expand the concept and practice of One Health. *Expert Rev Anti Infect Ther* 2019;17:129-39.
 31. Tesh RB, Watts DM, Sbrana E, Siirin M, Popov VL, Xiao SY. Experimental infection of ground squirrels (*Spermophilus tridecemlineatus*) with monkeypox virus. *Emerg Infect Dis* 2004;10:1563-7.
 32. Jezek Z, Szczeniowski M, Paluku KM, Mutombo M. Human monkeypox: clinical features of 282 patients. *J Infect Dis* 1987; 156:293-8.
 33. McCollum AM, Damon IK. Human monkeypox. *Clin Infect Dis* 2014;58:260-7.
 34. Learned LA, Reynolds MG, Wassa DW, et al. Extended interhuman transmission of monkeypox in a hospital community in the Republic of the Congo, 2003. *Am J Trop Med Hyg* 2005;73:428-34.
 35. Doshi RH, Guagliardo SAJ, Doty JB, et al. Epidemiologic and ecologic investigations of monkeypox, Likouala department, Republic of the Congo, 2017. *Emerg Infect Dis* 2019;25:281-9.
 36. Berthet N, Nakouné E, Whist E, et al. Maculopapular lesions in the Central African Republic. *Lancet* 2011;378:1354.
 37. Besombes C, Gonofio E, Konamna X, et al. Intrafamily transmission of monkeypox virus, Central African Republic, 2018. *Emerg Infect Dis* 2019;25:1602-4.
 38. Nakoune E, Lampaert E, Ndjapou SG, et al. A nosocomial outbreak of human monkeypox in the Central African Republic. *Open Forum Infect Dis* 2017;4:ofx168.
 39. Di Giulio DB, Eckburg PB. Human monkeypox: an emerging zoonosis. *Lancet Infect Dis* 2004;4:15-25.
 40. Huhn GD, Bauer AM, Yorita K, et al. Clinical characteristics of human monkeypox, and risk factors for severe disease. *Clin Infect Dis* 2005;41:1742-51.
 41. Petersen E, Kantele A, Koopmans M, et al. Human monkeypox: epidemiologic and clinical characteristics, diagnosis, and prevention. *Infect Dis Clin North Am* 2019;33:1027-43.
 42. Jezek Z, Szczeniowski M, Paluku KM, Mutombo M, Grab B. Human monkeypox: confusion with chickenpox. *Acta Trop* 1988;45:297-307.
 43. Hutin YJ, Williams RJ, Malfait P, et al. Outbreak of human monkeypox, Democratic Republic of Congo, 1996 to 1997. *Emerg Infect Dis* 2001;7:434-8.
 44. Rimoin AW, Kisalu N, Kebela-Ilunga B, et al. Endemic human monkeypox, Democratic Republic of Congo, 2001–2004. *Emerg Infect Dis* 2007;13:934-7.
 45. Hughes CM, Liu L, Davidson WB, et al. A tale of two viruses: coinfections of monkeypox and varicella zoster virus in the Democratic Republic of Congo. *Am J Trop Med Hyg* 2020;104:604-11.
 46. Hoff NA, Doshi RH, Colwell B, et al. Evolution of a disease surveillance system: an increase in reporting of human monkeypox disease in the Democratic Republic of the Congo, 2001–2013. *Int J Trop Dis Health* 2017;25:1JTDH.35885.
 47. Doshi RH, Alfonso VH, Morier D, et al. Monkeypox rash severity and animal exposures in the Democratic Republic of the Congo. *Ecohealth* 2020;17:64-73.
 48. Nolen LD, Osadebe L, Katomba J, et al. Extended human-to-human transmission during a monkeypox outbreak in the Democratic Republic of the Congo. *Emerg Infect Dis* 2016;22:1014-21.
 49. Vandenbogaert M, Kwasiorski A, Gonofio E, et al. Nanopore sequencing of a monkeypox virus strain isolated from a pustular lesion in the Central African Republic. *Sci Rep* 2022;12:10768.
 50. McMullen CL, Mulembakani P, Hoff NA, et al. Human monkeypox transmission dynamics thirty years after smallpox eradication in the Sankuru district, democratic republic of Congo. *Am J Trop Med Hyg* 2015;93:341.
 51. Ferré VM, Bachelard A, Zaidi M, et al. Detection of monkeypox virus in anorectal swabs from asymptomatic men who have sex with men in a sexually transmitted infection screening program in Paris, France. *Ann Intern Med* 2022 August 16 (Epub ahead of print).
 52. Isidro J, Borges V, Pinto M, et al. Phylogenomic characterization and signs of microevolution in the 2022 multi-country outbreak of monkeypox virus. *Nat Med* 2022;28:1569-72.
 53. Centers for Disease Control and Prevention. 2022 monkeypox outbreak global map. September 20, 2022 (<https://www>

- .cdc.gov/poxvirus/monkeypox/response/2022/world-map.html).
54. UK Health Security Agency. Investigation into monkeypox outbreak in England: technical briefing 2. September 2, 2022 (<https://www.gov.uk/government/publications/monkeypox-outbreak-technical-briefings/investigation-into-monkeypox-outbreak-in-england-technical-briefing-2>).
55. Thornhill JP, Barkati S, Walmsley S, et al. Monkeypox virus infection in humans across 16 countries — April–June 2022. *N Engl J Med* 2022;387:679-91.
56. Kugelman JR, Johnston SC, Mulembakani PM, et al. Genomic variability of monkeypox virus among humans, Democratic Republic of the Congo. *Emerg Infect Dis* 2014;20:232-9.
57. Patrocinio-Jesus R, Peruzzo F. Monkeypox genital lesions. *N Engl J Med* 2022;387:66.
58. Patel A, Bilinska J, Tam JCH, et al. Clinical features and novel presentations of human monkeypox in a central London centre during the 2022 outbreak: descriptive case series. *BMJ* 2022;378:e072410.
59. Davido B, D'anglejan E, Jourdan J, Robinault A, Davido G. Monkeypox 2022 outbreak: cases with exclusive genital lesions. *J Travel Med* 2022;29:taac077.
60. Hammerschlag Y, MacLeod G, Papadakis G, et al. Monkeypox infection presenting as genital rash, Australia, May 2022. *Euro Surveill* 2022;27:2200411.
61. Tarín-Vicente EJ, Alemany A, Agud-Dios M, et al. Clinical presentation and virological assessment of confirmed human monkeypox virus cases in Spain: a prospective observational cohort study. *Lancet* 2022;400:661-9.
62. Sklenovská N, Van Ranst M. Emergence of monkeypox as the most important orthopoxvirus infection in humans. *Front Public Health* 2018;6:241.
63. Grosenbach DW, Honeychurch K, Rose EA, et al. Oral tecovirimat for the treatment of smallpox. *N Engl J Med* 2018;379:44-53.
64. Jordan R, Chinsangaram J, Bolken TC, et al. Safety and pharmacokinetics of the antiorthopoxvirus compound ST-246 following repeat oral dosing in healthy adult subjects. *Antimicrob Agents Chemother* 2010;54:2560-6.
65. Chinsangaram J, Honeychurch KM, Tyavanagimatt SR, et al. Safety and pharmacokinetics of the anti-orthopoxvirus compound ST-246 following a single daily oral dose for 14 days in human volunteers. *Antimicrob Agents Chemother* 2012;56:4900-5.
66. Adler H, Gould S, Hine P, et al. Clinical features and management of human monkeypox: a retrospective observational study in the UK. *Lancet Infect Dis* 2022;22:1153-62.
67. Chan-Tack K, Harrington P, Bensman T, et al. Benefit-risk assessment for brincidofovir for the treatment of smallpox: U.S. Food and Drug Administration's Evaluation. *Antiviral Res* 2021;195:105182.
68. Food and Drug Administration. Tembexa (brincidofovir): highlights of prescribing information. June 2021 (https://www.accessdata.fda.gov/drugsatfda_docs/label/2021/214460s000,214461s000lbl.pdf).
69. Marty FM, Winston DJ, Rowley SD, et al. CMX001 to prevent cytomegalovirus disease in hematopoietic-cell transplantation. *N Engl J Med* 2013;369:1227-36.
70. Sherwat A, Brooks JT, Birnkrant D, Kim P. Tecovirimat and the treatment of monkeypox — past, present, and future considerations. *N Engl J Med* 2022;387:579-81.
71. French National Agency for Research on AIDS. Monkeypox: CORE protocol for an international trial of the safety and efficacy of treatments. July 28, 2022 (<https://www.anrs.fr/en/actualites/1127/monkeypox-core-protocol-international-trial-safety-and-efficacy-treatments>).
72. Wittek R. Vaccinia immune globulin: current policies, preparedness, and product safety and efficacy. *Int J Infect Dis* 2006;10:193-201.
73. WHO Advisory Committee on Variola Virus Research. Report of the twenty-third meeting: virtual meeting, 3–4 November 2021. Geneva: World Health Organization, 2021 (<https://apps.who.int/iris/rest/bitstreams/1423719/retrieve>).
74. Decker MD, Garman PM, Hughes H, et al. Enhanced safety surveillance study of ACAM2000 smallpox vaccine among US military service members. *Vaccine* 2021;39:5541-7.
75. Malarkry M, Gruber M. Food and Drug Administration. Biological License Application approval letter for MVA-BN vaccine, Bavarian Nordic. Silver Spring, MD: Food and Drug Administration, September 24, 2019 (<https://www.fda.gov/media/131079/download>).
76. Eto A, Saito T, Yokote H, Kurane I, Kanatani Y. Recent advances in the study of live attenuated cell-cultured smallpox vaccine LC16m8. *Vaccine* 2015;33:6106-11.
77. Le Guludec D. Avis n° 2022.0034/SESPEV du 20 mai 2022 du collège de la Haute Autorité de Santé relatif à la vaccination contre Monkeypox. Haute Autorité de Santé, May 20, 2022 (https://www.has-sante.fr/upload/docs/application/pdf/2022-05/avis_n2022.0034_sespev_du_20_mai_2022_du_college_de_la_has_relatif_a_la_vaccination_contre_la_variole_du_singe_monkeypox_vir.pdf).
78. UK Health Security Agency. Monkeypox: vaccine to be offered more widely to help control outbreak. June 21, 2022 (<https://www.gov.uk/government/news/monkeypox-vaccine-to-be-offered-more-widely-to-help-control-outbreak>).

Copyright © 2022 Massachusetts Medical Society.