



HAL
open science

Management of ischiopagus twin separation with a focus on W–S incision design

François Ruiz, Cecilia Neiva-Vaz, Marie-Paule Vazquez, Jean-Baptiste Masson, Mohammed El Beheiry, Stéphanie Pannier, Marine de Tienda, Laureline Berteloot, Pauline Lopez, Thomas Blanc, et al.

► To cite this version:

François Ruiz, Cecilia Neiva-Vaz, Marie-Paule Vazquez, Jean-Baptiste Masson, Mohammed El Beheiry, et al.. Management of ischiopagus twin separation with a focus on W–S incision design. *Journal of Pediatric Surgery Case Reports*, 2023, 64, pp.101747. 10.1016/j.epsc.2020.101747 . pasteur-04008441

HAL Id: pasteur-04008441

<https://pasteur.hal.science/pasteur-04008441>

Submitted on 28 Feb 2023

HAL is a multi-disciplinary open access archive for the deposit and dissemination of scientific research documents, whether they are published or not. The documents may come from teaching and research institutions in France or abroad, or from public or private research centers.

L'archive ouverte pluridisciplinaire **HAL**, est destinée au dépôt et à la diffusion de documents scientifiques de niveau recherche, publiés ou non, émanant des établissements d'enseignement et de recherche français ou étrangers, des laboratoires publics ou privés.



Distributed under a Creative Commons Attribution - NonCommercial - NoDerivatives 4.0 International License



Management of ischiopagus twin separation with a focus on W–S incision design

François Ruiz^a, Cecilia Neiva-Vaz^a, Marie-Paule Vazquez^a, Jean-Baptiste Masson^b, Mohammed El Beheiry^{b, c}, Stéphanie Pannier^d, Marine De Tienda^d, Laureline Berteloot^e, Pauline Lopez^f, Thomas Blanc^f, Roman Hossein Khonsari^{a, *}

^a Assistance Publique - Hôpitaux de Paris, Hôpital Universitaire Necker - Enfants Malades, Service de Chirurgie Maxillo-faciale et Chirurgie Plastique, Université de Paris, Paris, France

^b Decision and Bayesian Computation, CNRS UMR 3571, Neuroscience and Computational Biology Department, Institut Pasteur, Paris, France

^c Laboratoire Physico-Chimie Curie, Institut Curie, PSL Research University, Sorbonne Université, CNRS, Paris, France

^d Assistance Publique - Hôpitaux de Paris, Hôpital Universitaire Necker - Enfants Malades, Service de Chirurgie Orthopédique et Traumatologie Pédiatrique, Université de Paris, Paris, France

^e Assistance Publique - Hôpitaux de Paris, Hôpital Universitaire Necker - Enfants Malades, Service D'imagerie Pédiatrique, Université de Paris, Paris, France

^f Assistance Publique - Hôpitaux de Paris, Hôpital Universitaire Necker - Enfants Malades, Service de Chirurgie Viscérale Pédiatrique, Université de Paris, Paris, France

ARTICLE INFO

Keywords:

Ischiopagus
Conjoined twins
Incision design
Plastic surgery

ABSTRACT

Background: Ischiopagus us twins share parts of the spine, central nervous system, gastrointestinal and genitourinary tracts with various degrees of severity. Their separation is a surgical challenge. From the perspective of the plastic surgeon, one of the straightforward technical problems of conjoined twin separation is the coverage of the large residual parietal defects determined by the initial skin incisions.

Methods: Here we report the cases of three sets of separated ischiopagus twins and describe the skin incision design. All patients were females aged 4–6 months at the time of surgery. Semi-automatic segmentation and innovative 3D visualization methods were used and surgery planning was based on MRI and CT-scan data.

Results: The incision design allowed complete coverage for 2/3 sets of twins and specific strategies were defined to optimize secondary grafting procedures in the remaining set.

Conclusions: This report provides a description of relevant incision design strategies for ischiopagus separation to minimize morbidity related to coverage issues, especially in the abdominal and perineal regions.

1. Introduction

Conjoined ischiopagus twins are monozygous twins whose bodies are joined in utero and connected by their pelvis. They represent 10% of all conjoined twins. Their presentation is very variable and asymmetric. In most cases, they are joined end to end, with vertebral axes oriented at 180°, each twin having four normal limbs [1].

The objective of the separation is a balanced organ and skin allocation to each patient [2]. When one only of the components of the set survives, part of the abdominal wall of the other new-born can be used to bridge the defects [3]. In cases where both twins are viable, various procedures such as skin expansion, pedicled flaps and parietal reconstruction using synthetic patches have been proposed in the literature [4].

Nevertheless, even though the separation of inner organs and bones are precisely described in previous cases [5,6], skin incision design, which is crucial for satisfactory coverage, has never been reported.

The aim of this report is to present incisions used for separation in three sets of ischiopagus twins managed in our centre in the last 15 years and to establish a reliable and reproducible separation design.

2. Materials and methods

2.1. Anatomical description and imaging

All sets of twins were females (Figs. 1–3). Twins №1 were referred to our hospital in 2016, twins №2 in 2018 and twins №3 in 2005. All twins were transferred to France before their separation at 4–6 months

* Corresponding author. Service de chirurgie maxillo-faciale et chirurgie plastique, Hôpital Universitaire Necker - Enfants Malades, 149 rue de Sèvres, 75015, Paris, France.

E-mail address: roman.khonsari@aphp.fr (R.H. Khonsari).

<https://doi.org/10.1016/j.epsc.2020.101747>

Received 20 November 2020; Received in revised form 3 December 2020; Accepted 8 December 2020

Available online 11 December 2020

2213-5766/© 2020 Published by Elsevier Inc. This is an open access article under the CC BY-NC-ND license (<http://creativecommons.org/licenses/by-nc-nd/4.0/>).

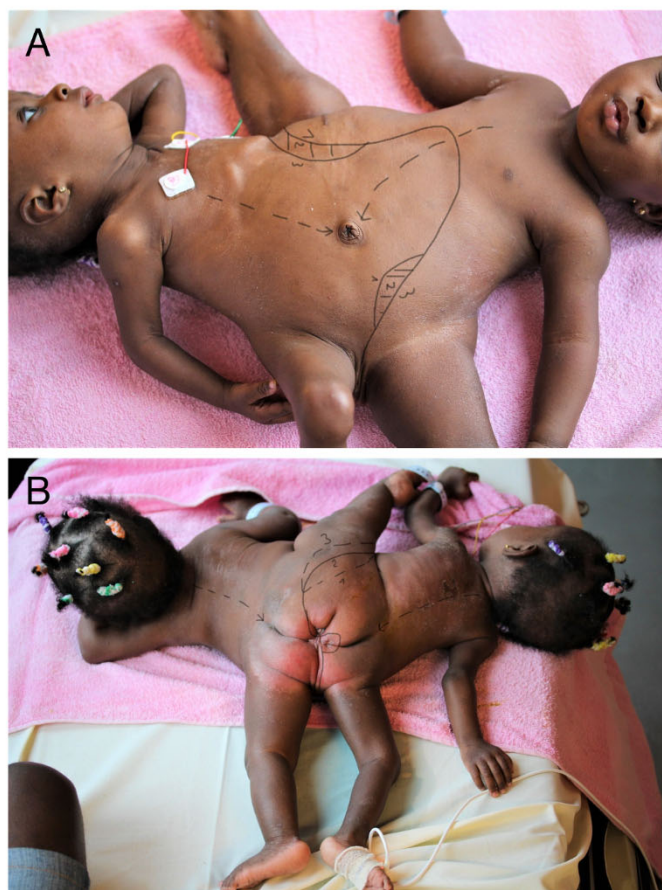


Fig. 1. (A) Three possibilities for the anterior W-shaped incision, allowing various degrees of final wound coverage; case №1. (B) Three possibilities for the posterior S-shaped incision; option 3 allowed maximal coverage of the hip for the twin №1a on the right side.

of age. Twins №1 and №3 had normal cognitive development; in case №2, one twin presented with epilepsy and developmental delay.

A multimodal imaging protocol was applied for pairs №1 and №2. Before CT-scan (45 min. prior), each twin received 300 mL of contrast media 45 minutes for oral digestive opacification. Negative contrast media (mannitol 5%) was used for one twin and positive contrast media

(gastrografine 10%) was used for her sister. Intravenous contrast media (2mL of non-ionic iodine-based contrast media/kg of combined weight) was used for each twin. A biphasic injection was made for one twin – 6 minutes and 60 seconds before image acquisition – in order to obtain a mixed urographic and venous portal phase; a unique injection was made for the twin sister, 40 seconds before image acquisition (late arterial phase). Multiplanar T2-weighted and T1-weighted MRI images were acquired. T1-weighted images were performed without and with injection of gadolinium. Furthermore, radioscopy retrograde opacification of genito-urinary and digestive tracts was performed.

All individuals from the three pairs had one heart, one liver and two kidneys. All sets of twins had a single anus. In cases №1–2, one of the twins had a normal digestive tract from her stomach to the single anus; the digestive tract of the other twin was branching to the tract of her sister at the intestinal level, the colon and the rectum being share by both twins. In case №3, both digestive tracts were symmetrically branching to a common colon, rectum and anus.

Twins №1 had normal genital organs. In twins №2, one newborn had a bicornuate uterus and two hemi-vaginas. Twins №3 shared 4 hemi-uterus and 2 blind vaginas.

Twins №2–3 had four normal lower limbs. In twins №1, a merged joint leg was vascularized by the right iliac artery (Table 1).

We used Mimics 20.0 (Materialise, Leuven, Belgium) in order to segment MRI and CT-scan images from twins №2 and obtained 3D renderings of the skeleton and inner abdominal organs (Fig. 4). The DIVA software (<https://diva.pasteur.fr>) was furthermore used in order to generate interactive 3D reconstructions from CT-scan and MRI data from twins №2, without the need for segmentation (supplementary videos 1, 2). DIVA automatically generated 3D interactive representations of tomographic data in a virtual reality (VR) reality environment compatible with consumer virtual reality (VR) headsets (HTC Vive Pro, Taoyuan, Taiwan) without data pre-treatment or segmentation. VR representations of images were generated by an optimized real-time volume ray casting approach, the entire volume becoming a physical object that could be manipulated, transformed, and annotated. Voxel look-up tables (i.e. transfer functions) were manually adjusted using spline functions to relate voxel intensity values to transparency, brightness, and contrast. Structures of interest in the DICOM images were highlighted using this dedicated interface. An interactive ‘clipping plane’ was used to better visualise local structures within the 3D image; this plane could be translated and rotated using a handheld VR controller included with the VR headset and 2D sagittal, coronal and axial images corresponding to the position of the VR controller were displayed on the correspond-

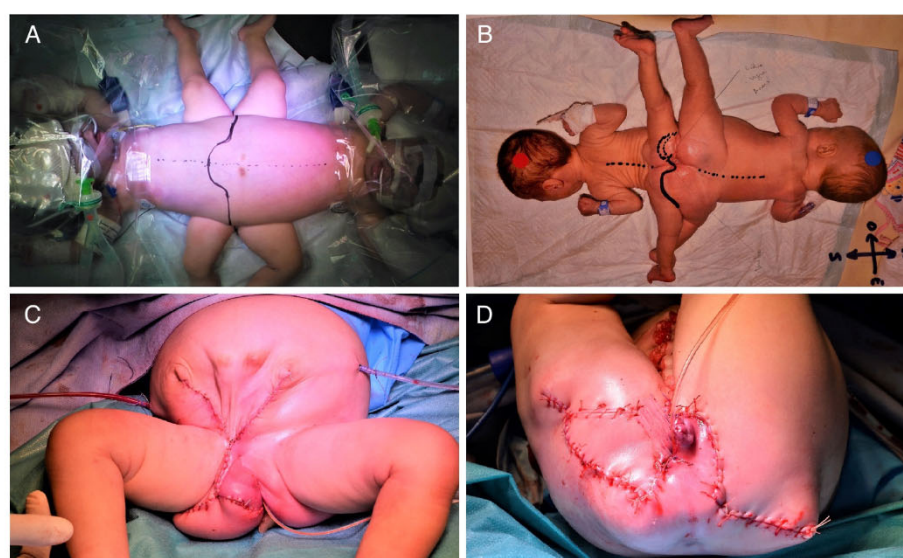


Fig. 2. (A) W–S incision design in case №2. (B) W–S incision design in case №3. (C, D) Complete closure of the perineum skin for both twins in case №2.

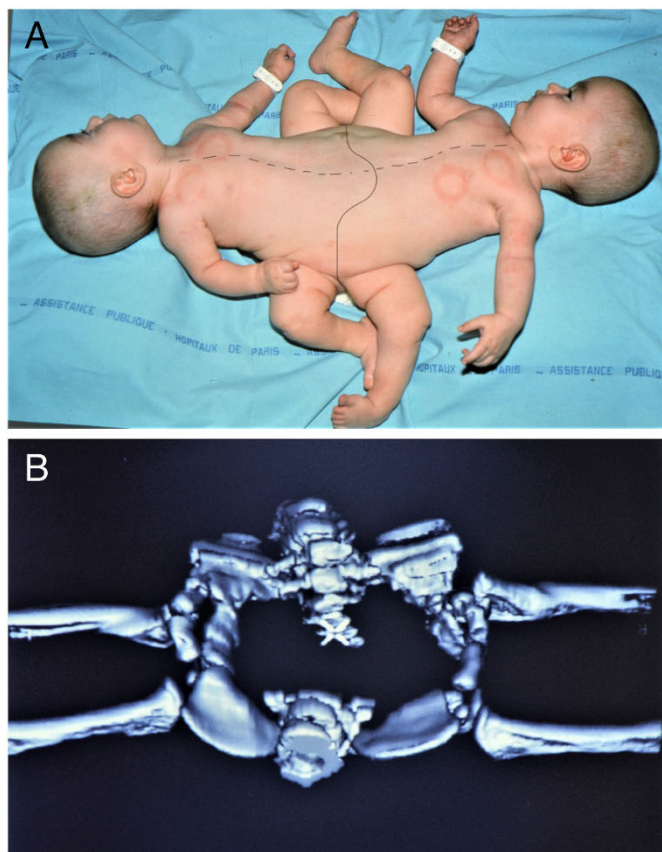


Fig. 3. (A) Anterior W-shaped incision design of case №3. (B) Three-dimensional reconstruction from CT-scan in case №3 showing the joined ischium.

ing sides of the 3D representation. Two landmarks positioned within the 3D volume were used to localise the livers in twins №2 (Supplementary Video 1 based on MRI images). Pre-defined trajectories through 3D reconstructions were recorded for twins №2 according to the requirements of the surgical team, revealing the contours of the digestive tracts and its position relative to the skeleton (Supplementary Video 2 based on CT-scan images).

Supplementary data to this article can be found online at <https://doi.org/10.1016/j.epsc.2020.101747>

2.2. Incision design

All pairs were managed by a multi-disciplinary surgical and anaesthesiology team involving two senior anaesthetists (one for each twin), plastic surgeons, general surgeons and orthopaedic surgeons (Fig. 5).

Table 1

Clinical evaluation of three sets of ischiopagus twins.

	Heart	Liver	Kidney	Ureter	Bladder	Urethra	Uterus	Vagina	Anus	Lower limb	Comment
Case №1a	1	1	2	2	2 (hemi-bladder)	1	1	1	0	1	No colon, rectum and anus
Case №1b	1 (<i>situs inversus</i>)	1	2	2	1	1	1	1	1	2	
Case №2a	1 (dextroposition)	1	2	2	2	1	1	2 hemi (bicornuate) vagina	0	2	Dextroposition of the heart, thoracic and abdominal <i>situs solitus</i>
Case №2b	1	1	2	2	2	1	1	1	1	2	Shared bladders. Each bladder receives one of the ureter of each twin
Case №3a	1	1	2	2	1	1	2 hemi uteri	1	0	2	Blind vagina
Case №3b	1	1	2	2	1	1	2 hemi uteri	1	1	2	Blind vagina.

For the three pairs №1–3, we performed a circumferential incision with an anterior W-shaped design (Figs. 1–3). We marked the thoracic and abdominal midline for each twin. The W-shaped incision allowed raising (1) a large antero-medial flap for the twin with a rectum and an anus, and (2) two antero-lateral flaps for the other twin. This large antero-medial flap was raised to cover the entire pelvic defect and to protect the anus and the rectum. For the twin with the two antero-lateral flaps, less skin was available for coverage: a neo-anus protected by a proximal ileostomy was created with minimal skin tension; areas of controlled wound healing were needed in case №1. In case №2a, skin tension was too high in the pelvic area to allow immediate skin closure. Two possibilities strategies were possible: (1) loss of substance and controlled wound healing as in case №1b or (2) direct closure using a V–Y flap. The loss of substance was larger than in case №1b and case №2a presented developmental delay and poor nutritional status: controlled wound healing was not a good option. A V–Y flap allowed translating a skin triangle from the buttocks to the vulva (Fig. 6). Whereas the anterior incision defines the skin closure of each twin, the posterior incision defined the attribution of genital organs and anus to each twin. This posterior incision was S-shaped; the two curves of the S were used to separate (1) the vulva and the anus of the twin with a functional anus from (2) the vulva and the neo-anus of the other twin. Using this approach, we achieved complete skin closure in 2 cases. In case №1, we modified the S-shaped incision in order to insure both the complete coverage of the perineum and the stump after amputation in one twin, and the coverage of the perineum in the other twin. For this, we exaggerated the curve of the S-shaped flap for the twin with the stump to obtain a larger musculo-cutaneous flap for perineum and stump coverage, resulting in less skin for the other twin. Different designs had initially been considered: incision #3 offered the largest anterior (Fig. 1A) and posterior (Fig. 1B) flaps for skin closure of the twin with the stump, leaving little coverage for her sister. Incision #1 was more balanced in the attribution of skin surfaces, but with more tension expected at closure. We used incision #2 as a compromise, with complete coverage of the perineum and the stump in one twin and area of controlled wound healing for her sister (Fig. 7).

In cases №2–3, the posterior S-shaped incision design allowed straightforward skin closure without the need for alternative design strategies (Fig. 2).

2.3. Post-operative care and complications

After separation, all patients were transferred into an intensive care unit with a mean stay of 16 (9–32) days. Anuria occurred in one of the twins in sets №1 and №2 in the first two post-operative days, leading to pyelo-ureteral anastomosis refection, with post-obstructive anuria occurring in one case. Eventration occurred in one twin from set №1 requiring abdominal wall reconstruction using a Gore-Tex® mesh in the first week after separation.

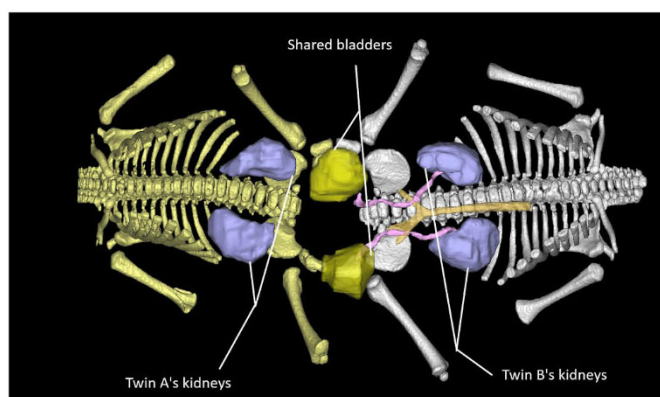


Fig. 4. 3D model of the urinary system in case №2 based on semi-automatic segmentation of soft and hard tissues from pre-operative CT-scans; each twin had 2 kidneys with one ureter; the two bladders received one of the ureters from each twin.



Fig. 5. Setting of the operating room for the separation of pair №2 rendered by artist Christelle Tea [11]. 3D reconstructions were displayed on the walls of the operating room during the procedure.

Delayed wound healing in twin №1b was managed using negative pressure wound therapy followed by a skin graft two weeks after separation (Fig. 8).

After intensive care management, the hospital stay in a surgery ward had an average duration of 38 (28–54) days. All children returned to their home country and the follow-up was performed mostly by telehealth and yearly visits to our department. Two major interventions were necessary for twins №3 after the separation procedures: femoral rotation osteotomy and urinary incompetence surgery at 10 years of age. Twins №1 and №2 may require similar procedures in the future as their follow-up has only reached 4 and 2 years respectively.

3. Discussion

Incisions define the skin surface allocated to each new-born where separating ischiopagus conjoined twins. One critical zone for coverage is the perineum, where skin tension is important with high infection risks, and where the need for restoring transit within short delays has to be taken into account [7]. In our experience, the anterior W-shaped flap design was not always sufficient for direct closure (case №1) and additional plastic surgery techniques were used, such as V–Y flaps (Fig. 6). The hip stump is also critical to cover in cases with only three lower

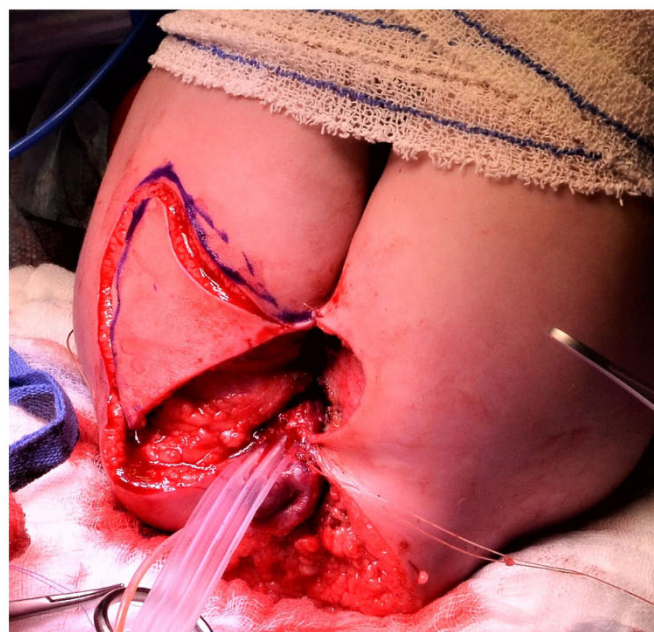


Fig. 6. V–Y flap used for complete closure of the perineum in twin №2a.

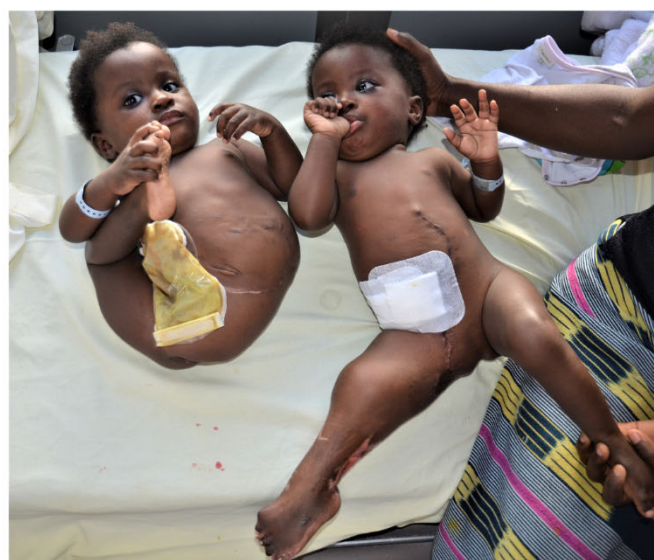

Fig. 7. Case №1a and №1b three weeks after separation: complete coverage of the perineum and the stump in twin №1a and area of controlled wound healing for twin №1b.

limbs [8], due to the osteitis and arthritis risks, and for subsequent rehabilitation. The incision design we proposed required to be discussed and adapted to individual cases with a multidisciplinary team involving plastic surgeons, to propose alternatives or additional techniques for optimal coverage.

Three-dimensional reconstructions from CT-scans and MRIs can be helpful to separate conjoined twins and influence the design of incisions, by providing an accurate anatomical evaluation of the distribution of inner organs [9]. We used three-dimensional models from semi-automatic segmentations of hard and soft tissues on pre-operative CT-scans for case №2, and 3D rendering using innovative visualization techniques (Fig. 4 and Supplementary Videos 1–2). These models were useful in discussions with the orthopaedic and abdominal surgery teams involved in the separation, and for adapting the incisions to the position of the future stoma for the twin with the neo-anus. 3D rendering and planning, with the help of 3D printing in the most complicated

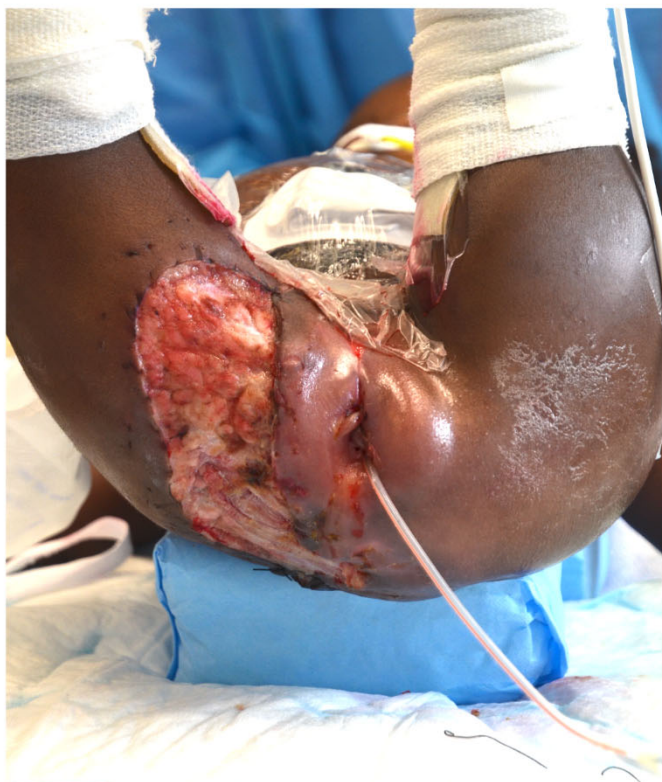

Fig. 8. Area of controlled wound healing before skin graft 15 days after separation in case №1b.

cases involving the craniofacial region, appears to be crucial in conjoined twin separation and helps proposing the optimal skin incision design [10].

4. Conclusion

Conjoined twins separation is a surgical challenge, starting from incision design. In ischiopagus twins, the coverage of the defect left by separation is a constant issue. Here we describe a W–S incision design allowing the full and direct skin coverage in 2/3 cases of ischiopagus twin separation and separation without major post-operative morbidity

in 1/3 case. The W–S incision design appears as a satisfactory compromise in the management of these tricky cases, where plastic surgeons are often at the frontline in the initial steps of the procedure and during final wound closure. This incision pattern has to be adapted to local anatomical constraints, complemented with other techniques such as V–Y plasty, and discussed based on the results of 3D planning.

Declaration of competing interest

The authors declare that they have no known competing financial interests or personal relationships that could have appeared to influence the work reported in this paper.

Acknowledgments

Special thanks to Pr. Arnaud Picard (maxillofacial surgery and plastic surgery), Pr. Yves Aigrain (general surgery), Dr Hortense Alliot (general surgery), Pr. Sabine Sarnacki (general surgery), Pr. Christophe Chardot (general surgery), Pr. Christophe Glorion (orthopaedic surgery), Pr. Nathalie Boddart (imaging) and Pr. Gilles Orliaguet (anaesthesiology and intensive care).

References

- [1] Spencer R Conjoined twins: developmental malformations and clinical implications. Baltimore: Johns Hopkins; 2003. p. 476.
- [2] Chatterjee SK, Chakravarty AK, Demajumdar N, et al. Ischiopagus tetrapus conjoined twins: 22 years after separation. *J Indian Assoc Pediatr Surg* 2009;14: 36–8.
- [3] Yokomori K, Ohkura M, Kitano Y, et al. Comprehensive planning of operative strategy for separation of ischiopagus tripus twins with particular reference to quality of life. *J Pediatr Surg* 1993;28:833–7.
- [4] Tannuri AC, Batatinha JA, Velhote MC, et al. Conjoined twins: twenty years' experience at a reference center in Brazil. *Clinics* 2013;68:371–7.
- [5] Kiely EM, Spitz L The separation procedure. *Semin Pediatr Surg* 2015;24:231–6.
- [6] Albert MC, Drummond DS, O'Neill J, et al. The orthopedic management of conjoined twins: a review of 13 cases and report of 4 cases. *J Pediatr Orthop* 1992;2: 300–7.
- [7] Trost Jr JG, Lin LO, Clark SJ, et al. Separation of thoraco-omphalo-ischiopagus conjoined twins: surgical planning, management, and outcomes. *Plast Reconstr Surg* 2016;138:1064–72.
- [8] Jones D Orthopedic aspects of separation. *Semin Pediatr Surg* 2015;24:249–51.
- [9] Liu X, Dong K, Zheng S, et al. Separation of pygopagus, omphalopagus, and ischiopagus with the aid of three-dimensional models. *J Pediatr Surg* 2018;53: 682–7.
- [10] Dunaway D, Jeelani NU Staged separation of craniopagus twins. *Semin Pediatr Surg* 2015;24:241–8.
- [11] Tea C, Khonsari RH. Bloc opératoire: points de vue (2019), Paris, Hoosh, 152p.

