



HAL
open science

Breast Magnetic Resonance Image Analysis for Surgeons Using Virtual Reality: A Comparative Study

Mohamed El Beheiry, Thomas Gaillard, Noémie Girard, Lauren Darrigues,
Marie Osdoit, Jean-Guillaume Feron, Anne Sabaila, Enora Laas, Virginie
Fourchette, Fatima Laki, et al.

► To cite this version:

Mohamed El Beheiry, Thomas Gaillard, Noémie Girard, Lauren Darrigues, Marie Osdoit, et al.. Breast Magnetic Resonance Image Analysis for Surgeons Using Virtual Reality: A Comparative Study. *JCO Clinical Cancer Informatics*, 2023, 5, pp.1127-1133. 10.1200/CCI.21.00048 . pasteur-04008404

HAL Id: pasteur-04008404

<https://pasteur.hal.science/pasteur-04008404>

Submitted on 28 Feb 2023

HAL is a multi-disciplinary open access archive for the deposit and dissemination of scientific research documents, whether they are published or not. The documents may come from teaching and research institutions in France or abroad, or from public or private research centers.

L'archive ouverte pluridisciplinaire **HAL**, est destinée au dépôt et à la diffusion de documents scientifiques de niveau recherche, publiés ou non, émanant des établissements d'enseignement et de recherche français ou étrangers, des laboratoires publics ou privés.



Distributed under a Creative Commons Attribution - NonCommercial - NoDerivatives 4.0
International License

IMAGING

original reports

abstract

Breast Magnetic Resonance Image Analysis for Surgeons Using Virtual Reality: A Comparative Study

Mohamed El Beheiry, PhD¹; Thomas Gaillard, MD²; Noémie Girard, MD²; Lauren Darrigues, MD²; Marie Osdoit, MD²; Jean-Guillaume Feron, MD²; Anne Sabaila, MD²; Enora Laas, MD²; Virginie Fourchette, MD²; Fatima Laki, MD²; Fabrice Lecuru, MD, PhD²; Benoit Couturaud, MD²; Jean-Philippe Binder, MD²; Jean-Baptiste Masson, PhD¹; Fabien Reyat, MD, PhD^{2,3}; and Caroline Malhaire, MD^{4,5}

PURPOSE The treatment of breast cancer, the leading cause of cancer and cancer mortality among women worldwide, is mainly on the basis of surgery. In this study, we describe the use of a medical image visualization tool on the basis of virtual reality (VR), entitled DIVA, in the context of breast cancer tumor localization among surgeons. The aim of this study was to evaluate the speed and accuracy of surgeons using DIVA for medical image analysis of breast magnetic resonance image (MRI) scans relative to standard image slice-based visualization tools.

MATERIALS AND METHODS In our study, residents and practicing surgeons used two breast MRI reading modalities: the common slice-based radiology interface and the DIVA system in its VR mode. Metrics measured were compared in relation to postoperative anatomical-pathologic reports.

RESULTS Eighteen breast surgeons from the Institut Curie performed all the analysis presented. The MRI analysis time was significantly lower with the DIVA system than with the slice-based visualization for residents, practitioners, and subsequently the entire group ($P < .001$). The accuracy of determination of which breast contained the lesion significantly increased with DIVA for residents ($P = .003$) and practitioners ($P = .04$). There was little difference between the DIVA and slice-based visualization for the determination of the number of lesions. The accuracy of quadrant determination was significantly improved by DIVA for practicing surgeons ($P = .01$) but not significantly for residents ($P = .49$).

CONCLUSION This study indicates that the VR visualization of medical images systematically improves surgeons' analysis of preoperative breast MRI scans across several different metrics irrespective of surgeon seniority.

JCO Clin Cancer Inform 5:1127-1133. © 2021 by American Society of Clinical Oncology

Creative Commons Attribution Non-Commercial No Derivatives 4.0 License 

INTRODUCTION

Breast cancer (BC) is the leading cause of cancer and cancer mortality among women worldwide. In 2018, 2.1 million BC diagnoses and 626,000 deaths were reported.¹ Of these diagnosed BC cases, it has been shown that 33% are locally advanced.² Surgery is the primary therapeutic strategy of BC.

Efficient carcinogenic and esthetic resection requires breast surgeons to carry out mental projections of planar radiologic images into three-dimensional (3D) surgical scenarios including surgical incision, resections, and remodeling. It also requires mapping of tumor morphologies, geometries, relative positions, and relative volumes within the breast. This 3D representation can be difficult to apprehend initially, especially for younger surgeon practitioners and residents, when analyzing magnetic resonance image (MRI) scans slice-by-slice. It has been reported that only 12% of surgeon medical faculty and 1% of

surgery residents have followed a radiology curriculum in the United States.³ The surgeon, as the last actor in the patient treatment workflow, is hence often limited in the exploitation of the medical image which, for oncology, contains among the most valuable clinical information.

As a means of visualizing 3D structures, virtual reality (VR) is a promising avenue to improve surgical diagnosis and planning.⁴⁻⁶ VR is a natural vehicle through which 3D data can be understood.⁷ When a user wears a VR headset, stereoscopy simulates their sense of sight and their senses of touch and locomotion are realistically imitated with low-latency motion detectors integrated in specialized handheld VR controllers. The combined effect of this sensory simulation is the sensation of total immersion in entirely artificial computer-generated environments. In this study, we sought to present medical images to surgeons in this unique visual context in the form of realistic 3D representations of their patients that we refer to as avatars.

ASSOCIATED CONTENT

Data Supplement

Author affiliations and support information (if applicable) appear at the end of this article.

Accepted on September 29, 2021 and published at ascopubs.org/journal/cci on November 12, 2021: DOI <https://doi.org/10.1200/CCI.21.00048>

CONTEXT

Key Objective

The majority of breast cancer (BC) treatments involve a surgical procedure. Despite this fact, surgeons consistently perform poorly in reading critical surgical staging magnetic resonance image (MRI) examinations of patients with BC, primarily because of a lack of radiologic training. In this study, we evaluate the proficiency of BC surgeons at analyzing MRI examinations represented using standard slice-based radiologic tools and using a previously reported tool, DIVA, which represents MRI examinations as three-dimensional reconstructions in virtual reality.

Knowledge Generated

Compared to standard radiologic tools, we find that surgeons more rapidly and more accurately analyze breast MRI examinations using DIVA. These results hold regardless of surgeon seniority.

Relevance

In DIVA, we demonstrate a method to potentially significantly improve surgeon proficiency in reading MRI examinations without the need for massive retraining. The reported increase in efficiency of medical image reading has the potential to improve surgical planning and greatly improve communication between surgeons and radiologists.

We describe the use of a visualization tool on the basis of VR, entitled DIVA, in the context of BC tumor localization among surgeons. The usefulness of DIVA has already been evaluated in the context of craniofacial trauma education for undergraduate medical students with promising results and outside the medical context for microscopy images associated with scientific research.^{8,9}

The aim of this study was to quantitatively evaluate the speed and accuracy of surgeons using DIVA for medical image analysis of breast MRI sequences relative to standard image slice-based visualization.

MATERIALS AND METHODS

Participants

We included 18 breast surgeons from the Gynecological, Breast and Reconstructive Cancer Surgery department at the Institut Curie to perform all the analysis. These surgeons included nine residents and nine practicing surgeons. This surgery department is part of a large tertiary cancer center, consistently ranked among the best in France and Europe, and was responsible for more than 3,200 surgeries in 2019.¹⁰ Each practicing surgeon participant will have operated several hundred patients with BC per year.

Images

We selected MRI sequences from 25 patients who had underwent surgery between 10/01/2018 and 20/11/2019 from the Institut Curie Picture Archiving and Communication System (PACS). Among the MRI sequences of operated patients, 14 had a mastectomy and 11 had a lumpectomy performed. Two additional sequences corresponded to healthy control cases for patients not requiring surgery.

All MRI sequences were performed as part of a preoperative staging. The standard breast MRI protocol included T2 sequences, T1 gradient-echo sequences, and injected dynamic 3D sequences with a gadolinium-containing

contrast agent. Only the T1-weighted contrast-enhanced MRI examination was used in this study. MRI data were collected from the computer server of the radiology department and anonymized with subject identification codes. Images selected included normal tests from screening of high-risk women and BC cases absent of neoadjuvant chemotherapy. MRI sequences that were difficult to analyze because of the presence of a marked masking background glandular enhancement (BIRADS type C and D) were excluded.¹¹

DIVA Software

DIVA is a previously reported software platform that instantaneously generates 3D patient reconstructions from original MRI scans in their native DICOM file format.^{7,8,12,13} These patient reconstructions, or patient avatars, are rendered using a volumetric ray-casting technique.¹⁴ In contrast to surface rendering approaches (eg, segmentation), this technique allows all pixels of the image to be rendered simultaneously and to have their characteristics (eg, transparency, color, and lighting effects) modified in real time.

DIVA works on a dual usage mode principle. The first mode is a desktop interface, which contains basic input and output functions as well as a widget to modify the patient avatar representation using a specialized 3D lookup table or filter. The second usage mode is the VR interface, which allows navigation and visualization of the full patient avatar in an immersive context. Patient avatar visualizations were on the basis of predefined filters with a radiologist. Users were able to grasp avatars with VR controllers and orient them in space to facilitate their analyses of the MRI. In this study, physicians used solely DIVA's VR interface with the HTC Vive VR headset.

Data Collection and Visualization

In our study, residents and practicing surgeons used two image reading modalities: T1-weighted contrast-enhanced

MRI examination using the radiologic slice-based interface common to PACS frontend software and by using DIVA in its VR mode. For the slice-based modality, we used the image viewer available at the Institut Curie, which is developed by Carestream Health (Rochester, New York). Surgeon participants were free to use all software features available in the PACS image viewer. Figure 1 illustrates the two image analysis modalities. Additionally, a recording of the use of DIVA in the context of this study is available in the Data Supplement.

For each physician participating in the study, we measured the time taken to analyze the images using the different approaches (slice-based and DIVA). Time taken to analyze the images was the uninterrupted time interval measured from the start of looking at the images until the surgeons indicated their analysis was complete. We recorded the results of their readings concerning the tumor and the envisaged surgical strategy. For time measurements, we additionally used the radiologist report as a modality for analyzing the case (without the use of the MRI).

Each surgeon analyzed three randomly selected MRI scans for each modality, making nine total image analyses per surgeon (on nine different patients). We note that some technical issues during the surgeon interview process meant that not all surgeons evaluated exactly nine cases. Table 1 shows the cases evaluated across the different groups.

Outcomes

Speed was defined as the analysis time required to produce a conclusion on tumor localization and surgical strategy. Accuracy metrics were defined in relation to the postoperative anatomical-pathologic report in a binary true or false manner. Three metrics were measured to ascertain the accuracy of the tumor localization: breast determination (ie, in which breast the tumor was located), number of lesions, and breast quadrant localization. Additionally, surgeons were asked to envisage a surgical strategy on the basis of their analyses, which was then compared with the actual surgical treatment performed on the patient.

As the quadrant in which the lesion is located can be subject to different interpretations (eg, a quadrant chosen in the MRI may not correspond to the same quadrant in a

mammogram), we associated each quadrant with the two adjacent quadrant interfaces as the same answer. For example, the union of the lower quadrants and the lower-inner quadrant would be considered the same answer.

Statistical Analysis

All practicing surgeon responses were compared using the generalized likelihood ratio tests. Analysis times between different approaches (ie, DIVA and slice-based) were compared with the Kolmogorov-Smirnov test. All statistical tests used a significance level of 5% (ie, P value $< .05$). Analyses were performed using Python and associated SciPy and scikit-learn libraries.^{15,16}

RESULTS

Speed

The analysis time required to determine the number of lesions and their location was significantly lower with the DIVA system than with the slice-based visualization, for residents, practicing surgeons, and subsequently in the entire group ($P < .001$). The analysis time of the DIVA system was comparable to the time needed to read the radiologist report to reach conclusions on the location of the different lesions ($P = .14$ in the entire group). A box plot and histograms of the time taken to analyze the images between all modalities are shown in Figure 2. The median time with DIVA was 37 seconds compared to 145 seconds with the slice-based visualization, and 45 seconds with the text-only radiologist report.

Accuracy—Breast Determination

Regarding the determination of which breast contained the lesion or lesions, 59.3% of the residents and 79.2% of experienced practicing surgeons were correct in their determinations using the slice-based visualization. With the DIVA system, this proportion of correct answers for the residents and practicing surgeons was significantly higher at 91.7% ($P = .003$) and 95.8% ($P = .04$), respectively, as shown in the spider plots of Figure 3.

Accuracy—Number of Lesions

For the determination of the number of lesions, 66.7% of the residents determined this information correctly using the slice-based visualization. This percentage was 75% using the DIVA system ($P = .49$). For experienced surgeons,

FIG 1. Two medical image visualization modalities used in this study: (A) slice-based visualization of MRI scan using viewing feature available with the hospital PACS and (B) immersive visualization using DIVA. The surgeon uses VR to grasp and interact with the 3D patient avatar. MRI, magnetic resonance image; PACS, Picture Archiving and Communication System; VR, virtual reality.



TABLE 1. Number of Evaluations for Each Modality Across the Entire Group, Practicing Surgeons, and Residents

Modality	Entire Group	Practicing Surgeon Cases	Residents Cases
Slice-based	51	24	27
DIVA	48	24	24
Radiologist report	54	27	27

NOTE. Only time measurements were performed with the radiologist report.

there was no difference between the two systems with 79.2% of correct answers with both systems (Fig 3).

Accuracy—Quadrant Determination

For quadrant determinations, we used a fused quadrants approach to compare responses of surgical residents and practicing surgeons to the definitive pathologist or radiologist report. For this outcome, 66.7% of the residents and 58.3% of the practicing surgeons were correct in their quadrant determinations with the slice-based visualization. With the DIVA system, this proportion of correct answers was 75% ($P = .49$) and 87.5% ($P = .01$) for the residents and practicing surgeons, respectively (Fig 3).

Accuracy—Surgical Strategy Determination

In determining the surgical strategy, 44.4% of residents and 66.7% of experienced surgeons chose the same surgical strategy actually applied to the patient when using

the slice-based visualization. With the DIVA system, this proportion of concordance was increased to 70.8% ($P = .03$) and 83.3% ($P = .12$), respectively, as indicated in Figure 3.

Effect of Seniority

The results describing the correlations of surgeon seniority in the measurement of the aforementioned analysis metrics are available in the Data Supplement. With increasing seniority, there was an improved analysis performance with DIVA. There was no clear correlation in improved slice-based visualization performance with seniority.

DISCUSSION

In this study, we show that the DIVA system improves the speed and accuracy of BC image analysis for surgeons, notably for residents. The immersive 3D breast and tumor representations provided by the DIVA system, moreover, have the potential to enhance the surgical approach and could greatly assist surgeons in the preparation of complicated cases.

It is important to emphasize that 3D rendering of medical images is not new. In fact, most PACS software tools contain 3D rendering or reformatting tools, although they are highly underexploited by surgeons. In an online survey, we performed on 59 French obstetrics and gynecologic surgeons, we found that 48 (81%) seldom or never use 3D volume rendering tools with existing PACS software (Data Supplement). From our accounts, this is because of a lack of training to take advantage of 3D reformat tools and a lack of interactivity in these typically static renderings.

In our survey, we found that 31% of BC surgeons are sometimes unsure about the extent of a BC lesion. Interestingly, 37% are often or sometimes unsure about the envisioned surgical strategy after reading the images. Additionally, we found that 98% of surgeons expressed an interest in using a VR-based solution to visualize patient representations (yes and maybe in Data Supplement). A likely explanation for this response is that surgeons, today, are not fully satisfied with the medical image visualization tools available to them.

A few studies have presented the use of VR in breast surgery and reconstruction¹⁷⁻¹⁹; however, none have quantitatively evaluated its usefulness for surgeons, in their daily practice. In the context of the study presented, the surgeon was asked to make a surgical decision purely on the basis of the breast MRI, which is not what happens in practice. It does, however, permit an assessment of the weight of the medical image in a surgical decision.

Relative to slice-based radiology tools, DIVA enhances the efficiency of medical image analysis for surgeons. Effectively, surgeons more accurately assess tumor localization in less time relative to the typical slice-based visualization approach. The improved accuracy is demonstrated by the increase in the proportion of correct diagnoses pertaining to

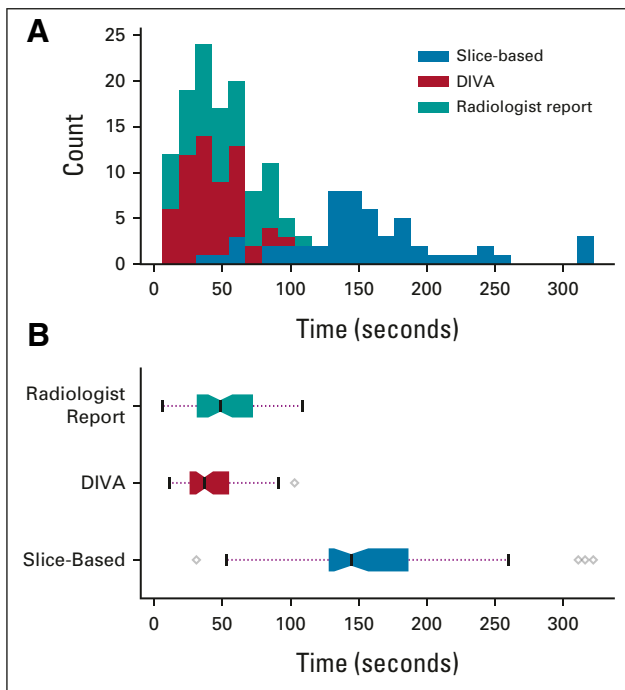


FIG 2. Analysis time for different viewing modalities for the entire group: (A) histograms of the time necessary to analyze the MRI scans in study for entire group of surgeons using the slice-based visualization and DIVA approaches (N = 52) and (B) box plots of the same data. MRI, magnetic resonance image.

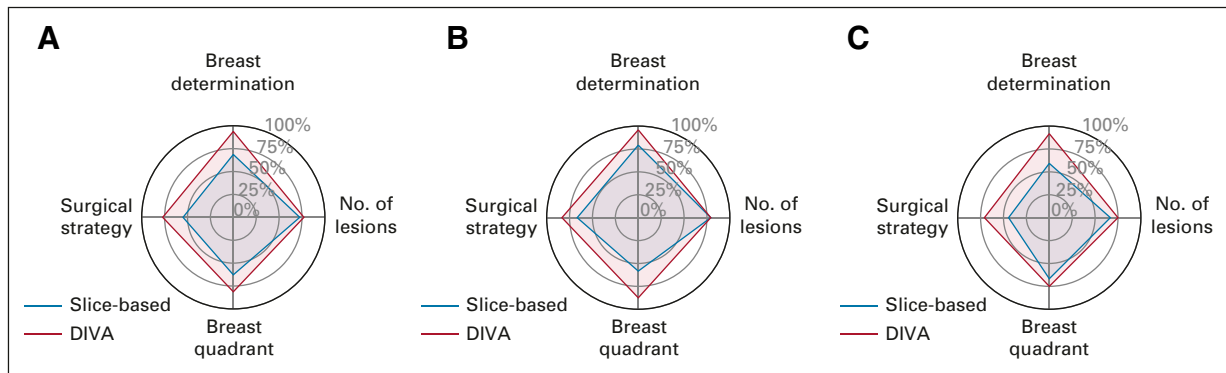


FIG 3. Spider plots of the percentage accuracy of the four metrics (breast determination, number of lesions, breast quadrant, and surgical strategy) evaluated in the MRI scan analysis for (A) the entire group, (B) the practicing surgeons, and (C) the residents.

the site, number, and quadrant location of the breast lesions relative to the initial radiologist report. The immersive 3D breast and tumor representations provided by the DIVA system significantly raised the probability of agreement and consistency among participants pertaining to the choice of the surgical strategy.

Our study measured and compared three metrics associated with tumor localization (Fig 1). DIVA outperforms the slice-based visualization for every metric. Notably, DIVA seemingly removes ambiguity in determining in which breast the tumor is located, with surgeons choosing the correct breast 94% of the time compared to 69% with the slice-based approach. This can be explained simply by the fact that 3D patient avatars in VR directly resemble patients in proportion and size. Arguably, DIVA essentially removes ambiguity in identifying in which breast the tumor is located.

Immersive stereoscopic visualization allows surgeons to immediately capture the position of the tumor by simply determining the position of the tumor relative to the contour of the breast. This task is made fairly intuitive with DIVA's lossless rendering approach that permits the tumor and breast contour to be rendered simultaneously (along with other structures such as blood vessels, pectoral muscles, and sentinel lymph nodes) without any pretreatment. By contrast, for the nonradiologist, quadrant identification is particularly challenging using purely slice-based visualizations, especially along the superior-inferior axis as breast MRI slices are typically viewed in the axial orientation.

The difference in accuracy between DIVA and the slice-based visualization approach for the number of lesions is less pronounced at 77% and 73% for the entire group, respectively. In both situations, nonspecific enhancement of the image because of gadolinium created artifacts in the visualization, which were incorrectly assessed as tumors.

Regarding the envisaged surgical strategy, the accuracy (relative to the results of the postoperative anatomical-pathologic report) increased for the entire group but most considerably for resident surgeons. This effectively implies

that the lack of experience that young surgeons have in dealing with PACS medical image visualization tools can be compensated with VR-based visualization using DIVA.

The consequences of these systematically improved metrics when using DIVA suggests an improved surgical planning whose benefits may be passed on to the patient being operated. Specifically, patients requiring a total mastectomy and those who may benefit from a conservative treatment using an oncoplastic surgical technique may be more readily identified. As an example, a recent case study we published showed how the DIVA system informed the decision to resect a multifocal lower-quadrant breast tumor.¹²

Medical benefits from the use of DIVA in preoperative planning may include a reduction in the number of total mastectomies (30.9% of patients at the Institut Curie in 2018) and reconstructions (ie, an increase in the prevalence of breast conserving surgeries), as well as a reduction in the risk of a second surgery (5.8% of patients at the Institut Curie in 2018), which is prevalent in BC operations.^{12,20} This potential reduction in second surgeries may result from VR enhancement of proper margins and proper breast quadrant localization by the surgeon, thus leading to less tumor recurrence. More broadly, the ability to better perceive the mammary gland volume, tumor volume, vascularization, and tumor location opens new opportunities and discussions regarding patient treatment plans. We additionally mention related studies from the Netherlands that measured ratios between tumor and breast volumes using 3D reconstructions of MRI images to predict cosmetic results of breast surgery²¹ and a French study that evaluated a per-operative utilization of 3D MRI reconstruction to localize nonpalpable breast lesions,²² which both yielded promising results.

For high patient volume cancer centers, the near order-of-magnitude reduction in time for surgeons to analyze the breast MRI scan with DIVA is of particular interest. The median image analysis time with DIVA was 3.92 times

faster compared with the slice-based visualization. Properly streamlined in the surgical workflow, the use of DIVA in the clinical setting may additionally address challenges associated with patient management.

The significant improvement in tumor localization metrics for resident surgeons using DIVA as compared to the slice-based visualization additionally implies a great pedagogical interest for VR in the context of surgery. In a previous study, DIVA was used in the Université de Paris Medical Faculty to teach students of craniofacial trauma surgery.⁸ In this study, 98% of students expressed a high degree of satisfaction and, importantly, an improved understanding of craniofacial trauma. The results from resident surgeons in this study strongly suggest that similar results would be attained in a BC-oriented surgical training.

Despite the exceptional experience of the BC service in which this study was conducted (3,200 patients operated in 2019), performance in reading MRI sequences with standard slice-based visualization tool suffered, likely because of a lack of formal training in radiology.³ In this regard, the VR-based visualization in DIVA can supplement the training of surgeons in a cost-effective fashion. To date, the results of this study have justified the purchase of several VR systems at the Institut Curie hospital center. In

the future, the systems will be available for use among radiotherapists, and radiologists with applications in gynecologic, ENT, head and neck, sarcoma, and liver specialties. It is also intended that further clinical evaluation and validation be pursued in the same and in different hospital centers.

Future technical developments of DIVA will promote the integration of automated analysis of tumors (eg, via object detection and segmentation tasks performed by deep-learning architectures) to provide more contextual information on tumor geometries. Furthermore, improvements and automation of the representation in VR will be investigated to increase visual quality, even for low-quality or highly complex MRI sequences.

In conclusion, this study indicates that, compared with existing slice-based visualization tools, the immersive visualization of medical images provided by DIVA universally improves surgeons' analysis of preoperative MRI scans across several different time and spatial metrics. The results that we quantified in the context of BC surgery moreover suggests that VR technology such as DIVA has the potential to broadly transform the way medical images are communicated in the clinical setting.

AFFILIATIONS

¹Decision and Bayesian Computation, USR 3756 (C3BI/DBC) and Neuroscience Department CNRS UMR 3571, Institut Pasteur and CNRS, Paris, France

²Surgery Department, Institut Curie, PSL Research University, Paris, France

³U932, Immunity and Cancer, INSERM, Institut Curie, Paris, France

⁴Department of Medical Imaging, Institut Curie, PSL Research University, Paris, France

⁵Institut Curie, INSERM, LITO Laboratory, Orsay, France

CORRESPONDING AUTHOR

Mohamed El Beheiry, PhD, Institut Pasteur, Decision and Bayesian Computation, Department of Neuroscience, 25/28 rue du Docteur Roux, 75015 Paris, France; e-mail: mohamed.el-beheiry@pasteur.fr.

EQUAL CONTRIBUTION

M.E. and T.G. contributed equally to this work. J.-B.M. and F.R. are senior authors.

AUTHOR CONTRIBUTIONS

Conception and design: Mohamed El Beheiry, Jean-Guillaume Feron, Anne Sabaila, Benoit Coutraud, Jean-Baptiste Masson, Fabien Rey, Caroline Malhaire

Provision of study materials or patients: Noémie Girard, Jean-Guillaume Feron, Virginie Fourchette, Fatima Laki, Jean-Philippe Binder, Fabien Rey

Collection and assembly of data: Mohamed El Beheiry, Noémie Girard, Lauren Darrigues, Marie Osdoit, Jean-Guillaume Feron, Enora Laas, Fatima Laki, Fabrice Lecuru, Jean-Philippe Binder, Fabien Rey, Caroline Malhaire

Data analysis and interpretation: Mohamed El Beheiry, Thomas Gaillard, Enora Laas, Virginie Fourchette, Jean-Baptiste Masson, Fabien Rey

Manuscript writing: All authors

Final approval of manuscript: All authors

Accountable for all aspects of the work: All authors

AUTHORS' DISCLOSURES OF POTENTIAL CONFLICTS OF INTEREST

The following represents disclosure information provided by authors of this manuscript. All relationships are considered compensated unless otherwise noted. Relationships are self-held unless noted. I = Immediate Family Member, Inst = My Institution. Relationships may not relate to the subject matter of this manuscript. For more information about ASCO's conflict of interest policy, please refer to www.asco.org/rwc or ascopubs.org/cci/author-center.

Open Payments is a public database containing information reported by companies about payments made to US-licensed physicians (Open Payments).

Mohamed El Beheiry

Employment: Avatar Medical

Leadership: Avatar Medical

Stock and Other Ownership Interests: Avatar Medical

Patents, Royalties, Other Intellectual Property: I have a patent pending submitted by the Institut Pasteur regarding VR technology use for surgeries. The Institut Pasteur, the Decision and Bayesian Computation laboratory, and Avatar Medical have an R&D agreement regarding development of some components of a software program on the basis of the DIVA technology. Currently, there is one PhD student working in that R&D agreement.

Travel, Accommodations, Expenses: Avatar Medical

Enora Laas

Consulting or Advisory Role: Myriad Genetics

Fabrice Lecuru

Consulting or Advisory Role: Clovis Oncology, GlaxoSmithKline, AstraZeneca

Jean-Baptiste Masson

Leadership: Avatar Medical

Stock and Other Ownership Interests: Avatar Medical

Consulting or Advisory Role: Avatar Medical

Patents, Royalties, Other Intellectual Property: I have a patent pending submitted by the Institut Pasteur (as a representative of all my institutional tutelles) regarding VR technology use for surgeries. The Institut Pasteur, the Decision and Bayesian Computation laboratory, and Avatar Medical have an R&D agreement regarding development of some component of the software. Currently, there is one PhD student working in that R&D agreement.

Fabien Reyat

Stock and Other Ownership Interests: Avatar Medical

Honoraria: Avatar Medical

No other potential conflicts of interest were reported.

ACKNOWLEDGMENT

We acknowledge the major contributions of the late Maxime Dahan in the conception and design of the reported study.

The authors acknowledge funding from the Institut Pasteur (J.-B.M.), the sponsorships of CRPCEN, Gilead Science, and foundation EDF (J.-B.M.), the ANR-17-CE23-0016 TRamWAY (J.-B.M.), the INCEPTION project (PIA/ANR-16-CONV-0005, OG) (J.-B.M.), and the programme d'investissement d'avenir supported by L'Agence Nationale de la Recherche ANR-19-P3IA-0001 Institut 3IA Prairie (J.-B.M.).

REFERENCES

1. Bray F, Ferlay J, Soerjomataram I, et al: Global cancer statistics 2018: GLOBOCAN estimates of incidence and mortality worldwide for 36 cancers in 185 countries. *CA Cancer J Clin* 68:394-424, 2018
2. Institut National du Cancer: Cancer du sein infiltrant non métastatique—Questions d'actualités—Rapport intégral. Institut National du Cancer, 2012. <https://www.e-cancer.fr/Expertises-et-publications/Catalogue-des-publications/Cancer-du-sein-infiltrant-non-metastatique-questions-d-actualites-rapport-integral>
3. Butler KL, Chang Y, DeMoya M, et al: Needs assessment for a focused radiology curriculum in surgical residency: A multicenter study. *Am J Surg* 211:279-287, 2016
4. Sadeghi AH, Taverne YJ, Bogers AJ, et al: Immersive virtual reality surgical planning of minimally invasive coronary artery bypass for Kawasaki disease. *Eur Heart J* 41:3279, 2020
5. Cao C, Cerfolio RJ: Virtual or augmented reality to enhance surgical education and surgical planning. *Thorac Surg Clin* 29:329-337, 2019
6. Zawy SA, Sakellaropoulou I, Stroop R: Evaluation of surgical approaches for tumor resection in the deep infratentorial region and impact of virtual reality technique for the surgical planning and strategy. *J Craniofac Surg* 31:1865-1869, 2020
7. El Beheiry M, Doutreligne S, Caporal C, et al: Virtual reality: Beyond visualization. *J Mol Biol* 431:1315-1321, 2019
8. Bouaoud J, El Beheiry M, Jablon E, et al: DIVA, a 3D virtual reality platform, improves undergraduate craniofacial trauma education. *J Stomatol Oral Maxillofac Surg* 122:367-371, 2021
9. El Beheiry M, Godard C, Caporal C, et al: DIVA: Natural navigation inside 3D images using virtual reality. *J Mol Biol* 432:4745-4749, 2020
10. Le Point: Palmarès des hôpitaux et cliniques 2020 du Point. Paris, France, Le Point, 2020
11. Morris E, Comstock C, Lee C, et al: ACR BI-RADS® Atlas, Breast Imaging Reporting and Data System. Reston, VA, American College of Radiology, 2013
12. Laas E, El Beheiry M, Masson JB, et al: Partial breast resection for multifocal lower quadrant breast tumor using virtual reality. *BMJ Case Rep* 14:e241608, 2021
13. Raimondi F, Vida V, Godard C, et al: Fast-track VR for cardiac imaging in congenital heart disease. *J Card Surg* 36:2598-2602, 2021
14. Engel K, Hadwiger M, Kniss J, et al: Real-Time Volume Graphics (ed 1). Boca Raton, FL, A K Peters/CRC Press, 2006
15. Virtanen P, Gommers R, Oliphant TE, et al: SciPy 1.0: Fundamental algorithms for scientific computing in Python. *Nat Methods* 17:261-272, 2020
16. Pedregosa F, Varoquaux G, Gramfort A, et al: Scikit-learn: Machine learning in Python. *J Machine Learn Res* 12:2825-2830, 2011
17. Gómez-Cía T, Gacto-Sánchez P, Sicilia D, et al: The virtual reality tool VirSSPA in planning DIEP microsurgical breast reconstruction. *Int J Comput Assist Radiol Surg* 4:375-382, 2009
18. Rancati A, Angrigiani C, Nava MB, et al: Augmented reality for breast imaging. *Minerva Chir* 73:341-344, 2018
19. Tomikawa M, Hong J, Shiotani S, et al: Real-time 3-dimensional virtual reality navigation system with open MRI for breast-conserving surgery. *J Am Coll Surg* 210:927-933, 2010
20. Calleoni M, Sun Z, Price KN, et al: Annual hazard rates of recurrence for breast cancer during 24 years of follow-up: Results from the International Breast Cancer Study Group Trials I to V. *J Clin Oncol* 34:927-936, 2016
21. Vos EL, Koning AH, Obdeijn IM, et al: Preoperative prediction of cosmetic results in breast conserving surgery: Predicting cosmetic result. *J Surg Oncol* 111:178-184, 2014
22. Duraes M, Crochet P, Pagès E, et al: Surgery of nonpalpable breast cancer: First step to a virtual per-operative localization? First step to virtual breast cancer localization. *Breast J* 25:874-879, 2019