



HAL
open science

Imported haemorrhagic fever with renal syndrome caused by Dobrava–Belgrade hantavirus in France

Meghann Antoine, Marie Elodie Langlois, Emilie Bres, Maud Rabeyrin,
Jean-Marc Reynes, Abbas Deeb

► **To cite this version:**

Meghann Antoine, Marie Elodie Langlois, Emilie Bres, Maud Rabeyrin, Jean-Marc Reynes, et al..
Imported haemorrhagic fever with renal syndrome caused by Dobrava–Belgrade hantavirus in France.
Clinical Kidney Journal, 2021, 14 (3), pp.1014-1016. 10.1093/ckj/sfaa006 . pasteur-03681843

HAL Id: pasteur-03681843

<https://pasteur.hal.science/pasteur-03681843v1>

Submitted on 30 May 2022

HAL is a multi-disciplinary open access archive for the deposit and dissemination of scientific research documents, whether they are published or not. The documents may come from teaching and research institutions in France or abroad, or from public or private research centers.

L'archive ouverte pluridisciplinaire **HAL**, est destinée au dépôt et à la diffusion de documents scientifiques de niveau recherche, publiés ou non, émanant des établissements d'enseignement et de recherche français ou étrangers, des laboratoires publics ou privés.



Distributed under a Creative Commons Attribution - NonCommercial 4.0 International License



EXCEPTIONAL CASE

Imported haemorrhagic fever with renal syndrome caused by Dobrava–Belgrade hantavirus in France

Meghann Antoine¹, Marie Elodie Langlois¹, Emilie Bres², Maud Rabeyrin³, Jean-Marc Reynes⁴ and Abbas Deeb²

¹Department of Internal Medicine, Centre Hospitalier Lyon Sud, Hospices Civils de Lyon, Université de Lyon, Lyon, France, ²Department of Nephrology, Centre Hospitalier Lyon Sud, Hospices Civils de Lyon, Université de Lyon, Lyon, France, ³Department of Cytology and Pathology, Hôpital Cardiologique, Hospices Civils de Lyon, Université de Lyon, Lyon, France and ⁴Hantavirus National Reference Center, Unité Environnement et Risques Infectieux, Institut Pasteur, Paris, France

Correspondence to: Abbas Deeb; E-mail: abbassdeeb78@yahoo.com

ABSTRACT

Acute kidney injury (AKI) caused by hantavirus infections is rare but should be suspected in any patient presenting with flu-like symptoms, signs of haemolytic-uraemic syndrome or presence of anti-glomerular basement membrane (anti-GBM) antibodies. We report the first case of Dobrava–Belgrade virus in France imported from southeastern Europe. The characteristic macroscopic appearance of the fresh renal biopsy specimen, displaying a haemorrhagic appearance of the medulla, suggested hantavirus infection. AKI caused by hantavirus infections remains a diagnostic challenge, especially outside endemic areas.

Keywords: acute kidney injury, Dobrava–Belgrade *Orthohantavirus*, France, hantavirus infection, haemorrhagic interstitial nephritis, renal biopsy

BACKGROUND

Hantavirus disease is a relatively rare cause of life-threatening disease with acute renal injury, also known as nephropathia epidemica. It is a zoonotic infection caused by viruses belonging to the genus *Orthohantavirus* of the family Hantaviridae. Three zoonotic hantavirus species have been reported in France: the Puumala, Seoul and Tula viruses. An average of 100 human cases are detected per year, mostly associated with Puumala virus, and generally in the northeast part of France (endemic area). Here we report a patient presenting an acute kidney injury (AKI) caused by Dobrava–Belgrade virus (DOBV) outside the French hantavirus endemic area.

CASE REPORT

A 48-year-old male plumber with a history of hypertension presented in Lyon hospital 3 days after the day of onset (Day 4) with a fever at 39°C associated with abdominal discomfort. He did not smoke tobacco or drink alcohol. Examination found no obvious cause for the fever. The biological assessment showed a hepatic cytolysis without cholestasis. No inflammatory syndrome was noticed while a persistent thrombocytopenia was observed. The evolution was marked by AKI, serum creatinine rising from 50 to 680 µmol/L, major proteinuria (16 g/24 h), significant haematuria and leucocyturia. The patient developed headache and skin rash. Interestingly, a percutaneous renal

Received: 10.12.2019; Editorial decision: 7.1.2020

© The Author(s) 2020. Published by Oxford University Press on behalf of ERA-EDTA.

This is an Open Access article distributed under the terms of the Creative Commons Attribution Non-Commercial License (<http://creativecommons.org/licenses/by-nc/4.0/>), which permits non-commercial re-use, distribution, and reproduction in any medium, provided the original work is properly cited. For commercial re-use, please contact journals.permissions@oup.com



FIGURE 1: The macroscopic haemorrhagic appearance of the medulla on the renal biopsy.

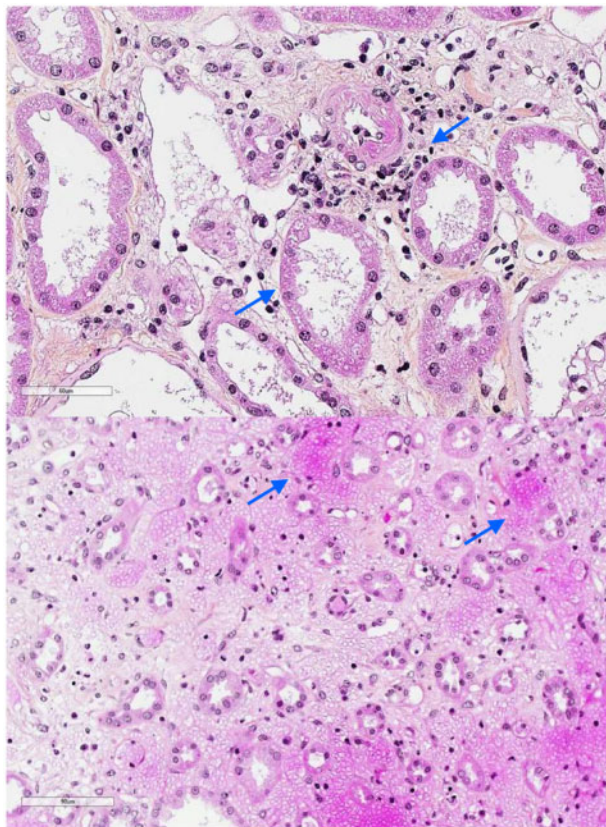


FIGURE 2: Tubular necrosis changes in association with interstitial oedema (arrows), mild inflammation and cortical peritubular capillaritis (top; hematoxylin and eosin saffron stain, $\times 400$). Diffuse medullary interstitial haemorrhage (arrows) (bottom; hematoxylin and eosin saffron stain, $\times 200$).

biopsy exhibited a macroscopically haemorrhagic medulla, suggesting a possible hantavirus infection (Figure 1). Histology showed acute haemorrhagic interstitial nephritis (Figure 2) characterized by an extensive interstitial haemorrhage of the outer medulla with massive extrusion of erythrocytes and inflammatory cells and focal tubular dilation. Discrete damage to tubules and peritubular capillaries was occasionally observed.

An initial oliguric phase was followed by polyuria 5 days later. The evolution was rapidly favourable without the need for dialysis.

Laboratory results diagnostic of hantavirus infection were achieved using molecular assay. The result of a nested reverse transcriptase polymerase chain reaction (RT-PCR) assay, targeting the partial L segment of hantaviruses performed retrospectively in a blood sample from Day 9 was positive. The sequence obtained (GenBank accession no. MN854701) from the amplified product was similar to the sequences of DOBV strains belonging to the Kurkino genotype found in central and southeastern Europe according to the results of a Blast search (<https://blast.ncbi.nlm.nih.gov/Blast.cgi>) and a phylogenetic analysis (see Supplementary data, Figures S1 and S2).

As a plumber living in the area of Lyon, outside the French hantavirus endemic area, he repaired waste water pipes in a Lyon suburb 1 week before Day 1. Interestingly, he spent 1 month in Greece, Macedonia and Bulgaria in southeastern Europe, visiting rural places, and returned to France 4 weeks before Day 1, suggesting an importation of the virus.

DISCUSSION

To the authors' best knowledge, this is the first reported human case of DOBV in France. DOBV is the most life-threatening European hantavirus, with a case fatality rate of up to 12%. The field mouse species *Apodemus ponticus*, *Apodemus agrarius* and *Apodemus flavicollis* are natural hosts of the virus. They are distributed in central and southeastern Europe and Russia [1]. This case is considered as an imported haemorrhagic fever because the Kurkino strain detected in the patient is mainly associated with *A. agrarius*, which is absent in France. These genotype and rodent species are found in southeastern Europe, where the patient spent his holidays. *A. flavicollis*, associated with the Dobrava genotype, is the only host species present in France, in the eastern part of the country, but has never been found to be infected [2].

Hantaviruses can cause haemorrhagic fever with renal syndrome (HFRS). The most prominent pathological presentation is an acute tubulointerstitial nephritis following the infiltration of inflammatory cells (Figure 2). Medullary haemorrhages are found in 20–60% of biopsies during the acute phase. This shows the link between renal damage and haemorrhagic manifestations [3, 4]. Kidney histology relates to the severity of acute kidney failure but not the magnitude of proteinuria, which is typically high.

The exact pathogenic mechanisms are not yet fully understood. Hantaviruses infect and replicate in the vascular endothelium and dendritic cells (DCs) but do not seem to cause direct cytopathic effects. HFRS is mediated largely by the innate and adaptive immune systems. Hantavirus-infected migrating DCs play a fundamental role in the dissemination of hantavirus to regional lymph nodes. These cells allow virus replication, which induces a powerful immune activation, especially by macrophages and cytotoxic CD8 T lymphocytes.

Pro-inflammatory cytokines produced by an antiviral innate immune response, such as interleukin (IL-6, IL-10), tumour necrosis factor- α and interferon- γ , may contribute to increased endothelial cell permeability due to dysregulation of the endothelial cell barrier rather than by direct cellular cytotoxicity. Increased glomerular permeability may lead to massive proteinuria [5]. Also, a genetic predisposition related to human leucocyte antigen type seems to be important for the severity of the disease, but different hantaviruses are associated with

different HLA haplotypes. HLA-B*35 is more common in severe disease progression in patients infected with DOBV, especially in fatal cases [5]. Treatment is symptomatic and may require haemodialysis. There is no specific antiviral chemotherapy available.

In conclusion, the diagnosis of hantavirus infections is based on clinical and epidemiological information and is routinely confirmed by blood tests. The macroscopic haemorrhagic appearance of the renal biopsy was key to suggest the diagnosis in the present case report from a region outside a hantavirus endemic area.

PATIENT CONSENT

The patient gave informed consent for the publication of this case.

SUPPLEMENTARY DATA

[Supplementary data](#) are available at [ckj](#) online.

ACKNOWLEDGEMENTS

The authors would like to thank Denis Fouque, MD, PhD, Nephrology Department, CHU Lyon Sud, for his help in writing the manuscript, Maryline Ripaux-Lefèvre from the

Hantavirus National Reference Center and Valérie Caro from the Environnement et Risques infectieux unit, Institut Pasteur, Paris, France for technical assistance. We also thank our patient for allowing this publication as a case report.

CONFLICT OF INTEREST STATEMENT

None declared. The results presented in this article have not been published previously in whole or part, except in abstract format.

REFERENCES

1. Klempa B, Avsic-Zupanc T, Clement J et al. Complex evolution and epidemiology of Dobrava-Belgrade hantavirus: definition of genotypes and their characteristics. *Arch Virol* 2013; 158: 521–529
2. Reynes JM, Carli D, Renaudin B et al. Surveillance des infections humaines par hantavirus en France métropolitaine, 2012–2016. *Bull Épidémiol Hebd* 2017; 23: 492–499
3. Tomlinson J. Diagnostic Atlas of Renal Pathology. *Pathology (Phila)* 2006; 38: 193
4. Ferluga D, Vizjak A. Hantavirus nephropathy. *J Am Soc Nephrol* 2008; 19: 1653–1658
5. Jiang H, Du H, Wang LM et al. Hemorrhagic fever with renal syndrome: pathogenesis and clinical picture. *Front Cell Infect Microbiol* 2016; 6: 1