



HAL
open science

Rubella Virus-Associated Cutaneous Granulomatous Disease: a Unique Complication in Immune-Deficient Patients, Not Limited to DNA Repair Disorders

David Buchbinder, Fabian Hauck, Michael Albert, Anita Rack, Shahrzad Bakhtiar, Anna Shcherbina, Elena Deripapa, Kathleen Sullivan, Ludmila Perelygina, Marc Eloit, et al.

► **To cite this version:**

David Buchbinder, Fabian Hauck, Michael Albert, Anita Rack, Shahrzad Bakhtiar, et al.. Rubella Virus-Associated Cutaneous Granulomatous Disease: a Unique Complication in Immune-Deficient Patients, Not Limited to DNA Repair Disorders. *Journal of Clinical Immunology*, 2019, 39 (1), pp.81-89. 10.1007/s10875-018-0581-0 . pasteur-03469013

HAL Id: pasteur-03469013

<https://pasteur.hal.science/pasteur-03469013v1>

Submitted on 11 Sep 2024

HAL is a multi-disciplinary open access archive for the deposit and dissemination of scientific research documents, whether they are published or not. The documents may come from teaching and research institutions in France or abroad, or from public or private research centers.

L'archive ouverte pluridisciplinaire **HAL**, est destinée au dépôt et à la diffusion de documents scientifiques de niveau recherche, publiés ou non, émanant des établissements d'enseignement et de recherche français ou étrangers, des laboratoires publics ou privés.



Distributed under a Creative Commons Attribution - NonCommercial 4.0 International License



Published in final edited form as:

J Clin Immunol. 2019 January ; 39(1): 81–89. doi:10.1007/s10875-018-0581-0.

Rubella Virus-Associated Cutaneous Granulomatous Disease: a Unique Complication in Immune-Deficient Patients, Not Limited to DNA Repair Disorders

David Buchbinder^{1,2}, Fabian Hauck³, Michael H. Albert³, Anita Rack³, Shahrzad Bakhtiar⁴, Anna Shcherbina⁵, Elena Deripapa⁵, Kathleen E. Sullivan⁶, Ludmila Perelygina⁷, Marc Eloit⁸, Bénédicte Neven^{9,10}, Philippe Pérot^{8,11}, Despina Moshous^{9,10}, Felipe Suarez¹², Christine Bodemer¹³, Francisco A. Bonilla¹⁴, Louise E. Vaz¹⁵, Alfons L. Krol¹⁶, Christoph Klein³, Mikko Seppanen¹⁷, Diane J. Nugent^{1,2}, Jasjit Singh^{2,18}, Hans D. Ochs¹⁹

¹Department of Pediatric Hematology, Children's Hospital of Orange County, 1201 W. La Veta Avenue, Orange, CA 92868, USA ²Department of Pediatrics, University of California at Irvine, Orange, CA, USA ³Department of Pediatrics, Dr. von Hauner Children's Hospital, University Hospital, LMU, Munich, Germany ⁴Division for Pediatric Stem Cell Transplantation and Immunology, University Hospital Frankfurt, Frankfurt/Main, Germany ⁵Department of Immunology, Dmitry Rogachev National Medical Research Center for Pediatric Hematology, Oncology and Immunology, Moscow, Russia ⁶Division of Allergy Immunology, The Children's Hospital of Philadelphia, Philadelphia, PA, USA ⁷Division of Viral Diseases, Centers for Disease Control and Prevention, Atlanta, GA, USA ⁸Biology of Infection Unit, Pathogen Discovery Laboratory, Institut Pasteur, Paris, France ⁹Unité d'Immunologie-Hématologie et Rhumatologie Pédiatriques, Hôpital Necker-Enfants-Malades, AP-HP, Paris, France ¹⁰INSERM U116 and Institut Imagine, Université Paris-Descartes, Sorbonne Paris Cité, Paris, France ¹¹Centre d'innovation et de Recherche Technologique (Citech), Institut Pasteur, Paris, France ¹²Unité d'hématologie adulte, Hopital

David Buchbinder dbuchbinder@choc.org.

Authorship Contributions All the authors helped draft and approved the submitted manuscript. HDO, DB, and FH coordinated the collection of the data and creation of the manuscript. All the authors diagnosed and treated the various immune disorders. HDO, DB, and FH reviewed the literature and illustrated the manuscript. LP provided laboratory support for the diagnosis of rubella virus and associated analyses. HDO, DB, and FH made possible this multi-institutional investigation.

David Buchbinder and Fabian Hauck contributed equally to this work.

Compliance with Ethical Standards

Conflicts of Interest The authors declare that they have no conflict of interest.

Disclaimer The findings and conclusions in this report are those of the authors and do not necessarily represent the official position of the Centers for Disease Control and Prevention, US Department of Health and Human Services.

Ethics Statements 1. CDC, VVPDB personnel were not involved in any clinical decisions regarding these patients. All decisions were made by physicians treating these cases. Patient blood samples and biopsy material were obtained by physicians after provision of informed consent. CDC's direct role involving the patients was only laboratory testing of specimens.

2. Archived FFPE specimens from patients with granuloma were tested with non-disclosure of patient information, which was determined to be ethically acceptable by the Internal Review Board at the CDC. This work was determined to be non-applicable for human subject regulations (ID number 2014 6417).

3. In addition, RV RT-PCR detection and sequencing analysis in the biopsy material for possible rubella virus in these tissue specimens was done for the purpose of possible public health response as a part of ongoing CDC surveillance for rubella virus. Note that rubella virus-positive granulomas have been shown to shed divergent infectious rubella virus, which is the public health concern. In addition, CDC, VVPDB, rubella team personnel have international public health responsibilities as part of the CDC Global Specialized Laboratory in the WHO Measles and Rubella Laboratory Network.

Publisher's Note Springer Nature remains neutral with regard to jurisdictional claims in published maps and institutional affiliations.

Necker-Enfants-Malades, AP-HP, INSERM U116 & Institut Imagine, Université Paris-Descartes, Sorbonne Paris Cité, Paris, France ¹³Service de dermatologie pédiatrique, Hopital Necker-Enfants- Malades, AP-HP, INSERM U116 & Institut Imagine, Université Paris-Descartes, Sorbonne Paris Cité, Paris, France ¹⁴Boston Children's Hospital, Boston, MA, USA ¹⁵Department of Infectious Disease, Doernbecher Children's Hospital, Oregon Health Sciences University, Portland, OR, USA ¹⁶Department of Dermatology, Doernbecher Children's Hospital, Oregon Health Sciences University, Portland, OR, USA ¹⁷Rare Disease Center, Children's Hospital, Helsinki University Central Hospital, Helsinki, Finland ¹⁸Department of Infectious Disease, Children's Hospital of Orange County, Orange, CA, USA ¹⁹Center for Immunity and Immunotherapies, Seattle Children's Research Institute, Department of Pediatrics, University of Washington, Seattle, WA, USA

Abstract

The association of immunodeficiency-related vaccine-derived rubella virus (iVDRV) with cutaneous and visceral granulomatous disease has been reported in patients with primary immunodeficiency disorders (PIDs). The majority of these PID patients with rubella-positive granulomas had DNA repair disorders. To support this line of inquiry, we provide additional descriptive data on seven previously reported patients with Nijmegen breakage syndrome (NBS) ($n = 3$) and ataxia telangiectasia (AT) ($n = 4$) as well as eight previously unreported patients with iVDRV-induced cutaneous granulomas and DNA repair disorders including NBS ($n = 1$), AT ($n = 5$), DNA ligase 4 deficiency ($n = 1$), and Artemis deficiency ($n = 1$). We also provide descriptive data on several previously unreported PID patients with iVDRV-induced cutaneous granulomas including cartilage hair hypoplasia ($n = 1$), warts, hypogammaglobulinemia, immunodeficiency, myelokathexis (WHIM) syndrome ($n = 1$), MHC class II deficiency ($n = 1$), Coronin-1A deficiency ($n = 1$), X-linked severe combined immunodeficiency (X-SCID) ($n = 1$), and combined immunodeficiency without a molecular diagnosis ($n = 1$). At the time of this report, the median age of the patients with skin granulomas and DNA repair disorders was 9 years (range 3–18). Cutaneous granulomas have been documented in all, while visceral granulomas were observed in six cases (40%). All patients had received rubella virus vaccine. The median duration of time elapsed from vaccination to the development of cutaneous granulomas was 48 months (range 2–152). Hematopoietic cell transplantation was reported to result in scarring resolution of cutaneous granulomas in two patients with NBS, one patient with AT, one patient with Artemis deficiency, one patient with DNA Ligase 4 deficiency, one patient with MHC class II deficiency, and one patient with combined immunodeficiency without a known molecular etiology. Of the previously reported and unreported cases, the majority share the diagnosis of a DNA repair disorder. Analysis of additional patients with this complication may clarify determinants of rubella pathogenesis, identify specific immune defects resulting in chronic infection, and may lead to defect-specific therapies.

Keywords

DNA ligase 4 deficiency; ataxia telangiectasia; Nijmegen breakage syndrome; Artemis deficiency; combined immunodeficiency; chronic rubella infection resulting in cutaneous granuloma formation

Introduction

The long-term presence of immunodeficiency-related vaccine-derived rubella virus (iVDRV) in association with cutaneous and sometimes visceral granuloma formation was recently identified using deep sequencing of lesions [1] and then extended by rubella-targeted testing in a total of 19 patients with various primary immunodeficiency disorders (PIDs) [1–4]. Based on the clinical and laboratory features, it has been hypothesized that underlying immunodeficiency allowed for persistence of the attenuated rubella virus vaccine strain. Polarization of the macrophages to a M2 phenotype appears to be associated with an inability to clear the virus [2]. Aberrant cytotoxic CD8+ T cell responses also appear to be important in the persistence of rubella virus in association with cutaneous granuloma formation [2]. Interestingly, the majority of PID patients with rubella-positive granulomas had DNA repair disorders such as ataxia telangiectasia (AT) ($n = 9$), Nijmegen breakage syndrome (NBS) ($n = 3$), or V(D)J recombination defects such as RAG1 ($n = 1$) and RAG2 ($n = 1$) deficiency [1–4].

DNA repair disorders encompass a spectrum of PIDs including AT, NBS, XRCC4-like factor (XLF)/Cernunnos, Bloom's syndrome (BS), DNA ligase 4 deficiency, and Artemis deficiency. The importance of DNA repair by homologous recombination, non-homologous end joining (NHEJ), and cell cycle checkpoint control is underscored by its crucial role in the development of the adaptive immune system. Processes involving NHEJ such as V(D)J recombination and associated development of T and B cell receptor diversity is one such example. It is unknown, however, how DNA repair disorders are permissive for the salient features that have been hypothesized to permit the development of iVDRV infection often presenting as chronic cutaneous granulomas (see Fig. 1). The potential impact of DNA repair disorders on cytotoxic CD8+ T cell responses and macrophage polarity are intriguing areas that warrant more detailed evaluation.

Methods

To support the importance of this line of inquiry, we provide additional information on previously reported patients (three patients with NBS and four patients with AT) and iVDRV-associated cutaneous granulomatous disease as well as eight not yet reported patients with DNA repair disorders and iVDRV-associated cutaneous granulomatous disease (one patient with NBS, five patients with AT, one patient with DNA ligase 4 deficiency, and one patient with Artemis deficiency). To our knowledge, the latter two disorders have not yet been associated with this complication. We are also including six not yet reported patients with other combined immunodeficiencies and iVDRV cutaneous granuloma formation (one patient each with cartilage hair hypoplasia (CHH), warts, hypogammaglobulinemia, immunodeficiency, myelokathexis (WHIM) syndrome, MHC class II deficiency, Coronin-1A deficiency, X-linked severe combined immunodeficiency (X-SCID), and combined immunodeficiency without a known molecular cause).

Patients with a PID diagnosis with cutaneous granulomas that were rubella virus-positive were identified through the Clinical Immunology Society Listserv which is a tool utilized by

the physician and scientist members of this professional society to enhance collaboration and exchange information focused on PID patients. The authors also identified relevant cases following a literature search or personal communication. Physicians were individually contacted. A structured datasheet was utilized to collect clinical information from treating physicians.

Results

Table 1 provides a description of the clinical and immunological characteristics of iVDRV-associated cutaneous granulomatous disease patients with DNA repair disorders ($n=15$) and other PIDs ($n=6$).

Demographic Features

The median age at the time of report of the patients with DNA repair disorders ($n=15$) was 9 years (range 3–18). The majority were females (73%). For patients with other PIDs ($n=6$), the median age at the time of report was 17 years (range 3–33). The majority were also females (67%).

Clinical and Immunologic Features

Cutaneous granuloma formation has been documented in all 15 DNA repair disorder cases while visceral granuloma formation impacting the spleen, liver, bone, and lungs were observed in six cases (40%). The severity of the cutaneous granulomas was variable including superficial lesions as well as deep ulcerating lesions and destruction of soft tissues (Fig. 1). Among patients with other PIDs, only cutaneous granuloma formation has been documented. T cell and B cell lymphopenia as well as hypogammaglobulinemia or impaired antibody formation was present in the majority of patients with DNA repair disorders consistent with a combined immunodeficiency phenotype. Four AT patients demonstrated a hyper IgM phenotype. Moreover, T cell and B cell lymphopenia was also present in the majority of patients with other PIDs. Among DNA repair disorder patients and other PIDs, the median age at onset of cutaneous granuloma formation was 54 months (range 14–168) and 151 months (range 22–324), respectively. The median duration of time elapsed from vaccination to the development of cutaneous granuloma formation in these two groups was 48 months (range 2–152) and 102 months (range 13–135), respectively. Two patients with DNA repair disorders developed cutaneous granulomas following chemotherapy for lymphoma (both AT patients). The presence of rubella was confirmed in all skin and visceral granulomas. The diagnosis of rubella was made by PCR (47%) or immunohistochemistry (53%) in patients with DNA repair disorders. For patients with other PIDs, the diagnosis of rubella was made by PCR in the majority of cases (83%).

Treatments and Outcomes

Among DNA repair disorder patients, treatments included topical corticosteroids (53%), hematopoietic stem cell transplantation (33%), and nitazoxanide (27%). Similarly, among patients with other PIDs, treatments included topical ($n=1$) and systemic corticosteroids ($n=1$) or both ($n=1$). One patient demonstrated clinical improvement following anti-tumor necrosis factor therapy. Hematopoietic stem cell transplantation was reported to result in

scarring resolution of granulomata including two patients with NBS, one patient with AT, one patient with Artemis deficiency, one patient with DNA Ligase 4 deficiency, one patient with MHC class II deficiency, and one patient with combined immunodeficiency without a known molecular cause [4]. Rubella-associated complications did not contribute to death among those patients who died (40%).

Discussion

The majority of the previously reported (14 of 19) and not yet reported (8 of 14) cases listed here share the clinical diagnosis of a DNA repair disorder and the presence of rubella virus, strongly suggesting the association between iVDRV and cutaneous granuloma formation. The addition of patients with DNA ligase 4 and Artemis deficiency to the existing literature of PIDs (i.e., AT, NBS, RAG1/RAG2 deficiency) with cutaneous granuloma formation in association with chronic rubella virus infection [1–4] suggests that aberrations in the genes involved in DNA repair result in a specific deficient immune response that places these patients at risk for the development of this complication. However, the presence of iVDRV-associated granulomatous disease in other PIDs may indicate a general predisposition of patients with combined immunodeficiencies who are not severe enough to be diagnosed before the initiation of live viral vaccines.

Common to all of these patients is the presence of a significant T cell deficiency. For many, there is also a concomitant antibody deficiency. Although not much is known about rubella virus-specific T cell responses, we hypothesize that adequate rubella virus-specific T cell responses are vital to the control of rubella virus. Likely common to many of these patients is the presence of rubella virus-specific antibodies. Since many of these patients were recipients of immunoglobulin prophylaxis with concomitant levels of rubella virus-specific antibodies reflective of the immunoglobulin donor pool, it appears that rubella virus-specific antibody is not able to eliminate persistent infection. Moreover, no cases of rubella virus-associated granulomas have been described in patients with agammaglobulinemia, and intravenous immunoglobulin does not appear to be an effective treatment of cutaneous granulomas.

Although a prominent T cell deficiency and concomitant antibody deficiency are common to the majority of these patients, the significant variability that exists even among specific diagnoses supports the importance of these aforementioned immunological lacunae in the pathogenesis of iVDRV-associated cutaneous granulomatous disease. For example, among patients with AT, there is a wide spectrum of symptoms, but granulomatous disease is not a frequent clinical finding. Moreover, the vast majority of the AT patients represented here have documented clinical and laboratory evidence of significant and profound immunodeficiency and immune dysregulation. This includes end organ autoimmunity and lymphoproliferation as well as interesting features such as abnormal isotype switching resulting in a hyper IgM phenotype and lack of anti-rubella IgG antibody formation [5]. Additional data focusing on detailed immunological evaluation among unbiased cohorts of patients (e.g., AT patients) without iVDRV-associated granulomatous disease would be a useful comparison.

The period of latency between vaccination and the evolution of iVDRV-associated cutaneous granulomatous disease was wide. Notably, the period of latency was shorter among patients with DNA repair disorders when compared with patients suffering from other PIDs. We hypothesize that the immunologic status of the patient plays an important role in shaping this period of latency. For example, diminution of CD8+ T cell cytotoxicity or the T cell repertoire over time may be forces favoring the persistence of vaccine-associated rubella virus and the subsequent development of cutaneous granulomatous disease. The presence of additional host factors (e.g., the receipt of cytotoxic chemotherapeutic agents in some of the reported patients), environmental factors, and pathogen-specific factors (e.g., viral escape mechanisms to include the accumulation of mutations by the virus) may also influence the risk for the development of this complication and the timing of its development in individual patients.

We acknowledge the limitations imposed by our study design and the possibility that there may be a selection bias such that patients with DNA repair disorders and cutaneous granuloma formation may be over-represented. We can only speculate as to the risk for iVDRV-associated cutaneous granuloma formation in DNA repair disorders and other combined immunodeficiencies. We acknowledge that no exact evidence exists that proves that rubella virus causes cutaneous granulomatous disease. It is clear, however, that rubella virus can be demonstrated in granulomas of patients with PIDs including patients with DNA repair disorders. For these PID patients, vaccination exposure preceded the development of cutaneous granulomatous disease. Indeed, there is a body of literature describing the presence of cutaneous granulomatous disease of unknown etiology in the context of disorders such as Artemis, DNA-dependent protein kinase (DNA-PK), and RAG deficiencies [1, 6, 7]. Careful evaluation of these cases for the presence of chronic rubella virus infection may be a productive clinical exploration. Moreover, confirmation of the presence of rubella virus strain RA27/3 is necessary. Many of these analyses can be achieved through the application of immunohistochemical staining and more sensitive techniques including RT-PCR. Analysis on fresh tissue is desirable as extraction of intact RNA from formalin-fixed paraffin-embedded is limited.

This relatively common association underscores the risk of live viral vaccination in patients with these disorders. If the diagnosis of a primary immunodeficiency disorder is known at the time of vaccination (e.g., AT), rubella virus vaccine should only be given in full awareness of this potential complication. Moreover, the presence of chronic granulomatous lesions should prompt aggressive pathogen identification to include rubella virus. Consideration should be given to use of curative treatment with hematopoietic stem cell transplantation using modified reduced intensity conditioning in selected patients with DNA repair disorders [8]. Other areas of active exploration include the use of agents such as nitazoxanide that may possess broad antiviral properties [9]. Interestingly, the responses reported post-conditioning among several of the NBS patients, one AT patient, one DNA ligase 4-deficient patient, and one Artemis-deficient patient suggests that the elimination of rubella virus-specific (functionally impaired) effector T cells may have resulted in the disappearance of the cutaneous granulomatous disease. We anticipate that the rubella virus itself remains; however, the engrafted donor immune system is then able to control the rubella virus as would be anticipated in the normal host.

Additional basic and clinical research analyses of confirmed patients with DNA repair disorders and other PIDs with iVDRV as well as cutaneous and visceral granuloma formation are planned. A focus of these analyses will include the evaluation of the cellular and humoral immune response to rubella vaccination. These efforts will help clarify those determinants that influence rubella pathogenesis, as new patients continue to be identified retrospectively and prospectively.

Acknowledgements

We thank the patients and their families for participating in our research studies. We would also like to acknowledge the support of the U.S. Centers for Disease Control and Prevention in Atlanta, GA. Patient blood samples and biopsy material were obtained after provision of informed consent.

References

1. Bodemer C, Sauvage V, Mahlaoui N, Cheval J, Couderc T, Leclerc-Mercier S, et al. Live rubella virus vaccine long-term persistence as an antigenic trigger of cutaneous granulomas in patients with primary immunodeficiency *Clin Microbiol Infect*. 2014;20(10):0656–63.
2. Perelygina L, Plotkin S, Russo P, et al. Rubella persistence in epidermal keratinocytes and granuloma M2 macrophages in patients with primary immunodeficiencies. *J Allergy Clin Immunol*. 2016;138(5): 1436–1439.e11.
3. Neven B, Pérot P, Bruneau J, Pasquet M, Ramirez M, Diana JS, et al. Cutaneous and visceral chronic granulomatous disease triggered by a rubella virus vaccine strain in children with primary immunodeficiencies. *Clin Infect Dis*. 2017;64(1):83–6. [PubMed: 27810866]
4. Deripapa E, Balashov D, Rodina Y, Laberko A, Myakova N, Davydova NV, et al. Prospective study of a cohort of Russian Nijmegen breakage syndrome patients demonstrating predictive value of low kappa-deleting recombination excision circle (KREC) numbers and beneficial effect of hematopoietic stem cell transplantation (HSCT). *Front Immunol*. 2017;8:807. [PubMed: 28791007]
5. Noordzij JG, Wulffraat NM, Haraldsson A, Meyts I, Veer LJ, Hogervorst FBL, et al. Ataxia-telangiectasia patients presenting with hyper-IgM syndrome. *Arch Dis Child*. 2009;94(6):448–9. [PubMed: 19224889]
6. Felgentreff K, Lee YN, Frugoni F, du L, van der Burg M, Giliani S, et al. Functional analysis of naturally occurring DCLRE1C mutations and correlation with the clinical phenotype of ARTEMIS deficiency. *J Allergy Clin Immunol*. 2015;136(1):140–50. [PubMed: 25917813]
7. Mathieu AL, Verronese E, Rice GI, et al. PRKDC mutations associated with immunodeficiency, granuloma, and autoimmune regulator- dependent autoimmunity. *J Allergy Clin Immunol*. 2015;135(6): 1578–88.e5.
8. Slack J, Albert MH, Balashov D, Belohradsky BH, Bertaina A, Bleesing J, et al. Outcome of hematopoietic cell transplantation for DNA double-strand break repair disorders. *J Allergy Clin Immunol*. 2018;141(1):322–8. [PubMed: 28392333]
9. Perelygina L, Hautala T, Seppanen M, Adebayo A, Sullivan KE, Icenogle J. Inhibition of rubella virus replication by the broad-spectrum drug nitazoxanide in cell culture and in a patient with a primary immune deficiency. *Antivir Res*. 2017;147:58–66. [PubMed: 28974385]

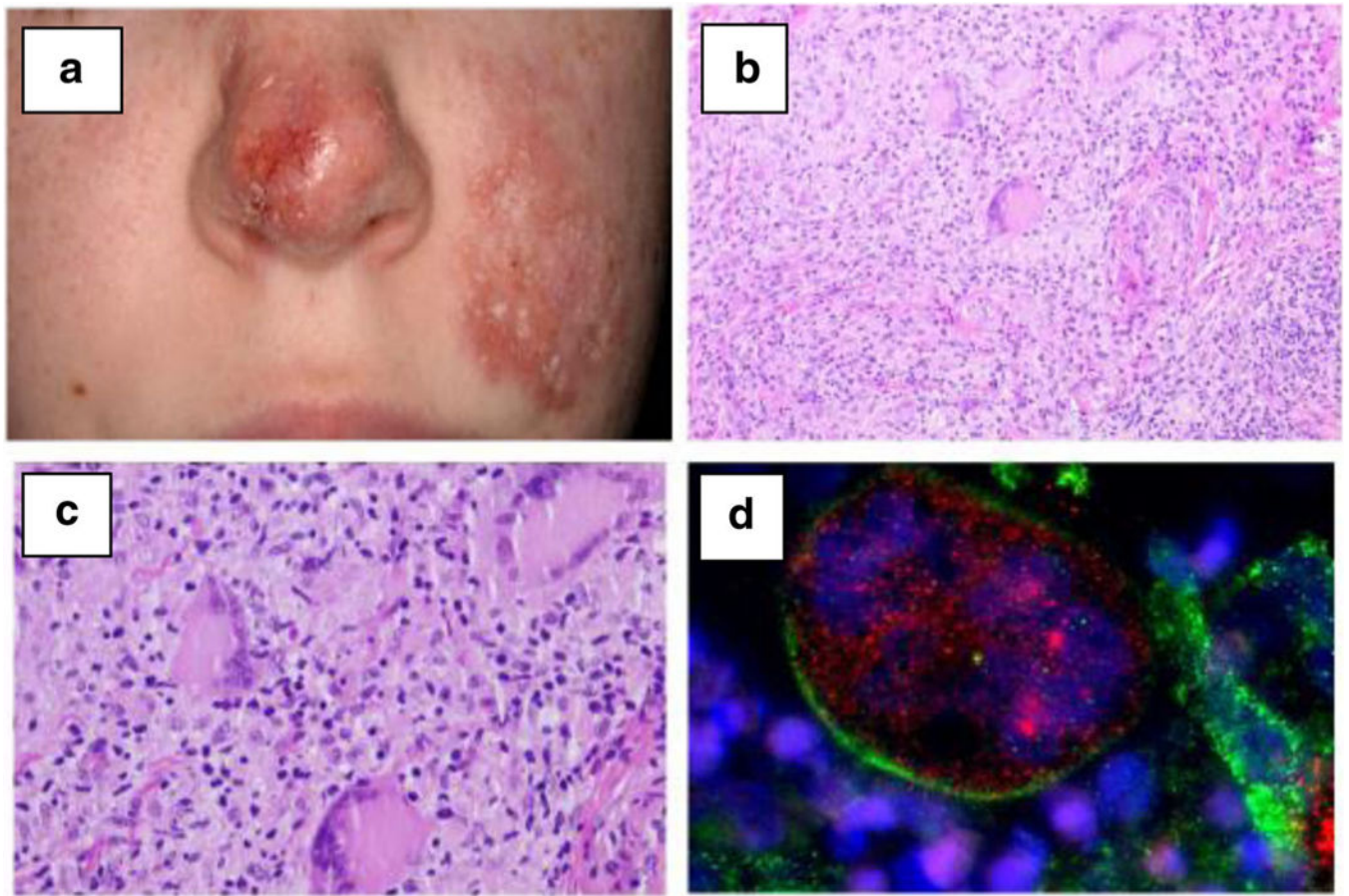


Fig. 1.
a Macroscopic features in patient no. 21 with acute and chronic ulcerations of the cheek and destruction of the nasal cartilage. **b, c** Histopathology of lesional skin in patient no. 21 with granulomatous dermatitis—H&E staining. Nodular, superficial, and deep dermal lymphohistiocytic infiltrate. **d** Histological immunofluorescent staining demonstrating the presence of rubella virus capsid (red) in Langerhans' giant cells (green) in patient no. 21

Table 1

Clinical and immunological characteristics of new and previously reported cases of immunodeficiency-related vaccine-derived rubella virus-associated cutaneous granulomatous disease in patients with DNA repair disorders and other primary immunodeficiency disorders

Patient no./Ref.	Age (yrs)	Sex	DNA breakage syndrome	Mutation	Clinical features	Immunophenotype	Age at vaccination with rubella and start of cutaneous granulomas (months)
1 Deripapa 2017	8	M	Nijmegen breakage syndrome	c. 657_661_del5 and c. 657_661_del5	Granulomatous dermatitis	T and B cell lymphopenia, hypogammaglobulinemia	13 months/24 months
2 Deripapa 2017	15	F	Nijmegen breakage syndrome	c. 657_661_del5 and c. 657_661_del5	Diffuse large B cell lymphoma, granulomatous dermatitis	T and B cell lymphopenia, hypogammaglobulinemia	16 months/168 months
3 Deripapa 2017	15	F	Nijmegen breakage syndrome	c. 657_661_del5 and c. 657_661_del5	Diffuse large B cell lymphoma, ganglioglioma, granulomatous dermatitis	T and B cell lymphopenia, hypogammaglobulinemia	14 months/120 months
4 New Case	10	M	Nijmegen breakage syndrome	c. 657_661_del5 and c. 657_661_del5	Lymphoma treated with chemotherapy and rituximab, granulomatous dermatitis of cheek	T and B cell lymphopenia, hypogammaglobulinemia	13 months/NA
5 New Case	11	F	AT	NA	ILLD, EBV- lymphoproliferative disease, granulomatous dermatitis	T and B cell lymphopenia, hypogammaglobulinemia	12 months/60 months
6 New Case	10	F	AT	NA	ILLD, granulomatous dermatitis, infections	T and B cell lymphopenia, hypogammaglobulinemia hyper M	16 months/108 months
7 New Case	7	F	AT	NA	ILLD, granulomatous dermatitis, granulomatous spleen and liver lesions	T and B cell lymphopenia, hypogammaglobulinemia hyper IgM	13 months/24 months
8 New Case	7	F	AT	c. 8781_8786 + 2del and c. 8781_8786 + 2del	Pancytopenia, transaminitis, granulomatous dermatitis / spleen lesions, chronic lung disease, probably partial thymectomy after heart surgery for Tetralogy of Fallot	T and B cell lymphopenia. Poor mitogen responses, hypogammaglobulinemia poor antibody responses. Constantly positive rubella IgM	13 months/39 months
9 Pereygina 2016	9	F	AT	NA	Granuloma annulare, lymphoproliferative disorder, non-Hodgkin lymphoma, immune cytopenias	T and B cell lymphopenia, hypogammaglobulinemia hyper IgM	NA/NA
10 Pereygina 2016	3	F	AT	IVS32 + 1 and 5726 T>Gpl909 Meth>Arg	Failure to thrive, developmental delay, granulomatous skin lesions, developed B cell lymphoma	T and B cell lymphopenia. Poor mitogen responses, hypogammaglobulinemia-poor antibody responses	12 months/NA
11 Pereygina 2016	5	F	AT	NA	Proteinuria, granulomatous dermatitis, trunk, pelvic lesion on x-ray	Hyper IgM	NA/NA
12 New Case	18	M	AT	NA	Cutaneous/hepatic granulomatosis, diabetes, polyarthritis, squamous cell carcinoma	T and B cell lymphopenia, hypogammaglobulinemia-poor antibody responses. Hyper IgM	NA/48 months

Patient no./Ref.	Age (yrs)	Sex	DNA breakage syndrome	Mutation	Clinical features	Immunophenotype	Age at vaccination with rubella and start of cutaneous granulomas (months)
13 Perylygina 2016	7	F	AT	Homozygous deletion with frameshift, absent protein	Diffuse granulomas, skin, liver, lungs, skeleton after chemotherapy for Hodgkin lymphoma	Hyper IgM	NA/NA
14 New Case	13	M	Artemis deficiency	c.194C > T and c.194C > T	Granulomatous dermatitis	Poor antibody responses	12 month/86 month
15 New Case	4	F	Ligase 4 deficiency	c.1341G>T and c.1103A>T	Bronchiectasis, villous atrophy, marrow failure, granulomatous dermatitis and liver lesions	T and B cell lymphopenia, hypogammaglobulinemia-poor antibody responses	12 months/14 months
16 New Case	33	F	Cartilage hair hypoplasia	Compound heterozygous	Diffuse large B cell lymphoma (20 years); autoimmune hemolytic anemia (27 years), hepatomegaly splenomegaly	T cell lymphopenia, naive T cell and memory B cell lymphopenia	216 months/324 months
17 New Case	3	F	MHC class II Deficiency	RFXANK c.338-25_338del homozygous	Severe chicken pox, cerebral vasculitis, hemiparesis, skin granuloma	T cell lymphopenia	9 months/22 months
18 New Case	18	F	WHIM syndrome	NA skin granuloma (cheeks)	T and B cell lymphopenia, neutropenia	T and B cell lymphopenia, neutropenia	NA/192 months
19 New Case	18	M	Coronin 1A Deficiency	Homozygous c.717G > A in CORO 1A exon 4 resulting in V134M	EBV-induced B cell lymphoproliferation (1 year), recurrent infections, bronchiectasis, reported in Moshous et al. JACI 2013.	T cell lymphopenia, naive T cell and memory B cell lymphopenia, antibody deficiency	NA/156 months
20 New Case	16	M	X-SCID	hemizygous c.209 T > C	Failure to thrive, multiple viral and bacterial infections, bronchiectasis, skin granulomas (face shoulder, knee)	T and NK lymphopenia	24 months/120 months
21 New Case	14	F	Combined immune deficiency	No mutation identified with whole exome sequencing	Facial dermatitis with destruction of nasal cartilage	T and B cell lymphopenia, moderate B lymphopenia	12 month/147 month

Patient no./Ref.	Biopsy Findings	Treatment of cutaneous granuloma and outcomes	Effect	Diagnosis of rubella Follow-up virus
1 Deripapa 2017	Superficial and dermal epithelioid granuloma with lymphocytic infiltration	Multiple courses of antibiotics and topical steroids, HSCT conditioning (busulfan, fludarabine, ATG, cyclophosphamide, rituximab)	None. Effect post-conditioning	PCR positive
2 Deripapa 2017	Superficial and dermal granulomas with necrosis, perivascular infiltration with lymphocytes, plasma cells and histiocytes	HSCT conditioning (busulfan, fludarabine, ATG, cyclophosphamide, rituximab)	None. Effect post-conditioning	PCR positive
3 Deripapa 2017	Epithelial ulcers. Dermal granulomas with central necrosis. Mixed cell infiltration (CD8 lymphocytes, plasmacytes, neutrophils)	Multiple courses of antibiotics and topical steroids	None	PCR positive

Patient no./Ref.	Biopsy Findings	Treatment of cutaneous granuloma and outcomes	Effect	Diagnosis of rubella Follow-up virus
4 New Case	Sarcoidal granulomatous dermatitis and perifolliculitis	Permethrin ivermectin keflex minocycline metronidazole gel	None	Positive
5 New Case	Dermal epithelioid granulomas with central necrosis. Mixed cells perivascular infiltration (CD4, CD8, CD20)	Multiple courses of antibiotics and topical steroids	None	PCR positive
6 New Case	Intradermal mixed cells infiltration (CD8, eosinophils, histiocytes)	Nitazoxanide	None	PCR positive
7 New Case	Dermal epithelioid granulomas with necrosis, giant cells formation. Mixed cells perivascular infiltration	Interferon-alfa	None	NA
8 New Case	Dermal lymphohistiocytic infiltration with granuloma-like macrophage aggregations. Infiltrate predominantly positive for CD68 and CD163	Nitazoxanide	Progressive dermatitis	PCR positive (RA27/3). IHC positive (skin and spleen)
9 Perylygina 2016	Necrotizing granulomatous inflammation	Oral/topical antibiotics, topical steroids	None	IHC positive
10 Perylygina 2016	Dermal chronic inflammation. Deep dermis with large and small necrotizing granulomas	Topical steroids and nutrition	Treatment effective	IHC positive
11 Perylygina 2016	Necrotic vasculitis with neutrophilic infiltrates and necrotizing granulomatous inflammation of dermis	Oral/topical steroids	None	IHC positive
12 New Case	Granulomatous inflammation with necrosis	Surgery, emollients, topical steroid, nitazoxanide, etanercept	NA	IHC positive skin and liver
13 Perylygina 2016	Non-infectious granulomatous process	Oral and topical steroids	Partial	IHC positive
14 New Case	Dermal epithelioid granulomas with necrosis, giant cells formation	Topical steroids, IVIG, cotrimoxazole, conditioning with alemtuzumab, fludarabine, treosulfan	Dermatitis resolved after HSCT	IHC positive (skin)
15 New Case	Nodular, superficial and deep dermal lymphohistiocytic infiltrate with scattered lymphohistiocytic cells	Topical steroids, IVIG (for immune deficiency), HSCT conditioning (fludarabine, cyclophosphamide, alemtuzumab), nitazoxanide	None. Effect post-conditioning.	IHC positive (skin and liver)
16 New Case	Granuloma skin biopsy	Cyclosporine, corticosteroids	Progressive disease	PCR positive
17 New Case	Granuloma skin biopsy	None	Stable disease	PCR positive
18 New Case	Granuloma skin biopsy	Topical steroids, anti-TNF therapy	Improved with anti-TNF therapy	PCR positive
19 New Case	Granuloma skin biopsy	Antibiotics, topical steroids, surgical excision	Stable disease	PCR positive
20 New Case	Granulomatous dermatitis with epithelioid granulomas	Subcutaneous immunoglobulin	Stable disease	IHC positive
21 New Case	Granulomatous dermatitis with non-necrotizing epithelioid granulomas, giant cell formation, and dermal microcysts	Topical: steroids, acrolimus; systemic: steroids, chloroquin, methotrexate,	Dermatitis resolved after HSCT, but plastic surgery will be needed	PCR positive (RA27/3)

Author Manuscript

Author Manuscript

Author Manuscript

Author Manuscript

Patient no./Ref.	Biopsy Findings	Treatment of cutaneous granuloma and outcomes	Effect	Diagnosis of rubella Follow-up virus
<p><i>AT</i> ataxia telangiectasia, <i>HSC</i> hematopoietic stem cell transplantation, <i>IHC</i> immunohistochemistry, <i>ILD</i> interstitial lymphocytic lung disease, <i>IVIG</i> intravenous immunoglobulin, <i>NA</i> not available, <i>PCR</i> polymerase chain reaction, <i>X-SCID</i> X-linked severe combined immunodeficiency</p>	<p>clarithromycin, doxycycline, ciprofloxacin; nitazoxanide</p>			