



**HAL**  
open science

## Hidden Biomass of Intact Malaria Parasites in the Human Spleen

Steven Kho, Labibah Qotrunnada, Leo Leonardo, Benediktus Andries, Putu A. I. Wardani, Aurelie Fricot, Benoit Henry, David Hardy, Nur I. Margyaningsih, Dwi Apriyanti, et al.

► **To cite this version:**

Steven Kho, Labibah Qotrunnada, Leo Leonardo, Benediktus Andries, Putu A. I. Wardani, et al.. Hidden Biomass of Intact Malaria Parasites in the Human Spleen. *New England Journal of Medicine*, 2021, 384 (21), pp.2067-2069. 10.1056/NEJMc2023884 . pasteur-03249650

**HAL Id: pasteur-03249650**

**<https://pasteur.hal.science/pasteur-03249650>**

Submitted on 4 Jun 2021

**HAL** is a multi-disciplinary open access archive for the deposit and dissemination of scientific research documents, whether they are published or not. The documents may come from teaching and research institutions in France or abroad, or from public or private research centers.

L'archive ouverte pluridisciplinaire **HAL**, est destinée au dépôt et à la diffusion de documents scientifiques de niveau recherche, publiés ou non, émanant des établissements d'enseignement et de recherche français ou étrangers, des laboratoires publics ou privés.

Copyright

## CORRESPONDENCE



## Hidden Biomass of Intact Malaria Parasites in the Human Spleen

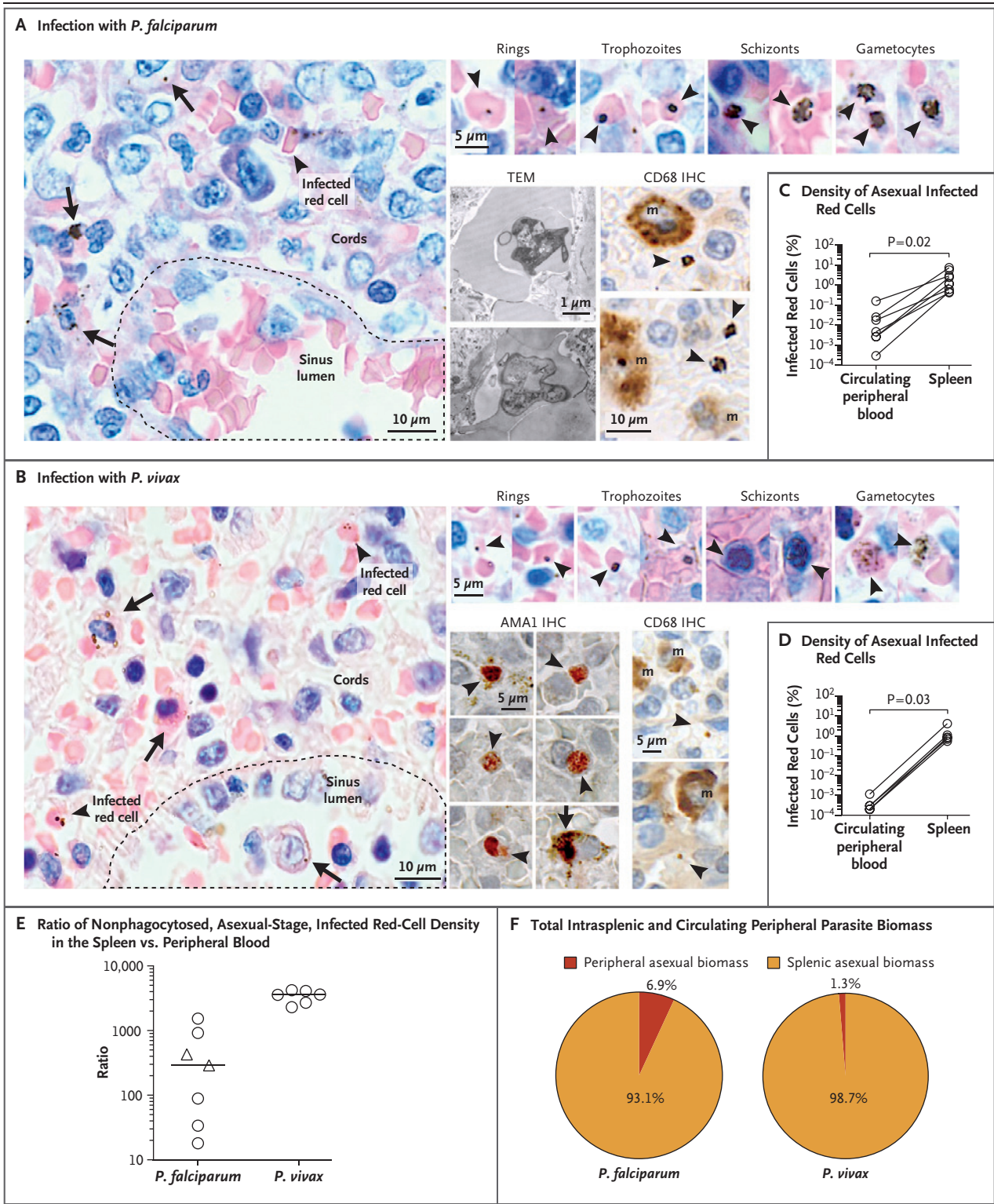
**TO THE EDITOR:** Intraerythrocytic malaria parasites are assumed to have predominantly intravascular tropism, with the spleen considered to be principally a site for parasite destruction, as is evident after antimalarial treatment.<sup>1</sup> We hypothesized a more complex role for the spleen in human malaria and explored the possibility that viable, plasmodium-infected red cells accumulate in this organ.<sup>2,3</sup> In a prospective study, we obtained spleen tissue and peripheral blood from 15 largely untreated, asymptomatic adults in malaria-endemic Papua, Indonesia, whose infection with *Plasmodium falciparum* (9 patients) or *P. vivax* (6 patients) was confirmed on polymerase-chain-reaction assay. All the patients had undergone splenectomy, mostly due to trauma (for cohort characteristics, see Table S1 in the Supplementary Appendix, available with the full text of this letter at NEJM.org).

Nonphagocytosed, intact red cells infected with *P. falciparum* or *P. vivax* in all stages of development were observed under microscopic examination of Giemsa-stained spleen sections and quantitated with the use of a counting method validated in an earlier study.<sup>4</sup> These observations were confirmed on electron microscopy and on immunohistochemical analysis conducted with the use of a *P. vivax* apical membrane antigen-1 marker and the macrophage marker CD68 (Fig. 1A and 1B, respectively). Further analysis (available in the Supplementary Appendix) revealed a large, previously unrecognized biomass of asexual-stage parasites accumulating in the spleen. Nonphagocytosed red cells infected with parasites were observed in densities hundreds to thousands of times higher than in circulating blood ( $P=0.02$  for the comparison with *P. falciparum*, and  $P=0.03$  for the comparison with *P. vivax*; see Fig. 1C and 1D, respectively). Splenic infection with *P. vivax* was unde-

tectable in the peripheral blood of 1 patient and splenic infection with *P. falciparum* was undetectable in the peripheral blood of 2 patients on polymerase-chain-reaction assays (Table S1 in the Supplementary Appendix). Splenic tropism was greatest in *P. vivax* infections, in which the median splenic density was 3590 times as high as that in peripheral blood (range, 2300 to 4210) and far greater than the estimated spleen-to-blood ratio in *P. falciparum* infections (median, 289; range, 18 to 1530) (in Fig. 1E). In spleens infected with *P. falciparum*, the mean percentage of asexual-stage parasites characterized as rings or trophozoites was 81% (95% confidence interval [CI], 66 to 96) and the mean percentage characterized as schizonts was 19% (95% CI, 4 to 34). In spleens infected with *P. vivax*, these proportions were 95% (95% CI, 86 to 100) and 5% (95% CI, 0 to 14), respectively. Parasite viability was confirmed in seven of nine *P. falciparum* infections (Fig. S1A in the Supplementary Appendix). Estimates of intrasplenic and peripheral biomasses (Fig. S1B) indicated that among the total number of asexual-stage *P. vivax* parasites, the spleen contained 98.7% (95% CI, 89.4 to 99.8) and the circulation contained 1.3% (95% CI, 0.2 to 10.6) (Fig. 1F). Estimates of the asexual-stage *P. falciparum* splenic biomass, given the as-

### THIS WEEK'S LETTERS

- 2067** Hidden Biomass of Intact Malaria Parasites in the Human Spleen
- 2070** Race and Genetic Ancestry in Medicine
- e81** Avacopan for the Treatment of ANCA-Associated Vasculitis
- e82** Cryoablation as Initial Therapy for Atrial Fibrillation



sumption that one mature form was sequestered for each circulating ring,<sup>5</sup> suggested that it was at least two times as large as that in the circulation.

In conclusion, in our small cohort study of

asymptomatic persons naturally infected with *P. falciparum* or *P. vivax*, a large biomass of intact, infected red cells accumulated in the spleen. The circulating compartment is important for path-

**Figure 1 (facing page). Accumulation of Intact, Asexual-Stage *P. falciparum* and *P. vivax*, in the Spleens of Patients with Asymptomatic Infection.**

Tissue sections of the spleen were stained with Giemsa and assessed for the presence of infection with plasmodium species at a magnification of 400. Representative Giemsa fields within the red pulp are shown in the spleens from two patients, one infected with *P. falciparum* (Panel A) and the other with *P. vivax* (Panel B), with clear distinction of architectural zones. Nonphagocytosed, intact, infected red cells were observed frequently (arrowheads) and were categorized into developmental stages on the basis of their morphologic appearance (ring forms, trophozoites, schizonts, and gametocytes). Structures resembling pigmented phagocytes were also present (arrows). Nonphagocytosed red cells infected with *P. falciparum* were also observed on transmission electron microscopy (TEM). Immunohistochemical (IHC) staining with CD68 confirmed the localization of infected cells outside macrophages (m). Antibodies against *P. vivax* apical membrane antigen-1 (AMA-1), a marker for *P. vivax* mature stages (staining red), supported the existence of *P. vivax* trophozoites and schizonts in the patient spleen (representative examples shown). Parasite counts revealed that densities of intact, infected red cells were significantly higher in the spleen than in the peripheral blood with both *P. falciparum* (Panel C, seven patients) and *P. vivax* (Panel D, six patients). The median ratio of asexual-stage infected red-cell density in the spleen versus circulating peripheral blood was higher with *P. vivax* than with *P. falciparum* (Panel E, with circular points representing untreated patients and triangular points recently treated patients). Spleen weight and estimated total blood volumes were used to calculate the total biomass in the spleen as a percentage of the total intrasplenic and circulating peripheral biomass for the two species (Panel F). Paired data points, assessed with the use of the Wilcoxon test, are shown in Panels C and D, and medians are shown in Panels E and F. Unadjusted P values <0.05 indicate statistical significance.

ogenesis and transmission, but, especially in *P. vivax*, it is neither the main site of the parasite biomass nor the main site of parasite interactions with cells mediating innate and adaptive immunity. The accumulation of young and mature parasites in stages proportional to their asexual life cycle in vivo and the magnitude of the ratio of the infected red cells in the spleen as compared with the peripheral blood suggest an endosplenic life cycle in both species, and one of greater magnitude in *P. vivax* (see the Supplementary Appendix for computations). Chronic malaria may be viewed primarily as an infection of the spleen rather than exclusively as an infection of the blood.

Steven Kho, Ph.D.

Menzies School of Health Research  
Darwin, NT, Australia

Labibah Qotrunnada, M.Sc.

Eijkman Institute for Molecular Biology  
Jakarta, Indonesia

Leo Leonardo, B.Sc.

Benediktus Andries, M.D.

Papuan Health and Community Development Foundation  
Timika, Indonesia

Putu A.I. Wardani, M.D.

Rumah Sakit Umum Daerah Kabupaten Mimika  
Papua, Indonesia

Aurelie Fricot, Ph.D.

Inserm  
Paris, France

Benoit Henry, M.D., Ph.D.

University of Paris  
Paris, France

David Hardy, Ph.D.

Institut Pasteur  
Paris, France

Nur I. Margyaningsih, M.Sc.

Dwi Apriyanti, B.Sc.

Agatha M. Puspitasari, B.Sc.

Eijkman Institute for Molecular Biology  
Jakarta, Indonesia

Pak Prayoga, Diploma in Laboratory Analysis

Papuan Health and Community Development Foundation  
Timika, Indonesia

Leily Trianty, Ph.D.

Eijkman Institute for Molecular Biology  
Jakarta, Indonesia

Enny Kenangalem, M.D.

Papuan Health and Community Development Foundation  
Timika, Indonesia

Fabrice Chretien, M.D., Ph.D.

Institut Pasteur  
Paris, France

Innocent Safeukui, Ph.D.

University of Notre Dame  
Notre Dame, IN

Hernando A. del Portillo, Ph.D.

Carmen Fernandez-Becerra, Ph.D.

ISGlobal  
Barcelona, Spain

Elamaran Meibalan, Ph.D.

Brigham and Women's Hospital  
Boston, MA

Matthias Marti, Ph.D.

University of Glasgow  
Glasgow, United Kingdom

Ric N. Price, M.D., F.R.A.C.P.

Tonia Woodberry, Ph.D.  
Menzies School of Health Research  
Darwin, NT, Australia

Papa A. Ndour, Ph.D.

University of Paris  
Paris, France

Bruce M. Russell, Ph.D.

University of Otago  
Dunedin, New Zealand

Tsin W. Yeo, M.D., Ph.D.

Menzies School of Health Research  
Darwin, NT, Australia

Gabriela Minigo, Ph.D.

Charles Darwin University  
Darwin, NT, Australia

Rintis Noviyanti, Ph.D.

Eijkman Institute for Molecular Biology  
Jakarta, Indonesia

Jeanne R. Poespoprodjo, M.D., Ph.D.

Papuan Health and Community Development Foundation  
Timika, Indonesia

Nurjati C. Siregar, M.D., Ph.D.

Eijkman Institute for Molecular Biology  
Jakarta, Indonesia

Pierre A. Buffet, M.D., Ph.D.

University of Paris  
Paris, France

Nicholas M. Anstey, F.R.A.C.P., Ph.D.

Menzies School of Health Research  
Darwin, NT, Australia  
nicholas.anstey@menzies.edu.au

Drs. Anstey and Buffet contributed equally to this letter.

Supported by program grant no. 1037304, by fellowship nos. 1042072 and 1135820, to Dr. Anstey, by a grant (no. 1131932) from Improving Health Outcomes in the Tropical North, and

by the Australian Centre of Research Excellence in Malaria Elimination — all through the Australian National Health and Medical Research Council; by a grant from the Institut National de la Santé et de la Recherche Médicale, to Dr. Buffet; by a grant from the Wellcome Trust (no. 099875), to Dr. Poespoprodjo; by a Senior Wellcome Trust Fellowship in Clinical Science award (no. 200909), to Dr. Price; by an Australian Government Postgraduate Award Scholarship, to Dr. Kho; by a Royal Society Wolfson Research Merit award, to Dr. Marti; and by the Australian Department of Foreign Affairs and Trade.

Disclosure forms provided by the authors are available with the full text of this letter at NEJM.org.

1. Chotivanich K, Udomsangpetch R, McGready R, et al. Central role of the spleen in malaria parasite clearance. *J Infect Dis* 2002;185:1538-41.
2. Barber BE, William T, Grigg MJ, et al. Parasite biomass-related inflammation, endothelial activation, microvascular dysfunction and disease severity in vivax malaria. *PLoS Pathog* 2015;11(1):e1004558.
3. Machado Siqueira A, Lopes Magalhães BM, Cardoso Melo G, et al. Spleen rupture in a case of untreated Plasmodium vivax infection. *PLoS Negl Trop Dis* 2012;6(12):e1934.
4. Safeukui I, Correas J-M, Brousse V, et al. Retention of Plasmodium falciparum ring-infected erythrocytes in the slow, open microcirculation of the human spleen. *Blood* 2008;112:2520-8.
5. Dondorp AM, Desakorn V, Pongtavornpinyo W, et al. Estimation of the total parasite biomass in acute falciparum malaria from plasma PfHRP2. *PLoS Med* 2005;2(8):e204.

DOI: 10.1056/NEJMc2023884

## Race and Genetic Ancestry in Medicine

**TO THE EDITOR:** In arguing that ancestral genotype should complement race categories in biomedical research, Borrell et al. (Feb. 4 issue)<sup>1</sup> misstate a finding that less than 2% of trials funded by the National Cancer Institute focused on any racial or minority population as their primary emphasis<sup>2</sup> and instead state that less than 2% of such trials included non-White participants. This error highlights the difference between bona fide and token inclusion.

ClinicalTrials.gov shows that the number of minority-focused trials has not grown, even though enrollment of non-Whites has nearly doubled over the past two decades.<sup>3</sup> This finding implies that most trials still lack the threshold for race-specific or genotypic analyses to be adequately powered.

For inclusion goals to work, we need to conduct more trials with non-White participants and enroll substantially more non-White participants in each trial. This challenge would be best met cooperatively, since individual medical centers, even when they are well positioned to recruit non-White participants, struggle to do so.<sup>4</sup>

The National Institutes of Health requires that

subgroup data provide adequate power if they are to be separately analyzed<sup>5</sup> but demands no specific level of minority participation and does not address the need for minority-focused trials. We believe the Biden administration should fix these shortcomings.

Kristine Enea, J.D., M.B.S.

Sanford H. Barsky, M.D.

California University of Science and Medicine  
Colton, CA  
barskys@cusm.org

No potential conflict of interest relevant to this letter was reported.

1. Borrell LN, Elhawary JR, Fuentes-Afflick E, et al. Race and genetic ancestry in medicine — a time for reckoning with racism. *N Engl J Med* 2021;384:474-80.
2. Chen MS Jr, Lara PN, Dang JH, Paterniti DA, Kelly K. Twenty years post-NIH Revitalization Act: enhancing minority participation in clinical trials (EMPaCT): laying the groundwork for improving minority clinical trial accrual: renewing the case for enhancing minority participation in cancer clinical trials. *Cancer* 2014;120:Suppl 7:1091-6.
3. Ong MBH. Participation by minority racial, ethnic groups in NCI-funded trials nearly doubles in 20 years. *The Cancer Letter*. June 26, 2020 ([https://cancerletter.com/the-cancer-letter/20200626\\_1/](https://cancerletter.com/the-cancer-letter/20200626_1/)).
4. Cancer Health Equity Institute. Funded research initiatives. Atlanta: Morehouse School of Medicine (<https://www.msm.edu/cancerhealthequityinstitute/research.php>).