



Kazachstania slooffiae: An unexpected journey to a human pleural sample

Victor Mercier, M. Desnos-Ollivier, Anaïs Lamy, Martin Mahul, Milène Sasso

► To cite this version:

Victor Mercier, M. Desnos-Ollivier, Anaïs Lamy, Martin Mahul, Milène Sasso. Kazachstania slooffiae: An unexpected journey to a human pleural sample. Journal of Medical Mycology = Journal de Mycologie Médicale, 2021, 31 (2), pp.101109. 10.1016/j.mycmed.2020.101109 . pasteur-03243543

HAL Id: pasteur-03243543

<https://pasteur.hal.science/pasteur-03243543>

Submitted on 3 Feb 2023

HAL is a multi-disciplinary open access archive for the deposit and dissemination of scientific research documents, whether they are published or not. The documents may come from teaching and research institutions in France or abroad, or from public or private research centers.

L'archive ouverte pluridisciplinaire **HAL**, est destinée au dépôt et à la diffusion de documents scientifiques de niveau recherche, publiés ou non, émanant des établissements d'enseignement et de recherche français ou étrangers, des laboratoires publics ou privés.



Distributed under a Creative Commons Attribution - NonCommercial 4.0 International License

***Kazachstania slooffiae*: An unexpected journey to a human pleural sample**

Victor MERCIER¹, Marie DESNOS-OLLIVIER², Anaïs LAMY³, Martin MAHUL⁴, Milène SASSO¹

¹ MIVEGEC, Univ. Montpellier, CHU de Nîmes, CNRS, IRD, Montpellier, France

² Institut Pasteur, CNRS, Molecular Mycology Unit, National Reference Center for Invasive Mycoses & Antifungals, UMR 2000, Paris, France

³ Department of Parasitology and Mycology, Nîmes University Hospital, Nîmes, France

⁴ Department of Intensive Care Unit, Nîmes University Hospital, Nîmes, France

Corresponding author:

Milène Sasso

Service de Parasitologie – Mycologie, CHU de Nîmes

Place du Professeur Robert Debré

30029 Nîmes, France

Tel: +33466683202, Fax: +33466684254

e-mail: milene.sasso@chu-nimes.fr

Abstract

We report a case of a 50-year-old shepherd hospitalized in intensive care unit for hiatal hernia complicated by an occlusive syndrome. In post-surgery, an acute respiratory distress occurs due to mediastinitis with large pleural effusion. At the laboratory, direct examination of the pleural sample revealed the presence of pseudohyphae. *Kazachstania slooffiae* was identified by Mass Spectrometry and confirmed by DNA sequencing. This uncommon yeast has never been previously described in human infections. Although its pathogenicity is not well known, *K. slooffiae* should be considered in the case of critically ill patients.

Key words

Kazachstania slooffiae, *Candida slooffiae*, emerging fungal disease, zoonoses, Mass Spectrometry, DNA sequencing,

Introduction

The genus *Kazachstania* includes more than 50 ascomycetous yeasts species that are ubiquitous [1–3]. Their implications in agribusiness are wide, such as wineprocess [2] or sourdoughs in traditional French wheat [4] but also frequently recovered from the gut of agriculturally important animals, with some species having host specificity.

We report a case of a 50-year-old shepherd hospitalized in intensive care unit for hiatal hernia complicated by an occlusive syndrome. In post-surgery, an acute respiratory distress occurs due to mediastinitis with large pleural effusion and *Kazachstania slooffiae* were isolated in pleural sample. This uncommon yeast, frequent colonizer of the porcine gastrointestinal tract, has never been previously described in human infections.

Case report

A 50-year-old man, living in the south of France as a shepherd, presented himself to the emergency room of Nîmes University Hospital, France, for an intestinal obstruction syndrome. He has a notable history of Lewis Santy's surgery for adenocarcinoma of the oesogastric junction with neoadjuvant chemotherapy which gave an excellent response four years ago. A contrasted computed tomography (CT) scan was performed and revealed an ischemic transverse colon with perforation and mediastinum contamination. The patient was quickly oriented to surgery. Subsequently, an empirical antibiotherapy was conducted while pleural and peritoneal samples were sent for microbiological analysis. Six hours after leaving the operating room, the patient presented an acute respiratory distress syndrome. A new CT scan revealed mediastinitis with a significant pleural effusion and pneumothorax, so the patient returned to the operating room. After the new surgery, he was transferred to the intensive care unit (ICU) with septic shock condition and acute respiratory distress condition, a treatment with caspofungin was added to the first antibiotherapy.

At the laboratory, direct examination of the pleural sample revealed pseudohyphae (Figure 1). On day 3, after the culture of the pleural sample, yeasts were isolated *in vitro* at 35°C on sabouraud-chloramphenicol-gentamicin medium, without actidione, and on BBL™ CHROMagar™ *Candida* medium (BD, Sparks, USA) exhibiting purple colonies. *Kazachstania slooffiae* (syn. *Candida slooffiae*) was identified by Mass Spectrometry with a score value of 99.9% (VITEK® MS, BioMérieux, Marcy l'Étoile, France). The identification was confirmed by DNA sequencing of the ITS regions and the D1-D2 domain of the large subunit (26S) rRNA gene, performed in our center and also at the National Reference Center for Invasive Mycoses and Antifungals (NRCMA) (Genbank accession numbers MT457819 and MT457852). Unfortunately, the absence of subculture on RPMI, while the antifungal susceptibility testing was performed by gradient diffusion and EUCAST methods, did not allow the determination of MICs (minimum inhibitory concentrations). Due to all microbiological findings, the antifungal treatment with caspofungin was maintained.

On day 10, due to its clinical evolution, with a further worsening of respiratory and septic conditions, a CT scan was performed and showed the persistence of right pleural empyema. He was treated with a new surgery with a thoracotomy and a large right pleural decortication. New pleural samples were collected and sent to the

laboratory for microbiological analysis. Results revealed the persistence of aerobic and anaerobic bacteria of the gastrointestinal tract (GIT) despite antibiotherapy, while fungal species, especially *K. slooffiae*, were absent. For safety reasons, it was decided to continue the antifungal treatment for six weeks.

Finally, after this final surgery, the patient presented a good recovery of the organ dysfunction and control of the septic source. He was discharged from the ICU 25 days after his admission to hospital.

Discussion

Kazachstania slooffiae belonged to the *Kazachstania* (*Arxiozyma*) *telluris* complex with other species such as *K. pintolopesii*, *K. telluris* and *K. bovina* [3]. Species of this complex have been isolated from different hosts, *K. pintolopesii* almost exclusively from rodents, *K. telluris* from soil and pigeons, *K. bovina* from birds, a cow, and a human [3]. *Kazachstania slooffiae* has been frequently found in horses [3] and in different parts of the GIT of apparently healthy pigs and is therefore considered as a natural resident of the porcine intestinal environment [5,6]. As the gastrointestinal tract pig has been studied as a model for the colonization of humans by yeast [7,8], this may suggest that this species can be adapted for human GIT. This case is the first which describes the isolation of *K. slooffiae* from a human sample, but the source of contamination is unclear. As a shepherd, one hypothesis that could explain the contamination of the digestive tract would be contact with animals. Another recent case report describes a *K. bovina* bloodstream infection in a 94-year-old patient in France [10].

In our case, on direct examination of the pleural sample, we noticed the presence of non-classical fungal elements (only pseudohyphae) and then, three days later, we obtained yeast colonies on fungal culture media. The modern tools available, such as Mass Spectrometry or DNA sequencing, allow the identification of a wide range of unusual microorganisms, provided that the fragmentation scheme or DNA sequence used exists in the database [9]. Using all these tools, the species *K. slooffiae* was identified and confirmed. However, identification by Mass Spectrometry must be interpreted with caution because of the risk of misidentification of species within the *Kazachstania* (*Arxiozyma*) *telluris* complex [10]. DNA sequencing should confirm the identifications of these rare species.

Kazachstania slooffiae is an uncommon yeast, never previously described in human infection, but which should be considered in the case of critically ill patients. Moreover, immunocompromised patients are more susceptible to infections caused by opportunistic microorganisms, especially those from the host's GIT [11]. Indeed, agents with low virulence potential may lead to invasive and often life-threatening infections due to impaired host immune function [12].

As there are no data on its antifungal management, an empiric treatment has been introduced with caspofungin, known for its fungicidal action on ascomycetous yeasts and used in cases of invasive candidiasis [13]. In our case, the antifungal susceptibility testing could not be performed because of the absence of subculture on RPMI. The NRCMA has already tested, using the EUCAST method, the antifungal susceptibility of 31 strains of 27 different *Kazachstania* sp. and found high percentage (54.8%) of isolates having high MICs for azoles, but low percentage (6.5%) of isolates with high MIC for caspofungin suggesting a potent *in vitro* activity of caspofungin [14]. Moreover, MICs appear to be very low for 5-fluorocytosine, caspofungin and micafungin (unpublished data).

Conclusion

The field of medical mycology has become an extremely challenging study of infections caused by a wide range of opportunistic fungi and this case illustrates the emergence of unusual species. The identification of these species must be confirmed by DNA sequencing. The message to both clinicians and clinical microbiologists is that there are no uniformly non-pathogenic fungi: any fungus can cause infection in a sufficiently immunocompromised host and should never be dismissed out of hand as a contaminant.

Declarations.

Declarations of interest: none

Bibliographic references

1. Jacques N, Sarilar V, Urien C, Lopes MR, Morais CG, Uetanabaro APT, *et al.* Three novel ascomycetous yeast species of the *Kazachstania* clade, *Kazachstania saulgeensis* sp. nov., *Kazachstania serrabonitensis* sp. nov. and *Kazachstania australis* sp. nov. Reassignment of *Candida humilis* to *Kazachstania humilis* f.a. comb. nov. and *Candida pseudohumilis* to *Kazachstania pseudohumilis* f.a. comb. nov. *Int J Syst Evol Microbiol.* 2016;66:5192–200.
2. Jood I, Hoff JW, Setati ME. Evaluating fermentation characteristics of *Kazachstania* spp. and their potential influence on wine quality. *World J Microbiol Biotechnol.* 2017;33:129.
3. Kurtzman CP, Robnett CJ, Ward JM, Brayton C, Gorelick P, Walsh TJ. Multigene phylogenetic analysis of pathogenic *Candida* species in the *Kazachstania* (*Arxiozyma*) *telluris* complex and description of their ascospore states as *Kazachstania bovina* sp. nov., *K. heterogenica* sp. nov., *K. pintolopesii* sp. nov., and *K. slooffiae* sp. nov. *J Clin Microbiol.* 2005;43:101–11.
4. Lhomme E, Urien C, Legrand J, Dousset X, Onno B, Sicard D. Sourdough microbial community dynamics: An analysis during French organic bread-making processes. *Food Microbiol.* 2016;53:41–50.
5. Urubschurov V, Janczyk P, Souffrant W-B, Freyer G, Zeyner A. Establishment of intestinal microbiota with focus on yeasts of unweaned and weaned piglets kept under different farm conditions. *FEMS Microbiol Ecol.* 2011;77:493–502.
6. Van Uden N, do SOUSA LC. Quantitative aspects of the intestinal yeast flora of swine. *J Gen Microbiol.* 1962;27:35–40.
7. Zhang Q, Widmer G, Tzipori S. A pig model of the human gastrointestinal tract. *Gut Microbes.* 2013;4:193–200.
8. Hoeflinger JL, Coleman DA, Oh S-H, Miller MJ, Hoyer LL. A piglet model for studying *Candida albicans* colonization of the human oro-gastrointestinal tract. *FEMS Microbiol Lett.* 2014;357:10–5.
9. Lee H, Park J-H, Oh J, Cho S, Koo J, Park IC, *et al.* Evaluation of a new matrix-assisted laser desorption/ionization time-of-flight mass spectrometry system for the identification of yeast isolation. *J Clin Lab Anal.* 2019;33:e22685.

10. Brunet K, Minoza A, Rammaert B, Portet-Sulla V, Hubert F, Lorenzo J-C, et al. Invasive *Candida bovina* Infection, France. *Emerg Infect Dis.* 2020;26:626–7.
11. Safdar A, Armstrong D. Infectious morbidity in critically ill patients with cancer. *Crit Care Clin.* 2001;17:531–70, vii–viii.
12. Dalle F, Wächtler B, L'Ollivier C, Holland G, Bannert N, Wilson D, et al. Cellular interactions of *Candida albicans* with human oral epithelial cells and enterocytes. *Cell Microbiol.* 2010;12:248–71.
13. Mora-Duarte J, Betts R, Rotstein C, Colombo AL, Thompson-Moya L, Smietana J, et al. Comparison of caspofungin and amphotericin B for invasive candidiasis. *N Engl J Med.* 2002;347:2020–9.
14. Desnos-Ollivier M, Robert V, Raoux-Barbot D, Groenewald M, Dromer F. Antifungal susceptibility profiles of 1698 yeast reference strains revealing potential emerging human pathogens. *PloS One.* 2012;7:e32278.

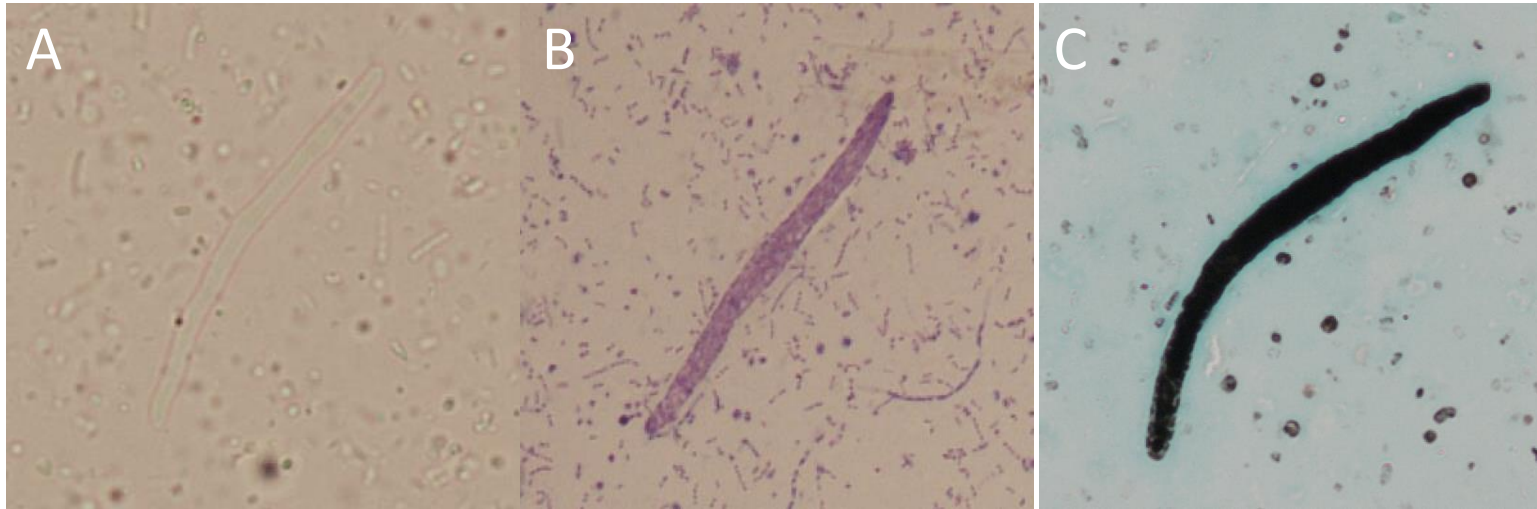


Figure 1 : Direct examination of the pleural sample showing pseudohyphae on fresh preparation (A), on May-Grunwald-Giemsa (B) and Gomori-Grocott staining (C).