



**HAL**  
open science

## **JAK inhibitors are effective in a subset of patients with juvenile dermatomyositis: a monocentric retrospective study**

Tom Le Voyer, Cyril Gitiaux, François-Jérôme Authier, Christine Bodemer, Isabelle Melki, Pierre Quartier, Florence Aeschlimann, Arnaud Isapof, Jean Philippe Herbeuval, Vincent Bondet, et al.

### ► To cite this version:

Tom Le Voyer, Cyril Gitiaux, François-Jérôme Authier, Christine Bodemer, Isabelle Melki, et al.. JAK inhibitors are effective in a subset of patients with juvenile dermatomyositis: a monocentric retrospective study. *Rheumatology*, 2021, pp.keab116. 10.1093/rheumatology/keab116. pasteur-03236464

**HAL Id: pasteur-03236464**

**<https://pasteur.hal.science/pasteur-03236464v1>**

Submitted on 22 Jul 2022

**HAL** is a multi-disciplinary open access archive for the deposit and dissemination of scientific research documents, whether they are published or not. The documents may come from teaching and research institutions in France or abroad, or from public or private research centers.

L'archive ouverte pluridisciplinaire **HAL**, est destinée au dépôt et à la diffusion de documents scientifiques de niveau recherche, publiés ou non, émanant des établissements d'enseignement et de recherche français ou étrangers, des laboratoires publics ou privés.



Distributed under a Creative Commons Attribution - NonCommercial 4.0 International License

## **JAK inhibitors are effective in a subset of patients with juvenile dermatomyositis: a monocentric retrospective study**

Tom Le Voyer<sup>1,2</sup>, Cyril Gitiaux<sup>3,4</sup>, François-Jérôme Authier<sup>5,6</sup>, Christine Bodemer<sup>7</sup>, Isabelle Melki<sup>1,8,9</sup>, Pierre Quartier<sup>1,10</sup>, Florence Aeschlimann<sup>1,10</sup>, Arnaud Isapof<sup>11</sup>, Jean Philippe Herbeuval<sup>12</sup>, Vincent Bondet<sup>13</sup>, Jean-Luc Charuel<sup>14</sup>, Marie-Louise Frémond<sup>8</sup>, Darragh Duffy<sup>13</sup>, Mathieu P Rodero<sup>12</sup>, Brigitte Bader-Meunier<sup>1,10</sup>

1. Department of Paediatric Hematology-Immunology and Rheumatology, Necker-Enfants Malades Hospital, AP-HP, Paris, France, Reference center for Rheumatic, AutoImmune and Systemic diseases in children (RAISE), Paris, France
2. Laboratory of Human Genetics of Infectious Diseases, Imagine Institute, Paris University, Paris, France
3. Reference Centre for Neuromuscular Diseases, Necker-Enfants Malades Hospital, AP-HP., Paris, France.
4. Department of Paediatric Neurophysiology, Necker-Enfants Malades Hospital, AP-HP, Paris University, Paris, France.
5. INSERM U955-Team Relaix, Faculty of Medicine, University of Paris-Est Creteil, Creteil France.
6. Department of Pathology, Reference Centre for Neuromuscular Diseases, Henri Mondor University Hospitals, AP-HP, Créteil, France.
7. Department of Pediatric Dermatology and Dermatology, National Reference Centre for Genodermatosis and Rare Diseases of the Skin (MAGEC), Hôpital Necker-Enfants Malades, Assistance Publique-Hôpitaux de Paris, Université Paris Descartes, Paris, France
8. Laboratory of Neurogenetics and Neuroinflammation, Imagine Institute, Paris University, Paris, France
9. General Paediatrics, Department of Infectious Disease and Internal Medicine, Reference centre for Rheumatic, AutoImmune and Systemic diseases in children(RAISE), Robert Debré Hospital, AP-HP, Paris, France
10. Laboratory of Immunogenetics of Paediatric Autoimmunity, Imagine Institute, Inserm U 1163, Paris University, Paris, France Paris, France
11. Département de Paediatric Neurology, Reference Centre for Neuromuscular Diseases, Armand Trousseau Hospital, AP-HP, Paris, France.
12. Chimie & Biologie, Modélisation et Immunologie pour la Thérapie (CBMIT), Université Paris Descartes, CNRS, UMR8601, Paris, France
13. Translational Immunology Lab, Institut Pasteur, Paris, France
14. Laboratory of Immunology; La Pitié Hospital, AP-HP, Paris, France

## **Abstract**

**Objective:** To evaluate the efficacy and safety of JAK inhibitors (JAKi) in juvenile dermatomyositis (JDM).

**Methods:** We conducted a single-center retrospective study of patients with JDM treated by JAKi with a follow-up of at least 6 months. Proportion of clinically inactive disease (CID) within six months of JAKi initiation was evaluated using PRINTO criteria and skin Disease Activity Score. Serum IFN- $\alpha$  concentration was measured by SIMOA assay.

**Results:** Nine refractory and one new-onset patients with JDM treated with ruxolitinib (n=7) or baricitinib (n=3) were included. The main indications for treatment were refractory muscle involvement (n=8) and ulcerative skin disease (n=2). CID was achieved in 5/10 patients (2/2 anti-MDA5, 3/4 anti-NXP2, 0/3 anti-TIF1 $\gamma$  positive patients) within six months of JAKi introduction. All responders could withdraw plasmatic exchange, immunoadsorption and other immunosuppressive drugs. The mean daily steroid dose decreased from 1.1 mg/Kg (range 0.35-2 mg/Kg/d) to 0.1 (range, 0-0.3, p=0.008) in patients achieving CID, and was stopped in two. Serum IFN- $\alpha$  concentrations were elevated in all patients at the time of treatment initiation and normalized in both responder and non-responder. A muscle biopsy repeated in one patient 26 months after the initiation of JAKi, showed a complete restoration of muscle endomysial microvascular bed. Herpes zoster and skin abscesses developed in three and two patients, respectively.

**Conclusion:** JAKis resulted in a CID in a subset of new-onset or refractory patients with JDM and may dramatically reverse severe muscle vasculopathy. Overall tolerance was good except for a high rate of herpes zoster infection.

**Key-words:** juvenile dermatomyositis, type 1 interferon, Janus-kinase inhibitor

**Key messages**

- Janus kinase inhibitors (JAKis) resulted in remission in a subset of juvenile dermatomyositis patients (JDM)
- JAKis seem efficient especially in anti-MDA5 and anti-NXP2 positive refractory JDM
- Overall tolerance of JAKis was good except for a high rate of herpes zoster infection.

**Address correspondence to:** Brigitte Bader-Meunier, 149 rue de Sèvres, 75015 Paris, France  
e-mail: [brigitte.bader-meunier@aphp.fr](mailto:brigitte.bader-meunier@aphp.fr); telephone number: 33 1 44 49 43 32;  
fax number: 33 1 44 49 50 70

Juvenile dermatomyositis (JDM) is a heterogeneous disease in respect of clinical phenotype, association with myositis-specific autoantibodies (MSAs), pathological stigmata and response to treatment. According to the results of one randomized trial, a combination of corticosteroids and methotrexate (MTX) is now recommended in newly diagnosed cases of patients with JDM [1]. However, treatment failure was recorded in 13/46 (28%) of the patients assigned to this combination. Moreover, this trial did not take into account the heterogeneity of JDM, and did not include severe JDM (cutaneous or gastrointestinal ulceration, interstitial lung disease (ILD), cardiomyopathy) which may be refractory to MTX. Conventional second lines treatments comprise mostly rituximab, mycophenolate mofetil and cyclophosphamide. Janus kinase inhibitors (JAKis) had emerged as a promising treatment of refractory adult dermatomyositis (DM) [2]. To date, the efficacy of JAKis has been reported in only a few cases series of one to four refractory patients with JDM [3-6]. Herein, we report the evaluation of JAK inhibition in a larger single-center series of ten patients with refractory and severe newly-diagnosed JDM

We retrospectively reviewed all the patients with JDM followed in the referral center for Rare Paediatric Rheumatism and systemic autoimmune diseases (RAISE) who received JAKis between July 2017 and January 2020. Inclusion criteria were: (i) diagnosis of JDM, according to conventional clinico-pathological criteria [7] (ii) treatment with JAKis (iii) follow-up of at least 6 months after the initiation of JAKis. Patients were assessed according to a standardized protocol. Muscle strength was assessed using the Childhood Myositis Assessment Scale (CMAS, range 0–52) and the Manual Muscle Testing (MMT) scale (range 0–80) and skin disease activity using the skin Disease Activity Score tool (skin DAS, range 0–9). Severe muscle involvement was defined by CMAS score  $\leq 15$  or MMT score  $\leq 30$ . Clinically inactive disease (CID) was defined by both the Paediatric Rheumatology International Trials Organisation (PRINTO) remission criteria [8] (at least three out of four of

the following criteria have to be met: creatine kinase  $\leq 150$  U/L, CMAS  $\geq 48$ , MMT  $\geq 78$ , and Physician VAS  $\leq 0.2$ ) and inactive skin Disease Activity Score (DAS) (score  $\leq 1/9$  without cutaneous ulcerations or erythema) within 6 months after JAKi introduction. Partial response was defined as an improvement of the muscle and/or skin score assessed by MMT/CMAS and skin DAS, respectively, allowing a significant tapering of steroids dosage of at least 50% of the initial dosage at 6 months after JAKi introduction, without adding a new immunosuppressive drugs. The outcome was the proportion of patients achieving a complete or partial response within the six months following the onset of JAKis. Myositis-specific-antibodies (MSA) and myositis-associated (MMA) were assessed by dot-blot immunoassay using Euroline Autoimmune Inflammatory Myopathies 16 Ag (Euroimmun) and Blue Diver PMS12-24 (D-Tek). Muscle biopsies (MB) were centrally reviewed (C.G.) using the validated score tool for muscle biopsy evaluation in patients with JDM [9]. Interferon- $\alpha$  protein concentration was measured by SIMOA assay (Quanterix Homebrew) as previously described [10]. All the adverse events were recorded. Comparisons between baseline and last follow-up visit steroid dose and serum IFN- $\alpha$  level between patients that achieved CID and those who did not were made using the Wilcoxon rank-sum test (GraphPad 7.0). A p-value  $< 0.05$  was considered statistically significant. Informed parental consents were obtained for the use of JAKis on a compassionate basis and for the collection of biological samples. This study was approved by the French data protection agency.

Ten patients were included, comprising one previously reported patient [3]. Demographic, clinical, immunological and pathological manifestations at diagnosis are shown in the **Table**. Based on drugs availability, patients received either ruxolitinib (n=7) or baricitinib (n=3) (both JAK1/2 selective inhibitors) on a compassionate basis. The main indications for treatment were refractory muscle involvement (n=9) and/or ulcerative skin disease (n=2). One anti-MDA5-positive patient with JDM with severe skin ulcerations and polyarthritis received baricitinib as a first line treatment in association with corticosteroids

(P4). No patient had interstitial lung disease (ILD). Median time from diagnosis to JAKi initiation was 7 months (range 2-40). At the introduction of JAKi, the nine refractory patients with JDM had previously received a median of 3 immunosuppressive drugs (range, 0-6). In addition to treatment with JAKi, patients also received corticosteroids (n=10), plasma exchange (PEX) or immunoadsorption (IA) (n=5) and/or intravenous immunoglobulins (IVIG) (n=6). Clinical inactive disease was achieved in 5/10 patients, ranging from 1.7 to 6 months after JAKi initiation (**Figure 1A-1D**). It was sustained at last follow-up after a median duration of JAKi of 15 months (range 8-35) (**Table**). The daily steroid dose decreased from a median dosage of 1.1 mg/Kg/day at JAKi introduction (range 0.35-2 mg/Kg/d) at JAKi introduction to 0.1 mg/kg/day (range, 0-0.3,  $p=0.009$  at 6 months in complete responders (**Figure 1E**). All other treatments including immunosuppressive drugs, IVIG and PEX/IA were withdrawn within six months in the five responders. Among the five remaining patients, two additional patients (P6, P7) met the criteria of partial response at 6 months. However, JAKi had to be removed at the last follow-up (**Table**), because of a severe muscle relapse at 11 months and insufficient efficacy respectively. Three patients (P8, P9 and P10) were non responder because either a severe muscle relapse after a short transient partial improvement (P8, P9) or worsening of the JDM without any improvement (P10) respectively. Calcinosis developed in P1 and partially regressed in P2. Muscle biopsy was repeated in P1, 51 months after the first MB and 26 months after the introduction of ruxolitinib and showed the complete restoration of endomysial microvascular bed (total score: 5, vascular score 0), the normalization of MHC-I immunostaining (likely reflecting the deactivation of type I-IFN signaling), myofibers appearing negative unlike capillaries, and only very mild sequelae lesions: myofiber size irregularity, rounded appearance and centronucleation of myofibers, mild endomysial fibrosis, without inflammatory infiltrates, necrosis/regeneration or myosinolysis (**Supplemental material, Figure S1**). Clinically inactive disease was observed in the two anti-MDA5, 3/4 anti-NXP2 patients and none of the anti-TIF1 $\gamma$  positive patients.

Both high and low muscle total activity and vascular score were demonstrated on complete responders (**Table**). The highest histological connective tissue score (endomysial and perimysial fibrosis) was observed in two patients who did not reach CID with a long-lasting JDM. Serum IFN- $\alpha$  concentration was measured in all the patients before the initiation of JAKis. It was elevated in all of them (median 109 fg/mL, range 30-31328) before the initiation of JAKis (median 109 fg/mL, range 30-31328) and decreased in all the eight patients tested to 4.5 fg/mL (range, 0-216) at the last follow-up (**Figure 1F**). It normalized (<10 fg/mL) in four of the five patients with CID (median time from JAKi introduction 2.5 months; range, 1.6-14) (**Supplemental material, Figure S1**). The two anti-MDA5 positive patient had the highest concentration at baseline (3350 and 31328 fg/mL) compared to anti-MDA5-negative patients (median 76 fg/mL, range 30-495) (**Figure 1F**). Median serum IFN- $\alpha$  concentration at JAKi introduction did not significantly differ between patient with CID (333 fg/mL) and others (82 fg/mL) ( $p=0,41$ ).

Seven infections occurred in four patients. Three patients had herpes zoster infection which required hospitalization in one patient. Two patients with skin ulcerations developed *staphylococcus aureus* skin abscesses associated with a psoas abscess in one of them. All of them continued the JAKis therapy. Two patients had growth retardation which resolved on JAKis (P3 and P7).

In this retrospective study, JAKis treatment associated with corticosteroids led to CID within 6 months in 5/10 patients with severe JDM, including one new-onset anti-MDA5 positive patient. The rational of the use of their inhibitors (JAKis) is supported by type I IFN-regulated genes (IRG) upregulation in peripheral blood, muscle, skin and endothelial cells and elevated serum IFN- $\alpha$  in serum of DM and patient with JDM, which has been shown to correlate with DM and JDM activity [11, 12]. The efficacy of either JAK1/2 (ruxolitinib, baricitinib) or JAK1/3 (tofacitinib) inhibitors has been previously reported in about 50 DM



patients, mostly with anti-MDA5 or anti-TIF1- $\gamma$  refractory skin, muscle, joint involvement [2, 13-17] and/or refractory rapidly progressive ILD [18]. In JDM, responses to baricitinib, ruxolitinib and tofacitinib have been reported in seven anti-MDA5 and anti-TIF1 $\gamma$  positive patients with refractory muscle, skin, and/or interstitial lung disease [4-6], and in one patient of the present study [3]. JDM is heterogeneous regarding clinical phenotype, association with myositis-specific autoantibodies (MSAs), pathological stigmata and response to treatment. Interestingly, in our study, complete responders comprised one new-onset anti-MDA5 as well as refractory JDM positive for anti-MDA5 or anti-NXP2 antibodies. Anti-MDA5 antibodies are associated with 1) a distinct clinical phenotype of JDM characterized by skin ulceration resulting from vasculopathy, oral ulceration, arthritis and milder muscle disease, 2) a higher serum IFN $\alpha$  levels 3) a peripheral and skin IRG upregulation compared to other JDM subtypes a higher serum IFN $\alpha$  levels, and a peripheral and skin IRG upregulation compared to other JDM subtypes [18]. These findings and our study suggest that IFN $\alpha$  might represent an appropriate therapeutic target in this specific subgroup, as a first or second line treatment. The remaining three long-lasting responders to JAKis were anti-NXP2 patients who presented with a severe subtype of JDM, associating a severe muscle weakness and severe muscle ischemia [19]. In one of these patients with complete response, we showed the complete restoration of endomysial microvascular bed and the normalization of MHC-I immunostaining, which likely reflects the deactivation of type I-IFN signaling. These features confirm the *in vivo* effects of IFN-I on muscle endothelial cells (ECs) angiogenesis [2]. During severe JDM vasculopathy, myogenic progenitor cells derived from muscle taken from patients with JDM are one of cellular sources of type I IFN which drives an antiangiogenic response in ECs [20]. Altogether, these data and our series suggest that JAKis may have beneficial effects in patients with JDM with severe muscle vasculopathy, especially in the case of anti-NXP2 positivity, before the occurrence of irreversible muscle damages. Overall, targeting the IFN $\alpha$  pathway with JAKis might reverse severe JDM vasculopathy either in

muscle (anti-NXP2 positivity) or skin (anti-MDA5 positivity). Conversely to some reports of patients with DM and JDM (4, 15, 16), none of our two TIF- $\gamma$  positive patients achieved a CID. However, the small size of our cohort makes difficult to draw definitive conclusion about the efficacy of JAKi among each subsets of MSA-positive patients. Both responder and non-responder patients had elevated serum IFN- $\alpha$  levels prior treatment. Thus, the identification of biomarkers which may predict the response to JAKis is warranted.

Treatment of calcinosis remains challenging, and the efficacy of JAKi for treating this complication is unclear. Improvement or stabilization of calcinosis were reported in two DM and three patients with JDM [4, 5, 21]. Both progression and partial regression were observed in our series.

Treatment with JAKis was overall well tolerated. Consistent with studies from adult rheumatoid arthritis patients, we observed a high rate of herpes zoster infection. Most infections were mild or moderate in severity and did not result in drug discontinuation.

Our study has limitations as a retrospective study with a limited sample size, and in terms of the observation period and sampling inequality. In particular, the lack of some clinical data did not allow us to use the validated juvenile dermatomyositis PRINTO levels of improvement [22]. Moreover, a cumulative effect of previous rituximab may have increased efficacy of JAKis. However, given that 1) the last infusion of rituximab was performed more than 2 months before starting JAKis in three of the four complete responders who received rituximab, 2) three of the four patients with complete response that received Rituximab treatment prior to JAKi normalized their B cell count while maintaining CID (**Supplemental material, Figure S2**), the likelihood of an effect of the combined treatments is small at least in these patients. Finally, this study did not allow us to assess the respective efficacy of the two different JAKis used. One strength of this first series of patients with JDM treated with JAKis is the homogeneous way of follow-up by the same medical team.

In conclusion, JAKis resulted in a CID. in a subset of new-onset and refractory patients with JDM, especially in a subset of anti-MDA5 and anti-NXP2 positive patients. Overall tolerance was good except for a high rate of non-severe herpes zoster infection. Prospective multicenter trials are needed to identify predictive factors of response to JAKis in new-onset or refractory patients with JDM.

**Acknowledgments:** DD thanks Immunoqure for provision of the mAbs under an MTA for the SIMOA IFN- $\alpha$  assay

**Funding Source:** None

**Financial Disclosure:**

BBM has received financial support to attend congress from Novartis and has participated as a co-investigator in clinical trials by AbbVie, Bristol-Meyers Squibb, Lilly, Novartis, Novimmune, Pfizer, Roche and Sanofi.

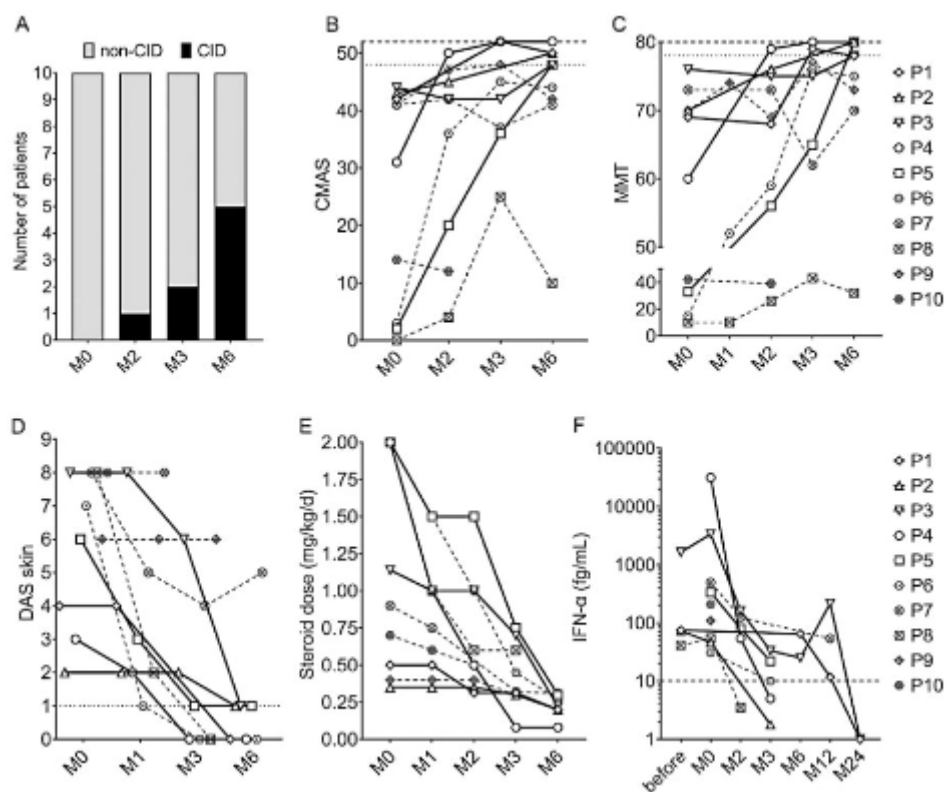
P.Q. has received consultancy or speakers fees from AbbVie, Chugai-Roche, Lilly, Novartis, Novimmune, Pfizer, Roche, Sanofi and Sweedish Orphan Biovitrum (Sobi) and invitation or financial support to attend congress from AbbVie, Bristol-Meyers Squibb, Novartis, Pfizer, Roche and Sobi. P.Q. takes part in two data safety monitoring boards for Sanofi and has participated as an investigator in clinical trials by AbbVie, Bristol-Meyers Squibb, Lilly, Novartis, Novimmune, Pfizer, Roche and Sanofi. The other authors have no financial disclosure.

**Conflict of Interest:** The authors have no conflicts of interest to disclose

**References:**

1. Ruperto N, Pistorio A, Oliveira S, Zulian F, Cuttica R, Ravelli A, et al. Prednisone versus prednisone plus ciclosporin versus prednisone plus methotrexate in new-onset juvenile dermatomyositis: a randomised trial. *Lancet* 2016;387:671–678.
2. Ladislau L, Suárez-Calvet X, Toquet S, Landon-Cardinal O, Amelin D, Depp M, et al. JAK inhibitor improves type I interferon induced damage: proof of concept in dermatomyositis. *Brain* 2018;141:1609–1621.
3. Aeschlimann FA, Frémond M-L, Duffy D, Rice GI, Charuel J-L, Bondet V, et al. A child with severe juvenile dermatomyositis treated with ruxolitinib. *Brain* 2018;141:e80–e80.
4. Papadopoulou C, Hong Y, Omoyinmi E, Brogan PA, Eleftheriou D. Janus kinase 1/2 inhibition with baricitinib in the treatment of juvenile dermatomyositis. *Brain* 2019;142:e8–e8.
5. Sabbagh S, Almeida de Jesus A, Hwang S, Kuehn HS, Kim H, Jung L, et al. Treatment of anti-MDA5 autoantibody-positive juvenile dermatomyositis using tofacitinib. *Brain* 2019 142:e59.
6. Kim H, Dill S, O'Brien M, Vian L, Li X, Manukyan M, Jain M, Adejo LW, George J, Perez M, Grom AA, Sutter M, Feldman BM, Yao L, Millwood M, Brundidge A, Pichard DC, Cowen EW, Shi Y, Lu S, Tsai WL, Gadina M, Rider LG, Colbert RA. Janus kinase (JAK) inhibition with baricitinib in refractory juvenile dermatomyositis. *Ann Rheum Dis*. 2020 Aug 2
7. Brown VE, Pilkington CA, Feldman BM, Davidson JE. An international consensus survey of the diagnostic criteria for juvenile dermatomyositis (JDM). *Rheumatology* 2006; 45: 990–3
8. Lazarevic D, Pistorio A, Palmisani E, Miettunen P, Ravelli A, Pilkington C, et al. The PRINTO criteria for clinically inactive disease in juvenile dermatomyositis. *Ann Rheum Dis* 2013;72:686–693.
9. Wedderburn LR, Varsani H, Li CK et al. International consensus on a proposed score system for muscle biopsy evaluation in patients with juvenile dermatomyositis: a tool for potential use in clinical trials. *Arthritis Rheum*. 2007;57:1192-201.
10. Rodero MP, Decalf J, Bondet V, Hunt D, Rice GI, Werneke S, et al. Detection of interferon alpha protein reveals differential levels and cellular sources in disease. *J Exp Med* 2017;214:1547–1555.
11. Greenberg SA, Pinkus JL, Pinkus GS, Burleson T, Sanoudou D, Tawil R, et al. Interferon-alpha/beta-mediated innate immune mechanisms in dermatomyositis. *Ann Neurol* 2005; 57: 664–78.
12. Melki I, Devilliers H, Gitiaux C, et al. Circulating Interferon- $\alpha$  Measured With a Highly Sensitive Assay as a Biomarker for Juvenile Inflammatory Myositis Activity: Comment on the Article by Mathian et al. *Arthritis Rheumatol* 2020 Jan;72:195-197
13. Hornung T, Janzen V, Heidgen F-J, Wolf D, Bieber T, Wenzel J. Remission of Recalcitrant Dermatomyositis Treated with Ruxolitinib. *N Engl J Med* 2014; 371: 2537–8
14. Kurtzman DJB, Wright NA, Lin J, Femia AN, Merola JF, Patel M, et al. Tofacitinib Citrate for Refractory Cutaneous Dermatomyositis: An Alternative Treatment. *JAMA Dermatol* 2016; 152: 944–5.
15. Paik JJ, Christopher-Stine L. A case of refractory dermatomyositis responsive to tofacitinib. *Semin Arthritis Rheum* 2017; 46: e19.
16. Moghadam-Kia S, Charlton D, Aggarwal R, Oddis CV. Management of refractory cutaneous dermatomyositis: potential role of Janus kinase inhibition with tofacitinib. *Rheumatology* 2019; 58: 1011–5.
17. Kurasawa K, Arai S, Namiki Y, Tanaka A, Takamura Y, Owada T, et al. Tofacitinib for refractory interstitial lung diseases in anti-melanoma differentiation-associated 5

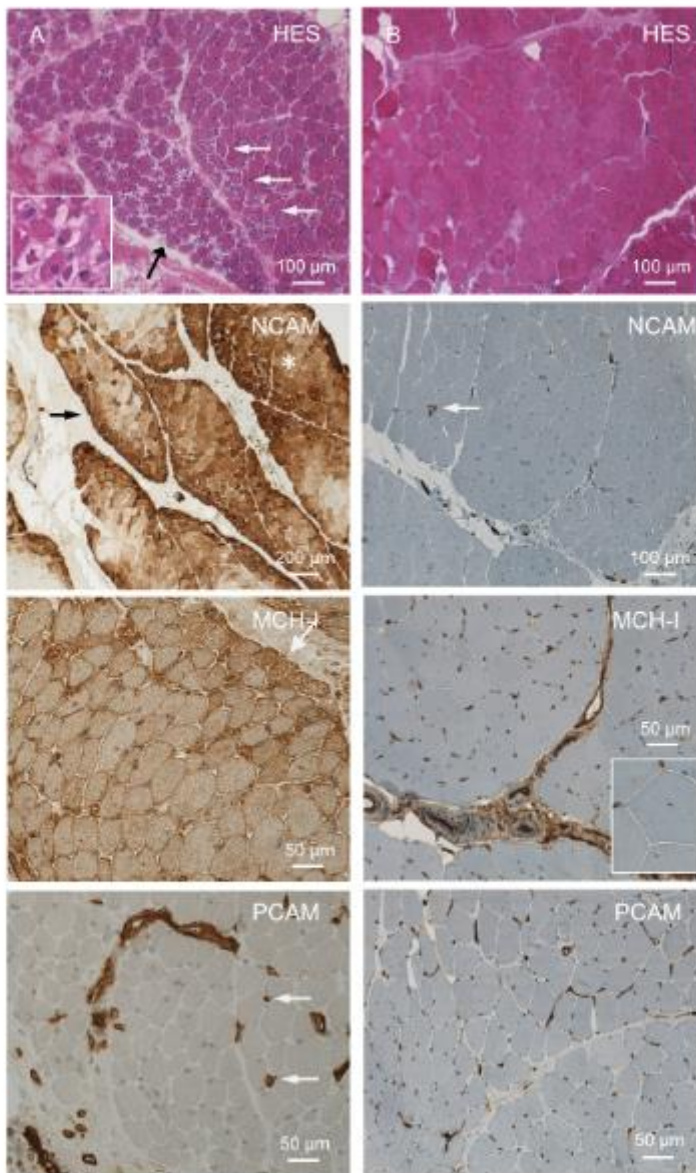
- gene antibody-positive dermatomyositis. *Rheumatology* 2018; 57: 2114–9.
18. Melki I, Devilliers H, Gitiaux C, Bondet V, Duffy D, Charuel J-L, et al. Anti-MDA5 juvenile idiopathic inflammatory myopathy: a specific subgroup defined by differentially enhanced interferon- $\alpha$  signalling. *Rheumatology* 2019; 72:195-197.
  19. Aouizerate J, De Antonio M, Bader-Meunier B, Barnerias C, Bodemer C, Isapof A, et al. Muscle ischaemia associated with NXP2 autoantibodies: a severe subtype of juvenile dermatomyositis. *Rheumatology* 2018;57:873–879.
  20. 15. Gitiaux C, Latroche C, Weiss-Gayet M, Rodero MP, Duffy D, Bader-Meunier B, et al. Myogenic Progenitor Cells Exhibit Type I Interferon–Driven Proangiogenic Properties and Molecular Signature During Juvenile Dermatomyositis. *Arthritis Rheumatol* 2018;70:134–145.
  21. Wendel S, Venhoff N, Frye BC, May AM, Agarwal P, Rizzi M, et al. Successful treatment of extensive calcifications and acute pulmonary involvement in dermatomyositis with the Janus-Kinase inhibitor tofacitinib – A report of two cases. *J Autoimmun* 2019;100:131–136.
  22. Rider LG, Aggarwal R, Machado PM, Hogrel J-Y, Reed AM, Christopher-Stine L, et al. Update on outcome assessment in myositis. *Nat Rev Rheumatol*. 2018;14(5):303–318.



### LEGENDS OF FIGURES

**Figure. Change in disease activity in ten patients with JDM on JAKis treatment. A:** Proportion of the ten patients with JDM achieving CID within six months at different follow-up times under JAKis. **B:** Increase of CMAS score [0-52]; **C:** Increase of MMT score [0-80]; **D:** Decrease of DAS skin score [0-9]; **E:** Decrease of median daily steroid dose.; **F:** Decrease of serum IFN- $\alpha$  level. Continuous line represents patients that achieved CID and dotted line patients that did not achieve CID within six months

Supplementary Figure S1



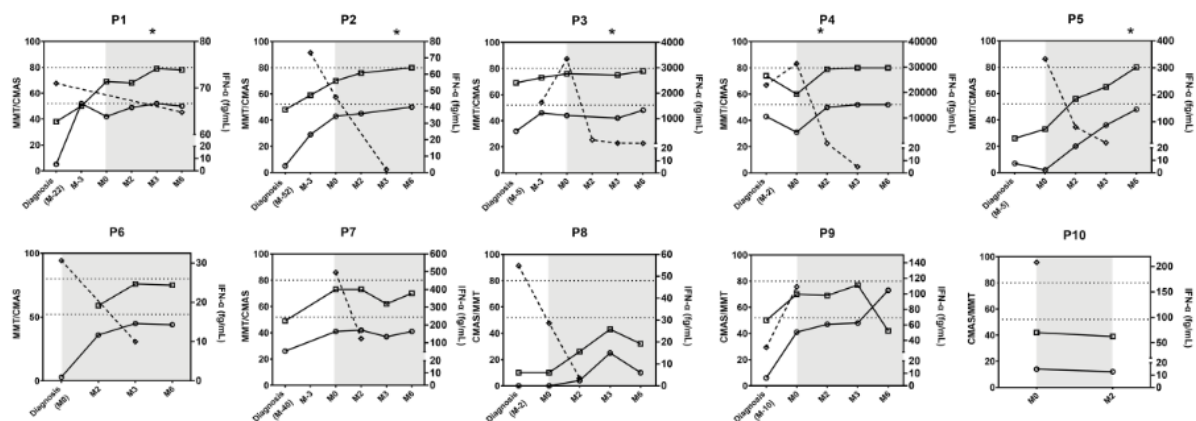
**Supplemental material Figure S1.** Changes in muscle biopsy features on ruxolitinib in Patient 1.

A Pathological features at JDM diagnosis : HES: severe ischemic myopathy with a numerous grouped injured myofibres within the same fascicle (black arrow) and perifascicular atrophy (white arrows), insert shows myofibres with punch-out vacuoles of myosinolysis at high magnification; NCAM: extensive abnormal myofibre re-expression of NCAM witnessing the intensity of muscle suffering with the typical pattern of JDM combining areas of grouped diseased myofibers (star) and perifascicular reinforcement (arrow); NCAM: very few immunoreactive atrophic fibres (arrow); MCH-I: ubiquitous abnormal myofibre re-expression of major histocompatibility complex (MHC)-type I with perifascicular reinforcement (arrow); PECAM: massive endomysial capillary loss with only few remaining vessels (arrows).

B Pathological features 42 months later and after 22 months of JAKi treatment. HES: residual changes with myofibre size irregularity, rounded appearance and centronucleation of myofibres, and mild endomysial fibrosis. MHC-I: normalization of MHC-I immunostaining reflecting the deactivation of type I-interferon signaling, myofibres appearing negative unlike capillaries (insert: higher magnification). PECAM immunostaining showing the complete restoration of endomysial microvascular bed.



Supplementary Figure S2



**Supplemental material Figure S2. Clinical and biological evolution of the ten patients with JDM treated by JAKi.** Clinical assessment is shown with MMT (open square, range [0-80]), CMAS (open circle, range [0-52]). Serum IFN- $\alpha$  level by SIMOA is represented in bold. Time under JAKi treatment is shown in grey background. The star represents the onset of clinical inactive disease.