



HAL
open science

Emerging mould infections: Get prepared to meet unexpected fungi in your patient

Sarah Dellière, Olga Rivero-Menendez, Cécile Gautier, Dea Garcia-Hermoso, Ana Alastruey-Izquierdo, Alexandre Alanio

► To cite this version:

Sarah Dellière, Olga Rivero-Menendez, Cécile Gautier, Dea Garcia-Hermoso, Ana Alastruey-Izquierdo, et al.. Emerging mould infections: Get prepared to meet unexpected fungi in your patient. *Medical Mycology*, 2020, 58 (2), pp.156-162. 10.1093/mmy/myz039 . pasteur-03223966

HAL Id: pasteur-03223966

<https://pasteur.hal.science/pasteur-03223966v1>

Submitted on 11 May 2021

HAL is a multi-disciplinary open access archive for the deposit and dissemination of scientific research documents, whether they are published or not. The documents may come from teaching and research institutions in France or abroad, or from public or private research centers.


L'archive ouverte pluridisciplinaire **HAL**, est destinée au dépôt et à la diffusion de documents scientifiques de niveau recherche, publiés ou non, émanant des établissements d'enseignement et de recherche français ou étrangers, des laboratoires publics ou privés.

Copyright



Review Article

Emerging mould infections: Get prepared to meet unexpected fungi in your patient

Sarah Dellière¹, Olga Rivero-Menendez², Cécile Gautier³, Dea Garcia-Hermoso³, Ana Alastruey-Izquierdo ² and Alexandre Alanio ^{1,3,4,*}

¹Université de Paris, Laboratoire de Parasitologie-Mycologie, AP-HP, Groupe Hospitalier Saint-Louis-Lariboisière-Fernand-Widal, Paris, France, ²Mycology Reference Laboratory, National Centre for Microbiology, Instituto de Salud Carlos III, Majadahonda, Madrid, Spain, ³Institut Pasteur, Molecular Mycology Unit, CNRS UMR2000, National Reference Center for Invasive Mycoses and Antifungals (NRCMA), Paris, France and ⁴Department of Molecular Microbiology and Immunology, Johns Hopkins Bloomberg School of Public Health, Johns Hopkins University, Baltimore, Maryland, USA

*To whom correspondence should be addressed. Alexandre Alanio, MD, PhD, Molecular Mycology unit, Institut Pasteur, 25 rue du Dr Roux 75724 Paris Cedex 15. Tel: +33140613255; Fax: +33145688420; E-mail: alexandre.alanio@pasteur.fr

Received 18 December 2018; Revised 1 March 2019; Accepted 5 April 2019; Editorial Decision 29 March 2019

Abstract

Invasive fungal diseases are increasing issues in modern medicine, where the human immunodeficiency virus (HIV) pandemic and the wider use of immunosuppressive drugs generate an ever-growing number of immunocompromised patients with an increased susceptibility to uncommon fungal pathogens. In the past decade, new species have been reported as being responsible for disseminated and invasive fungal diseases in humans. Among them, the following genera are rare but seem emerging issues: *Scopulariopsis*, *Hormographiella*, *Emergomyces*, *Westerdykella*, *Trametes*, *Actinomucor*, *Saksenaee*, *Apophysomyces*, and *Rhizoglyphus*. Delay in diagnosis, which is often the case in these infections, jeopardizes patients' prognosis and leads to increased mortality. Here we summarize the clinical and biological presentation and the key features to identify these emerging pathogens and we discuss the available antifungal classes to treat them. We focused on Pubmed to recover extensively reported human invasive cases and articles regarding the nine previously cited fungal organisms. Information concerning patient background, macroscopic and microscopic description and pictures of these fungal organisms, histological features in tissues, findings with commonly used antigen tests in practice, and hints on potential efficient antifungal classes were gathered. This review's purpose is to help clinical microbiologists and physicians to suspect, identify, diagnose, and treat newly encountered fungi in hospital settings.

Key words: invasive fungal disease, emerging fungi, *Emergomyces*, *Scopulariopsis*, *Hormographiella*, *Actinomucor*, *Apophysomyces*, *Rhizoglyphus*, *Saksenaee*, *Trametes*, *Westerdykella*.

Introduction

Invasive fungal infections (IFIs) are increasing due to the growing use of immunosuppressive chemotherapy and the persistence of the AIDS pandemic in specific areas. In addition, the improvement of diagnostic means may concur to that trend. *Candida* spp. and *Cryptococcus* spp. are the most frequent isolated yeasts in human IFIs, while *Aspergillus* spp., *Fusarium* spp.

and *Scedosporium* spp. are the most isolated moulds.¹ However, the part attributed to other fungal organisms is increasing and emerging uncommon species responsible for IFIs are more frequently described around the world. In this review, we describe unusual emerging moulds responsible for IFIs with a focus on the fungus—morphology, environmental niche, location, mode of transmission—and on the infection (clinical presentation and treatments available). These genera and species were selected

for their scarcity and their recent emergence during the past two decades.

Actinomucor spp.

The genus *Actinomucor* belongs to the order *Mucorales* and is commonly isolated from soil, from the rhizosphere of plants and from mouse and rabbit dung.² *Actinomucor elegans* is involved in traditional fermentation of sufu, a cheese-like soybean very common in Asia.³ The only species of the genus *Actinomucor* is *Actinomucor elegans*, divided in var. *elegans*, var. *kuwaitiensis*, and var. *taiwanensis*, considered synonyms (<http://www.indexfungorum.org>). *A. elegans* has white to cream floccose cultures growing rapidly at 30°C. Microscopically they are verticillately branched sporangiophores with terminate sporangia in various lengths. The smooth or spiny sporangia wall encloses spherical to ovoidal sporangiospores.⁴ Sequencing of the ITS1-5.8S-ITS2 region of rDNA is currently used to identify accurately species of this genus.

Only five cases of superficial and invasive mucormycosis involving *Actinomucor* have been described in the literature since 2001. Two cases were associated with maxillary sinusitis in an immunocompetent 11-year-old female⁵ and in an allogeneic transplant patient with a lymphoblastic lymphoma;⁶ a third case was a necrotic foot lesion in a diabetic patient.⁷ Disseminated infection was diagnosed in two cases following a trauma during combat in Iran⁸ and in a diabetic patient with refractory aplastic anemia.⁹ Out of five patients, two were cured with surgery debridement and amphotericin B administration,^{5,6} two died despite debridement and broad spectrum antifungal,^{8,9} and one was lost to follow-up.⁷

Apophysomyces mexicanus

Among the subphylum *Mucoromycotina*, the *Apophysomyces* species complex¹⁰ encompasses five species: *A. elegans*, *A. variabilis*, *A. trapeziformis*, *A. ossiformis*, and the most recently proposed *A. mexicanus*.¹¹ The members of this complex are mainly soil thermophilic microorganisms with tropical to subtropical distribution and have been implicated in cases of human mucormycosis mainly in immunocompetent individuals.^{12,13} The most common clinical presentations are cutaneous and subcutaneous localizations following trauma, burn, invasive procedures or natural disasters.¹⁴ In the reported case of *A. mexicanus*, patient presented with a necrotizing fasciitis rapidly spreading despite the administration of amphotericin B and fluconazole followed by an extensive surgical debridement. Diagnosis was achieved by identifying coenocytic hyphae during the histopathological examination of the necrotic tissue and the growth of a whitish fungal colony characteristic of mucoralean fungi. The species of *Apophysomyces* produce fast-growing white to gray colonies and genus specific morpholog-

ical features such as the prominent bell-shaped, vase-shaped or funnel-shaped apophyses. While smooth walled sporangiophores (including the apophyse) are a common feature of this genus, the verrucose texture of the wall in *A. mexicanus* constitutes its distinctive characteristic.¹¹ A molecular approach with the amplification of the ITS1-5.8S-ITS2 region of rDNA is required to assure definite species-level identification. The biggest case series of *Apophysomyces* sp. reports 13 cases after cutaneous injury during a tornado in Missouri in May 2011.¹⁵ Five patients (38%) died, however; a focus on patients treated appropriately according to guidelines (i.e., amphotericin B in combination with surgical debridement)¹⁶ shows a treatment efficiency of 85% with only two deaths.¹⁵

Saksenaia erythrospora

Among the subphylum *Mucoromycotina* the genus *Saksenaia* comprises three species: *S. vasiformis* species complex, *S. erythrospora* and *S. oblongispora*.¹⁰ These cosmopolitan mucoralean organisms produce white-gray expanding colonies with a maximum temperature of 44°C. Sporulation may be promoted by subculturing the fungus on water agar 1% or Czapek medium at 30° to 37°C.⁴ The multispored flask-shaped sporangium is characteristic of the genus. Species recognition is based mainly on differences in length of sporangiophores and sporangia; shape and size of sporangiophores and maximum growth temperatures. Accurate species identification also relies on sequencing of the ITS1-5.8S-ITS2 region and the D1-D2 domains of the large-subunit ribosomal DNA. Mucormycosis due to *Saksenaia* spp. have been mostly associated with cutaneous infections in healthy and immunocompetent subjects following traumatic implantation with soil and water contamination, inhalation of spores, insect stings, or the use of indwelling catheters.^{17,18} Up to now, nine cases of the newly described species *S. erythrospora* have been reported. The majority of infections were observed in immunocompetent individuals (except for one diabetic patient)¹⁹ and were associated with trauma (sailing accident, combat trauma, intramuscular injection or application of medicated adhesive tape),¹⁹⁻²¹ medical tourism activities (esthetic surgery) or invasive rhinosinusitis.^{22,23} Clinical presentations included necrotic or ulcerative skin and soft tissue lesions, necrotizing fasciitis, or orbital cellulitis. No specific management has been recommended in recent guidelines for *Saksenaia* sp. compared to other mucormycosis. As first line therapy, a combination of surgical debridement when feasible and the administration of a lipid formulation of amphotericin B, which offers a better chance of survival to the patient, have been recommended.^{16,24}

Hormographiella aspergillata

H. aspergillata is the asexual form of *Coprinopsis cinerea*, a common basidiomycete found in compost.²⁵ This fungus has been

Table 1. Macroscopic and microscopic features of emerging fungal species in IFIs.

Genus	Macroscopic aspect in culture		Microscopic aspect in culture		Microscopic aspect in tissue	
	Description	Image	Description	Image	Description	Image
<i>Actinomicor spp.</i>	White to cream floccose colonies	Fig. 1A	Verticillately branched sporangiophores; smooth or spiny sporangia	Fig. 1B	Intravasculaire and parenchymal invasive, ribbon-like, branching fungal elements characteristics of the member of <i>Mucorales</i> species	8,9
<i>Apophysomyces mexicanus</i>	White to gray rapid growing colonies	ND	Verrucose-walled sporangiophores and apophyse	11	Wide coenocytic mycelia	11
<i>Saksenaea erythrospora</i>	White to gray expanding colonies	19,21	Multispored flask-shaped sporangium	Fig. 1F	Broad aseptate hyphae with wide angle branching	19,21
<i>Hormographiella aspergillata</i>	White to cream cotton-like colonies	27,28	Septate conidiophores/clusters of smooth-walled hyaline and cylindrical arthroconidia	27,28	Hyaline hyphae with acute branching Necrotic tissue	27,28
<i>Trametes polyzona</i>	White and cottony colonies	31	Hyaline septate hyphae and rectangular arthroconidia	30	Septate fungal hyphae Neutrophil tissue infiltration	31
<i>Emergomyces africanus</i>	Mycelial phase (25–30°C) Light brown wrinkled colony with powdery segment Yeast phase (37°C) Smooth cream-to-beige color colony	Fig. 1C	Mycelial phase: Septate hyaline hyphae with numerous smooth-walled oval conidia borne on thin pedicles. Yeast phase: Small thin-walled, globose-to-oval yeasts (2–4 µm in diameter)	Fig. 1D	Round to ovoid yeasts with single budding nuclei and thin walls simulating <i>Histoplasma capsulatum</i>	54
<i>Rhizidhysterion rufulum</i>	Dark green to grey velvety colonies	Fig. 1E	Septate irregularly branched dematiaceous hyphae Ascomata apothecioid, Ascospores transversely 3-septate, with no longitudinal septa	39,41	Thick-walled brown, spherical, sclerotic bodies with or without septation	39,41
<i>Scopulariopsis (Microascus) spp.</i>	Powdery pale brown colonies	Fig. 1G	Septate hyphae, annellidic conidiogenous cells in chains and smooth or rough-walled subglobose conidia with a flattened base.	Fig. 1H	Irregularly shaped hyphae with swollen thick-walled structure Angioinvasive Necrotic tissue formation May be melanized	43,45
<i>Westerdykella dispersa</i>	Dark-brown colonies with dark globose cleistothecium	Fig. 1I	Reddish-brown, smooth, cylindrical to slightly reniform ascospores Pycnidia with ostioles and subglobose to pyriform, hyaline conidia	Fig. 1J Fig. 1K	septate hyphal angioinvasive	48

ND, not described.

reported in 15 cases in the past two decades and majorly arises in neutropenic patients who underwent allogeneic stem cell transplantation as part of acute leukemia treatment.^{26,27} Clinical presentation is an invasive pulmonary infection in all cases but one has been described to disseminate to the central nervous system (CNS), eyes, skin, sinuses, and blood (endocarditis).²⁸ Diagnosis is driven by the presence of nodular infiltrates and the halo sign on pulmonary computed tomography (CT). Galactomannan is constantly negative and bronchoalveolar lavage (BAL) is always negative Table (2).²⁹ Thoracoscopic surgery and lung biopsy allowed to have final diagnosis in all cases allowing the growth

of *H. aspergillata* in all cases in which it was performed.^{26,29} The morphological characteristics of the fungus are described in Table 1. This fungus responds poorly to all antifungal and mortality rate of all cases published is 73%.^{25,26} *In vitro* susceptibility shows intrinsic resistance to echinocandins and variable minimal inhibitory concentration (MIC) to second generation azoles and amphotericin B (AmB), but these data cannot be translated into clinical practice without caution. The addition of nebulized liposomal-AmB (L-AmB) to IV L-AmB is the treatment combination that showed the best improvement of a patient condition so far.²⁶

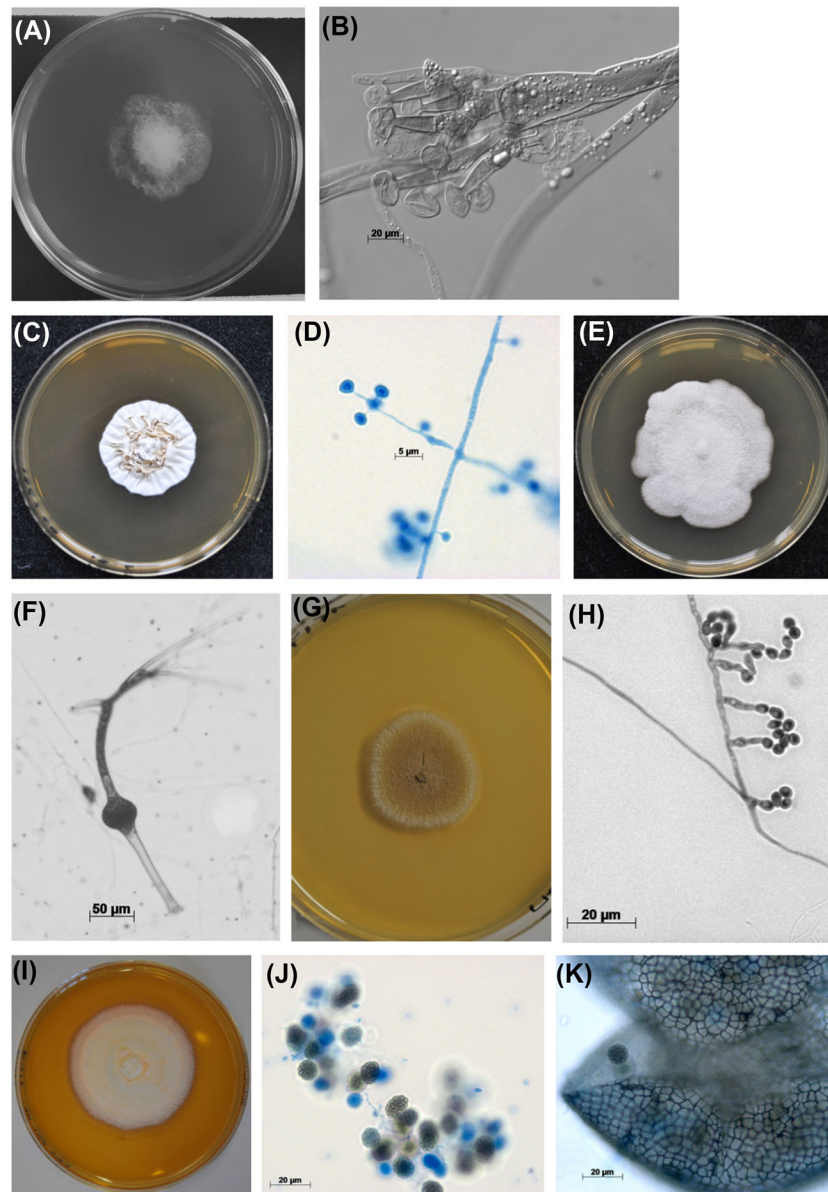


Figure 1. *Actinomucor elegans* (A) floccose colony on MEA 2% after 3 days of incubation at 30°C (B) microscopic aspect of sporangiophores terminating in columellae. *Emergomycetes africanus* (C) restricted colony on MEA 2% after 10 days at 24°C (D) microscopy of slide culture on MEA 2% after 7 days at 24°C; solitary conidiophores and subspherical conidia. *Rhytidhysteron rufulum* (E) velvety colony on MEA 2% after 15 days at 21°C. *Saksenaëa erythrospora* (F) sporangiophore, flask-shaped sporangia and rhizoids after 15 days on Czapek agar at 30°C. *Scopulariopsis brevicaulis* (G) brown powdery colony on MEA 2% after 10 days at 30°C. *Microascus cirrosus* (H) annelated conidiophores and conidia after 7 days on MEA 2% at 30°C. *Westerdykella dispersa* (I) expanding colony on MEA 2% after 7 days at 30°C (J) reddish brown cylindrical ascospores (K) dark globose cleistothecium and reddish brown cylindrical ascospores. MEA2%: Malt extract agar 2%.

Trametes polyzona

Trametes polyzona is a basidiomycete that belongs to the order *Polyporales*. It is a saprotrophic fungus that has been isolated in Africa, South and Central America, and Asia being particularly prevalent in tropical countries and playing a major role as a decomposer in the tropical forest ecosystem.³⁰ The first report in human infections was in 2016 from two cases of pneumonia³¹ in Reunion island. Patients suffered from chronic debilitating

diseases that lead to fungal colonization of the respiratory tract. They were initially treated with caspofungin or fluconazole and later with liposomal amphotericin B. Histopathological confirmation was obtained in one case. The isolates recovered from both cases did not sporulate in standard culture and were identified by sequencing informative targets. Antifungal susceptibility testing revealed low MICs (<0.5 mg/l) to amphotericin B and azoles but high MICs (>8 mg/l) for caspofungin and terbinafine.

Table 2. Results of routinely used biological fungal markers in invasive fungal disease of emergent fungi.

	β-D-glucan Number of positive patient (n)	GM serum Number of positive patient (n)	GM BAL Number of positive patient (n)	Urine Histoplasma Ag Number of positive patient (n)	Reference
<i>Actinomyces</i> spp.	NA	1 (1)	NA	NA	6
<i>Apothysomyces mexicanus</i>	NA	NA	NA	NA	
<i>Saksanae erythrospora</i>	NA	NA	NA	NA	
<i>Hormographiella aspergillata</i>	0 (1)	0 (7)	0 (4)	NA	26-29
<i>Trametes polyzona</i>	NA	NA	NA	NA	
<i>Emergomyces africanus</i>	NA	NA	NA	3 (10)	54
<i>Rhytidhysterion rufulum</i>	NA*	NA**	NA	NA	
<i>Scopulariopsis (Microascus) spp.</i>	0 (1)	0 (2)	0 (1)	NA	45,55
<i>Westerdykella dispersa</i>	NA	0 (1)	NA	NA	48

Ag, antigen; BAL, broncho-alveolar lavage; GM, galactomannan; NA, no assessment.

*1(1) in an unpublished case in 2018; **0 (1) in an unpublished case in 2018.

Emergomyces spp.

For more than 50 years, the genus *Emmonsia* was known to cause a rare disease called adiaspiromycosis.³² While the incidence of adiaspiromycosis does not seem to increase, an outbreak of *Emmonsia*-like fungi has been causing severe disseminated infection in South African human immunodeficiency virus (HIV) patients in the past 10 years.³³ Considering that these fungi do not produce adiaspores in tissue, display thermal dimorphism and generate disseminated disease in immunocompromised patients, a new genus called *Emergomyces* has been proposed supported by molecular investigations.³⁴ *Emergomyces* accommodates former *Emmonsia pasteuriana*, and the new species *Emergomyces africanus* responsible for the South African outbreak³⁴ and *Emergomyces orientalis* only described in a case in China.³⁵ *Emergomyces pasteuriana*, ex-*Emmonsia pasteuriana*, has been reported in five cases since 1998,³⁶ while *E. africanus* has been responsible for at least 86 reported cases in South Africa since 2008.³⁵ Both present as disseminated infections with skin lesions in AIDS patients with a CD4 cell count <100/mm³. Clinical presentation of *E. africanus*, whose infection has been recently well described, associates fever, weight loss, anemia, and widespread nonspecific skin lesions from erythematous papules to ulcers and crusted plaques. Infection is fatal in about 30% of cases.^{33,35} Dissemination is documented by lesions on chest X-ray resembling tuberculosis and elevated liver enzymes. Culture of skin biopsy isolates the fungus in all cases, whose characteristics are described in Table 1. Isolation of the fungus from blood or bone marrow is significantly associated with death.³⁵ Despite the lack of guidelines on the management of emergomycosis,

the fungus seems to respond well and rapidly to amphotericin B deoxycholate for 14 days followed by itraconazole maintenance therapy.^{33,35}

Rhytidhysterion rufulum

Rhytidhysterion rufulum is a melanized ascomycete genus that has been recognized for many years as a plant pathogen. Recent molecular studies transferred the genus from *Patellariaceae* to the *Hysteriaceae* family.³⁷ *Rhytidhysterion rufulum* was first isolated from a human infection in 2009 in a case of chromoblastomycosis in India.³⁸ Seven more phaeophycomycosis cases have been described in the literature since then.³⁸⁻⁴² Five were immunocompetent patients, one renal transplant and two diabetic patients. Diagnosis was always based on the isolation of the fungus and sequencing since the isolates do not sporulate in culture. All cases were found in the lower limbs. Patient's treatment included itraconazole alone or in combination with terbinafine and/or lesion excision. One case was also treated with amphotericin B in addition to lesion excision, itraconazole and terbinafine.³⁹ Four of the cases got cured, one (chromoblastomycosis) did not, and three patients were lost to follow-up.

Scopulariopsis (Microascus) spp.

The ascomyceteous genus *Scopulariopsis* includes hyaline and melanized species that are ubiquitous and found in soil, air, wood, dung, and animal remains.⁴³ Most common species involved in human pathogenicity are *Scopulariopsis brevicaulis*, *Scopulariopsis gracilis*, *Scopulariopsis brumptii* (recently

renamed as *Microascus gracilis* and *Microascus paisii* respectively), *Scopulariopsis candida*, *Microascus cirrosus* and *Microascus cinereus*.⁴³ They are occasionally involved in human infections ranging from superficial infections (onychomycosis, keratitis, otomycosis) to invasive infections with high mortality rates. The latter include endocarditis, sinusitis, brain abscess, pulmonary, deep cutaneous and disseminated cases with poor outcome, mostly seen in immunocompromised patients.⁴³ *Scopulariopsis* spp. grows well on routine laboratory media and are recovered and identified easily from clinical samples (Table 1). Fungal biological markers are also usually negative in disseminated infection (Table 2). Infections by *Scopulariopsis* spp. lack recommendation guidelines related to high *in vitro* MICs (minimum inhibitory concentrations) to all current antifungal agents.⁴⁴ Furthermore, many cases report discrepancies between MIC *in vitro* and clinical response suggesting that some antifungals, mainly amphotericin B and voriconazole, may be active in patients, as observed in fusariosis with voriconazole.^{44,45} Surgery combined with antifungal is usually advised to give patients the highest chance of survival.^{44,45}

Westerdykella dispersa

Westerdykella spp. are saprobic fungi with a worldwide distribution. It belongs to the family *Sporomiaceae* (order *Pleosporales*). It has been described as the causative agent of systemic infection in dogs.⁴⁶ Two cases of human infections have been reported until now.^{47,48} Sue et al. reported the infection in a neutropenic patient with acute lymphoblastic leukemia.⁴⁸ Infectious complication around a peripherally inserted central catheter occurred. The patient was successfully treated with a combination of voriconazole and liposomal amphotericin B in addition to repeated debridements. The second case was isolated from a critically burned patient.⁴⁷ Three other isolates were recovered from lower extremity wounds or tissue in the United States identified as *Westerdykella*, one of them as *W. dispersa* and the other two as *W. reniformis*.⁴⁸ However, their virulence in these cases has not been acknowledged.

Discussion

New mould species are increasingly reported as responsible for IFs in humans. Some belong to newly described genus such as *Emergomyces* spp., but some are well-known fungi never encountered in human disease before like *H. aspergillata*. On one hand, the use of antifungal therapy necessarily gives rise to the emergence of naturally resistant species. In addition, antifungal prophylaxis with azoles in at-risk patients has been shown to select for resistant species such as Mucorales or *Scopulariopsis* spp.^{49,50} In patients empirically treated with echinocandins, the most common antifungal class for the treatment of candidemia, invasive mould infection may also arise.²⁷ New classes of antifungals are needed to treat and prevent these naturally resistant

emerging species in immunocompromised patients. On the other hand, introduction and improvement of biomolecular techniques to identify mould and yeast species may create a reporting bias, since these techniques, following recommendations on fungal barcoding, are able to detect more species that are misidentified by classical methods previously used.^{51,52}

In the light of new diagnostic methods, including fungal biomarkers and polymerase chain reaction (PCR) techniques, microscopic identification skills tend to be overlooked. However, a thorough direct examination of patient samples not only can catch and orientate towards a fungal group (yeast, hyalohyphomycetes, Mucorales) but also remains the fastest result to help initiate early treatment as a mean to improve prognosis. Furthermore, a direct observation of fungal elements in tissue is a strong evidence to prove an invasive fungal infection according to the EORTC criteria.⁵³ Considering that infections by emerging fungi are difficult cases to diagnose, they may therefore be under reported.

Acknowledgments

We thank Françoise Dromer and Stéphane Bretagne for their continuous support.

Declaration of interest

The authors report no conflicts of interest. The authors alone are responsible for the content and the writing of the paper.

References

- Vallabhaneni S, Mody RK, Walker T, Chiller T. The global burden of fungal diseases. *Infect Dis Clin N Am*. 2016; 30: 1–11.
- Karimi K, Arzanlou M, Ahari AB, Ghazi MM. Phenotypic and molecular characterization of the causal agent of chafer beetle mortality in the wheat fields of the Kurdistan province, Iran. *J Plant Protect Res*. 2015; 55: 227–234.
- Han B-Z, Kuijpers AFA, Thanh NV, Nout MJR. Mucoraceous moulds involved in the commercial fermentation of Sufu Pehtze. *Antonie van Leeuwenhoek*. 2004; 85: 253–257.
- Garcia-Hermoso D, Dromer F, Alanio A, Lortholary O. Agents of systemic and subcutaneous mucormycosis and entomophthoromycosis. In: *Manual of Clinical Microbiology*, 11th edn. Washington, DC: American Society of Microbiology, 2015: 2087–2108.
- Davel G, Featherston P, Fernandez A et al. Maxillary sinusitis caused by *Actinomyces elegans*. *J Clin Microbiol*. 2001; 39: 740–742.
- Dorin J, D'Aveni M, Debourgogne A et al. Update on *Actinomyces elegans*, a mucormycete infrequently detected in human specimens: how combined microbiological tools contribute efficiently to a more accurate medical care. *Int J Med Microbiol*. 2017; 307: 435–442.
- Khan ZU, Ahmad S, Mokaddas E, Chandy R, Cano J, Guarro J. *Actinomyces elegans* var. *kuwaitiensis* isolated from the wound of a diabetic patient. *Antonie van Leeuwenhoek*. 2008; 94: 343–352.
- Tully CC, Romanelli AM, Sutton DA, Wickes BL, Hospenthal DR. Fatal *Actinomyces elegans* var. *kuwaitiensis* infection following combat trauma. *J Clin Microbiol*. 2009; 47: 3394–3399.
- Mahmud A, Lee R, Munfus-McCray D et al. *Actinomyces elegans* as an emerging cause of mucormycosis. *J Clin Microbiol*. 2012; 50: 1092–1095.
- Alvarez E, Stchigel AM, Cano J et al. Molecular phylogenetic diversity of the emerging mucoralean fungus *Apophysomyces*: proposal of three new species. *Revista Iberoamericana de Micología*. 2010; 27: 80–89.

11. Bonifaz A, Stchigel AM, Guarro J et al. Primary cutaneous mucormycosis produced by the new species *Apophysomyces mexicanus*. *J Clin Microbiol*. 2014; 52: 4428–4431.
12. Garcia-Covarrubias L, Bartlett R, Barratt DM, Wassermann ARJ. Rhino-orbitocerebral mucormycosis attributable to *Apophysomyces elegans* in an immunocompetent individual: case report and review of the literature. *J Trauma*. 2001; 50: 353–357.
13. Chakrabarti A, Shivaprakash MR, Curfs-Breuker I, Baghela A, Klaassen CH, Meis JF. *Apophysomyces elegans*: epidemiology, amplified fragment length polymorphism typing, and in vitro antifungal susceptibility pattern. *J Clin Microbiol*. 2010; 48: 4580–4585.
14. Gomes MZR, Lewis RE, Kontoyiannis DP. Mucormycosis caused by unusual mucormycetes, non-*Rhizopus*, -*Mucor*, and -*Lichtheimia* species. *Clin Microbiol Rev*. 2011; 24: 411–445.
15. Neblett-Fanfair R, Benedict K, Bos J et al. Necrotizing cutaneous mucormycosis after a tornado in Joplin, Missouri, in 2011. *N Engl J Med*. 2012; 367: 2214–2225.
16. Cornely OA, Arikan-Akdagli S, Dannaoui E et al. ESCMID† and ECMML‡ joint clinical guidelines for the diagnosis and management of mucormycosis 2013. *Clin Microbiol Infect*. 2014; 20: 5–26.
17. Chakrabarti A, Kumar P, Padhye AA et al. Primary cutaneous zygomycosis due to *Saksenaia vasiformis* and *Apophysomyces elegans*. *Clin Infect Dis*. 1997; 24: 580–582.
18. Spellberg B, Edwards J, Ibrahim A. Novel perspectives on mucormycosis: pathophysiology, presentation, and management. *Clin Microbiol Rev*. 2005; 18: 556–569.
19. Chander J, Singla N, Kaur M et al. *Saksenaia erythrospora*, an emerging mucoralean fungus causing severe necrotizing skin and soft tissue infections: a study from a tertiary care hospital in north India. *Infect Dis*. 2016; 49: 170–177.
20. Relloso S, Romano V, Landaburu MF et al. *Saksenaia erythrospora* infection following a serious sailing accident. *J Med Microbiol*. 2014; 63: 317–321.
21. Hospenhal DR, Chung KK, Laird K et al. *Saksenaia erythrospora* infection following combat trauma. *J Clin Microbiol*. 2011; 49: 3707–3709.
22. Rodríguez JY, Rodríguez GJ, Morales-López SE, Cantillo CE, Le Pape P, Álvarez-Moreno CA. *Saksenaia erythrospora* infection after medical tourism for esthetic breast augmentation surgery. *Int J Infect Dis*. 2016; 49: 107–110.
23. Bradoo R, Baveja S, Tendolkar U et al. Rhinosinusitis caused by *Saksenaia erythrospora* in an immunocompetent patient in India: a first report. *JMM Case Reports*. 2015; 2: 4410.
24. Lortholary O, Fernández-Ruiz M, Perfect JR. The current treatment landscape: other fungal diseases (cryptococcosis, fusariosis and mucormycosis). *J Antimicrob Chemother*. 2016; 71: ii31–ii36.
25. Chowdhary A, Kathuria S, Agarwal K, Meis JF. Recognizing filamentous basidiomycetes as agents of human disease: a review. *Med Mycol*. 2014; 52: 782–797.
26. Godet C, Cateau E, Rammaert B et al. Nebulized liposomal amphotericin B for treatment of pulmonary infection caused by *Hormoglyphiella aspergillata*: case report and literature review. *Mycopathologia*. 2017; 182: 709–713.
27. Suarez F, Olivier G, Garcia-Hermoso D et al. Breakthrough *Hormoglyphiella aspergillata* infections arising in neutropenic patients treated empirically with caspofungin. *J Clin Microbiol*. 2010; 49: 461–465.
28. Nanno S, Nakane T, Okamura H et al. Disseminated *Hormoglyphiella aspergillata* infection with involvement of the lung, brain, and small intestine following allogeneic hematopoietic stem cell transplantation: case report and literature review. *Transplant Infect Dis*. 2016; 18: 611–616.
29. Conen A, Weisser M, Hohler D, Frei R, Stern M. *Hormoglyphiella aspergillata*: an emerging mould in acute leukaemia patients? *Clin Microbiol Infect*. 2011; 17: 273–277.
30. Zmitrovich IV, Ezhov ON, Wasser SP. A survey of species of genus *Trametes* fr. (higher Basidiomycetes) with estimation of their medicinal source potential. *Int J Med Mushrooms*. 2012; 14: 307–319.
31. Gauthier A, Jaubert J, Traversier N et al. *Trametes polyzona*, an emerging filamentous basidiomycete in Réunion Island. *Mycoses*. 2017; 60: 412–415.
32. Schwartz IS, Kenyon C, Feng P et al. 50 Years of *Emmonsia* disease in humans: the dramatic emergence of a cluster of novel fungal pathogens. *PLoS Pathogens*. 2015; 11: e1005198–e1005198.
33. Kenyon C, Bonorchis K, Corcoran C et al. A dimorphic fungus causing disseminated infection in South Africa. *N Engl J Med*. 2013; 369: 1416–1424.
34. Dukik K, Muñoz JF, Jiang Y et al. Novel taxa of thermally dimorphic systemic pathogens in the *Ajellomycetaceae* (Onygenales). *Mycoses*. 2017; 60: 296–309.
35. Maphanga TG, Britz E, Zulu TG et al. In vitro antifungal susceptibility of yeast and mold phases of isolates of dimorphic fungal pathogen *Emergomyces africanus* (formerly *Emmonsia* sp.) from HIV-infected South African patients. *J Clin Microbiol*. 2017; 55: 1812–1820.
36. Malik R, Capoor MR, Vanidassane I et al. Disseminated *Emmonsia pasteuriana* infection in India: a case report and a review. *Mycoses*. 2015; 59: 127–132.
37. Boehm EWA, Mugambi GK, Miller AN et al. A molecular phylogenetic reappraisal of the *Hysteriaceae*, *Mytiliniaceae* and *Gloniaceae* (*Pleosporomycetidae*, *Dothideomycetes*) with keys to world species. *Stud Mycol*. 2009; 64: 49–83.
38. Chowdhary A, Guarro J, Randhawa HS et al. A rare case of chromoblastomycosis in a renal transplant recipient caused by a non-sporulating species of *Rhytidhysterion*. *Med Mycol*. 2008; 46: 163–166.
39. Mahajan VK, Sharma V, Prabha N et al. A rare case of subcutaneous phaeoerythromycosis caused by a *Rhytidhysterion* species: a clinico-therapeutic experience. *Int J Dermatol*. 2014; 53: 1485–1489.
40. Mishra K, Das S, Goyal S et al. Subcutaneous mycoses caused by *Rhytidhysterion* species in an immunocompetent patient. *Med Mycol Case Rep*. 2014; 5: 32–34.
41. Chander J, Singla N, Kundu R, Handa U, Chowdhary A. Phaeoerythromycosis caused by *Rhytidhysterion rufulum* and review of literature. *Mycopathologia*. 2016; 182: 1–5.
42. Mudhigeti N, Patnayak R, Kalawat U, Yeddula SRC. Subcutaneous *Rhytidhysterion* infection: a case report from South India with literature review. *Cureus*. 2018; 10: 1–9.
43. Iwen PC, Schutte SD, Florescu DF, Noel-Hurst RK, Sigler L. Invasive *Scopulariopsis brevicaulis* infection in an immunocompromised patient and review of prior cases caused by *Scopulariopsis* and *Microascus* species. *Med Mycol*. 2012; 50: 561–569.
44. Paredes K, Capilla J, Mayayo E, Guarro J. Virulence and resistance to antifungal therapies of *Scopulariopsis* species. *Antimicrob Agents Chemother*. 2016; 60: 2063–2068.
45. Gavril D, Woerther P-L, Ben Lakhdar A et al. Invasive cutaneous infection due to *Scopulariopsis brevicaulis* unsuccessfully treated with high-dose micafungin in a neutropenic patient. *Infection*. 2017; 45: 361–363.
46. Armentano RA, American KCJOT. 2013. Disseminated mycotic infection caused by *Westerdykella* species in a German Shepherd dog. *Am Vet Med Assoc*. 2013; 242: 381–387.
47. Lipovy B, Kocmanova I, Holoubek J et al. The first isolation of *Westerdykella dispersa* in a critically burned patient. *Folia Microbiol*. 2018; 63: 1–4.
48. Sue PK, Gurda GT, Lee R et al. First report of *Westerdykella dispersa* as a cause of an angioinvasive fungal infection in a neutropenic host. *J Clin Microbiol*. 2014; 52: 4407–4411.
49. Lamoth F, Chung SJ, Damonti L, Alexander BD. Changing epidemiology of invasive mold infections in patients receiving azole prophylaxis. *Clin Infect Dis*. 2017; 64: 1619–1621.
50. Danion F, Aguilar C, Catherinot E et al. Mucormycosis: new developments into a persistently devastating infection. *Semin Respir Crit Care Med*. 2015; 36: 692–705.
51. Schoch CL, Seifert KA, Huhndorf S et al. Nuclear ribosomal internal transcribed spacer (ITS) region as a universal DNA barcode marker for Fungi. *Proc Natl Acad Sci U S A*. 2012; 109: 6241–6246.
52. Stielow JB, Lévesque CA, Seifert KA et al. One fungus, which genes? Development and assessment of universal primers for potential secondary fungal DNA barcodes. *Pers - Int Mycol J*. 2015; 35: 242–263.
53. De Pauw B, Walsh TJ, Donnelly JP et al. Revised definitions of invasive fungal disease from the European organization for research and treatment of cancer/invasive fungal infections cooperative group and the national institute of allergy and infectious diseases Mycoses Study Group (EORTC/MSG) Consensus Group. *Clin Infect Dis*. 2008; 46: 1813–1821.
54. Schwartz IS, Kenyon C, Lehloeny R et al. AIDS-related endemic mycoses in Western Cape, South Africa, and clinical mimics: a cross-sectional study of adults with advanced HIV and recent-onset, widespread skin lesions. *Open Forum Infect Dis*. 2017; 4: ofx186.
55. Rose SR, Vallabhajosyula S, Velez MG et al. The utility of bronchoalveolar lavage beta-D-glucan testing for the diagnosis of invasive fungal infections. *J Infect*. 2014; 69: 278–283.