



**HAL**  
open science

## **Invasive Infections with *Nannizziopsis obscura* Species Complex in 9 Patients from West Africa, France, 2004–20201**

Dea Garcia-Hermoso, Samia Hamane, Arnaud Fekkar, Arnaud Jabet, Blandine Denis, Martin Siguier, Guy Galeazzi, Elie Haddad, Sophie Brun, Valérie Vidal, et al.

► **To cite this version:**

Dea Garcia-Hermoso, Samia Hamane, Arnaud Fekkar, Arnaud Jabet, Blandine Denis, et al.. Invasive Infections with *Nannizziopsis obscura* Species Complex in 9 Patients from West Africa, France, 2004–20201. *Emerging Infectious Diseases*, 2020, 26 (9), 10.3201/eid2609.200276 . pasteur-03222568

**HAL Id: pasteur-03222568**

**<https://pasteur.hal.science/pasteur-03222568>**

Submitted on 10 May 2021

**HAL** is a multi-disciplinary open access archive for the deposit and dissemination of scientific research documents, whether they are published or not. The documents may come from teaching and research institutions in France or abroad, or from public or private research centers.

L'archive ouverte pluridisciplinaire **HAL**, est destinée au dépôt et à la diffusion de documents scientifiques de niveau recherche, publiés ou non, émanant des établissements d'enseignement et de recherche français ou étrangers, des laboratoires publics ou privés.



Distributed under a Creative Commons Attribution 4.0 International License

# Invasive Infections with *Nannizziopsis obscura* Species Complex in 9 Patients from West Africa, France, 2004–2020<sup>1</sup>

Dea Garcia-Hermoso, Samia Hamane, Arnaud Fekkar, Arnaud Jabet, Blandine Denis, Martin Siguier, Guy Galeazzi, Elie Haddad, Sophie Brun, Valérie Vidal, Gilles Nevez, Rozenn Le Berre, Maud Gits-Muselli, Fanny Lanternier, Stéphane Bretagne

## Medscape EDUCATION ACTIVITY

In support of improving patient care, this activity has been planned and implemented by Medscape, LLC and Emerging Infectious Diseases. Medscape, LLC is jointly accredited by the Accreditation Council for Continuing Medical Education (ACCME), the Accreditation Council for Pharmacy Education (ACPE), and the American Nurses Credentialing Center (ANCC), to provide continuing education for the healthcare team.

Medscape, LLC designates this Journal-based CME activity for a maximum of 1.00 **AMA PRA Category 1 Credit(s)**<sup>™</sup>. Physicians should claim only the credit commensurate with the extent of their participation in the activity.

Successful completion of this CME activity, which includes participation in the evaluation component, enables the participant to earn up to 1.0 MOC points in the American Board of Internal Medicine's (ABIM) Maintenance of Certification (MOC) program. Participants will earn MOC points equivalent to the amount of CME credits claimed for the activity. It is the CME activity provider's responsibility to submit participant completion information to ACCME for the purpose of granting ABIM MOC credit.

All other clinicians completing this activity will be issued a certificate of participation. To participate in this journal CME activity: (1) review the learning objectives and author disclosures; (2) study the education content; (3) take the post-test with a 75% minimum passing score and complete the evaluation at <http://www.medscape.org/journal/eid>; and (4) view/print certificate. For CME questions, see page 2307.

**Release date: August 14, 2020; Expiration date: August 14, 2021**

### Learning Objectives

Upon completion of this activity, participants will be able to:

- Assess the clinical features of invasive fungal infection with *N. obscura* species complex, based on a series of 9 new confirmed human cases from 2004 to 2020
- Evaluate the microbiological features of invasive fungal infection with *N. obscura* species complex, based on a series of 9 new confirmed human cases from 2004 to 2020
- Determine the clinical implications of features of invasive fungal infection with *N. obscura* species complex, based on a series of 9 new confirmed human cases from 2004 to 2020

### CME Editor

**Jude Rutledge, BA**, Technical Writer/Editor, Emerging Infectious Diseases. *Disclosure: Jude Rutledge has disclosed no relevant financial relationships.*

### CME Author

**Laurie Barclay, MD**, freelance writer and reviewer, Medscape, LLC. *Disclosure: Laurie Barclay, MD, has disclosed no relevant financial relationships.*

### Authors

*Disclosures: Dea Garcia-Hermoso, PhD; Samia Hamane, MD; Arnaud Jabet, MS; Blandine Denis, MD, PhD; Guy Galeazzi, MD; Elie Haddad, MD; Sophie Brun, MD, PhD; Valérie Vidal, MD; Gilles Nevez, MD, PhD; Rozenn Le Berre, MD, PhD; Maud Gits-Muselli, MD; Fanny Lanternier, MD, PhD; and Stéphane Bretagne, MD, PhD, have disclosed no relevant financial relationships. Arnaud Fekkar, PharmD, PhD, has disclosed the following relevant financial relationships: served as a speaker or a member of a speakers bureau for Gilead; received grants for clinical research from Janssen. Martin Siguier, MD, has disclosed the following relevant financial relationships: served as an advisor or consultant for Viiv Healthcare; other (travel expenses reimbursement) from Gilead.*

Nine new human invasive infections caused by the keratinophilic fungi *Nannizziopsis obscura* have been reported in France since 2004. The patients had variable clinical manifestations, had frequent dissemination, were mainly T-cell immunocompromised, and all originated from sub-Saharan West Africa. Before collection of the isolates, the etiologies of these infections were often misidentified, underscoring the extent of microscopic and cultural polymorphisms. All isolates but 1 had low MICs for the 8 antifungal drugs tested. When treated, patients received mainly azole therapy. Two of 7 patients with a known outcome died. We performed multilocus sequence analysis of *N. obscura* clinical strains and several strains of *Nannizziopsis* spp. isolated from reptiles. The human strains were clearly differentiated from the animal strains. *N. obscura* might be endemic to West Africa and responsible for undetected infections, which might become reactivated when immunosuppression occurs. *N. obscura* infection is probably underestimated because only sequencing enables proper identification.

*Nannizziopsis* spp. are described as keratinophilic nascomycetous fungi that cause dermal infections with frequently fatal outcomes in various reptiles (e.g., lizards, geckos, chameleons, iguanas, snakes, and crocodiles), mainly in captivity (1,2). *Nannizziopsis* spp. belong to the order of *Onygenales* and the recently described family of *Nannizziopsidaceae* (1). In humans, invasive *Nannizziopsis* spp. infection seems rare; only 5 cases have been reported to date (1,3–7). Such an observation suggests an actual rarity, a recent emergence because of modification in the ecoepidemiology (e.g., new populations at risk [8]), or previous underdiagnoses or misdiagnoses because of a lack of definite identification.

We describe 9 human cases of invasive fungal infection with *N. obscura* species complex identified in France during 2004–2020 (Table 1, <https://wwwnc.cdc.gov/EID/article/26/9/20-0276-T1.htm>), along with the initial identification from the 5 reporting hospitals. Isolates were sent to France's National Reference Center for Invasive Mycoses and Antifungals, where a polyphasic identification combining phenotypic features and

molecular data was performed. Seven of the 9 cases were diagnosed after 2016.

### The Patients

Patient 1 was 49-year-old HIV-positive man from Mali who was hospitalized for a liver abscess discovered in August 2004 during a stay in Mali. He was afebrile but had advanced AIDS (zero CD4 cell/mm<sup>3</sup>). A liver needle aspiration showed hyphae with arthroconidia. The first identified colonies were *Trichosporon* spp., based on a positive urease test and presence of arthroconidia. The patient was given liposomal amphotericin B and metronidazole. After 15 days, the patient returned to Mali for personal reasons; no follow-up was possible. At that time, the organism had been identified as *Chrysosporium* spp.

Patient 2 was a 50-year-old man who came from Mali to undergo heart transplantation in January 2009 after 9 months of hospitalization for cardiac insufficiency. After transplantation, the patient had cytomegalovirus reactivation and multivisceral failure. One month later, he had onset of bacterial mediastinitis. He was surgically treated and received wide-spectrum antibiotics but no antifungals. The immunosuppressive therapy consisted of prednisone (15 mg/d) and ciclosporine. A serum sample was negative for *Aspergillus* galactomannan. Two months later (just 2 days before the death of the patient), a blood culture was positive, and the isolate was identified as *Geotrichum* spp. or *Chrysosporium* spp.

Patient 3 was a 58-year-old woman with diabetes who was from Mali but had been living in France for 30 years. In 2017, she reported a 2-week history of asthenia and chest pain without fever. She had renal transplantation in 2016 and was receiving tacrolimus, mycophenolate, and prednisone (5 mg/d). A computed tomography (CT) scan revealed an irregular lung nodule (14 mm in diameter). She received amoxicillin/clavulanic acid. Three months later, she had an abscess of the left thigh and multiple nodular skin lesions on both legs. A new CT scan showed an enlargement of the pulmonary nodule. Direct examination of the skin

Author affiliations: Institut Pasteur, Paris, France (D. Garcia-Hermoso, F. Lanternier, S. Bretagne); Hôpitaux Lariboisière–Saint-Louis-Fernand Widal, Assistance Publique–Hôpitaux de Paris, Paris (S. Hamane, A. Jabet, B. Denis, M. Siguier, M. Gits-Muselli, S. Bretagne); Groupe Hospitalier Pitié–Salpêtrière, Assistance Publique–Hôpitaux de Paris, Sorbonne Université, Paris (A. Fekkar); Hôpital Max Fourestier, Nanterre, France (G. Galeazzi); Centre Hospitalier Universitaire Hôtel-Dieu de France, Université de Saint-Joseph, Beirut, Lebanon (E. Haddad); Hôpital Avicenne, Assistance Publique–Hôpitaux de Paris, Bobigny, France (S. Brun,

V. Vidal); Hôpital La Cavale Blanche, Centre Hospitalier Universitaire de Brest, Brest, France (G. Nevez, R. Le Berre); Université Paris 13, Paris (S. Brun); Université de Paris, Paris (M. Gits-Muselli, F. Lanternier, S. Bretagne)

DOI: <https://doi.org/10.3201/eid2609.200276>

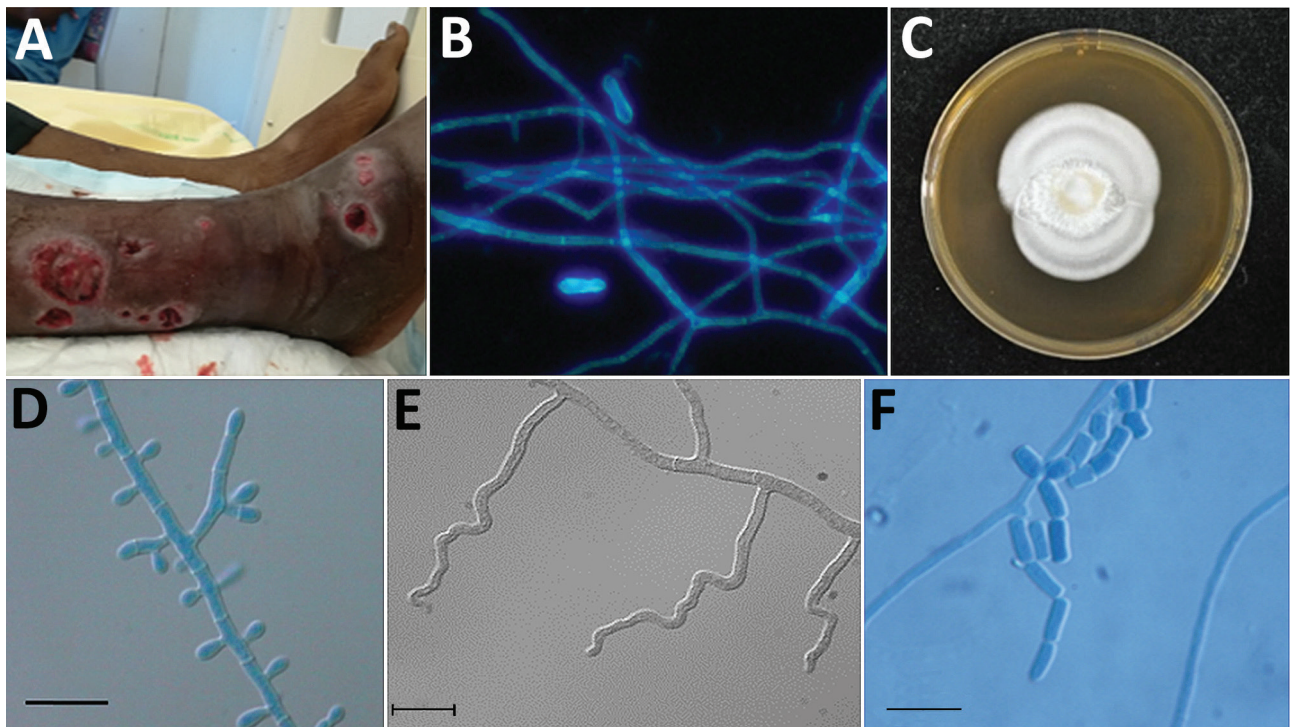
<sup>1</sup>Preliminary results of this study were presented at the International Society for Human and Animal Mycology, June 30–July 4, 2018, Amsterdam, the Netherlands (poster 174, Medical Mycology 56, Supplement 2).

and lung biopsies revealed septate and vesicular hyphae, and the culture resembled *Trichophyton* spp., which was eventually confirmed as *N. obscura* upon sequencing. Serum  $\beta$ -D-glucan was strongly positive ( $>500$  pg/mL, positivity threshold  $\geq 80$  pg/ml), and serum *Aspergillus* galactomannan antigen was repeatedly negative. A whole-body positron emission tomography (PET)-CT scan showed multiple clinically latent hypermetabolic lesions (in the nasal septum, left breast, and mediastinal nodes). Voriconazole was initiated, then switched to posaconazole after *N. obscura* identification. The dose of tacrolimus was reduced, and mycophenolate mofetil was replaced by azathioprine. At 6 months, a new PET-CT scan showed a residual hypermetabolic pulmonary lesion. Posaconazole was stopped after 8 months. No relapse had occurred as of 1 year later.

Patient 4 was a 62-year-old man from Guinea who had been living in France for 12 years (recent trip to Guinea occurred  $\approx 1$  year before). He was hospitalized in July 2017 for several suppurated lesions on the right fibula (Figure 1, panel A) that were unresponsive to amoxicillin/clavulanic acid treatment. He had undergone renal transplantation in 2009 for hypertensive nephropathy and received mycophenolate mofetil, tacrolimus, and prednisone (5 mg/d). A CT

scan confirmed tissue infiltration with small abscesses but showed no sign of bone involvement. Large-scale debridement was performed, and direct examination of infected tissues showed regular septate hyphae and arthroconidia (Figure 1, panel B). Yeast-like fungi appeared on Sabouraud-chloramphenicol-gentamycin slants. Microscopic examination showed arthroconidia, and the urease test was positive, suggesting the presence of *Trichosporon* spp. A whole-body PET-CT scan revealed asymptomatic hypermetabolic lesions in the contralateral leg and lung micronodules. Voriconazole was started when trichosporonosis was suspected and switched to posaconazole with the identification of *N. obscura*. Serum  $\beta$ -D-glucan was strongly positive ( $>500$  pg/mL), whereas *Aspergillus* galactomannan antigen detection was negative. At 6 months, a PET-CT scan showed residual hypermetabolism around the right ankle. Onychomycosis of the right toe was noted, and a specimen was taken. Direct examination showed hyphae, but the culture was negative. Posaconazole was maintained for 2 years, with tacrolimus and prednisone (5 mg/d). A new PET-CT scan showed no hypermetabolic lesion.

Patient 5 was a 69-year-old woman from Guinea-Bissau who had been living in France for 10 years (her most recent trip to Guinea-Bissau occurred in 2016).



**Figure 1.** Features of *Nannizziopsis obscura* infections in patients from West Africa, France 2004–2020. A) Ulcerative lesions. B) Septate hyphae and arthroconidia on a calcofluor white direct examination (original magnification  $\times 200$ ). C) Macroscopic aspect on Sabouraud dextrose agar at 7 days. D) Septate conidiophore bearing clavate and sessile conidia. E) Undulate hyphae. F) Barrel-shaped arthroconidia. Scale bars indicate 10  $\mu$ m.

She was admitted for the investigation of lung lesions. She had been treated for advanced mantle cell lymphoma in 2017, resulting in complete remission. In June 2018, a thoracic CT scan showed lymphadenopathy, lung nodules, and condensations treated with intravenous antibiotics and rituximab. In September 2018, disseminated nodular hyperchromic skin lesions appeared, and skin biopsies showed large septate hyphae with arthroconidia. A combination of voriconazole and liposomal amphotericin B was started for probable invasive mold infection. White mold colonies were observed after 5 days culture, and a presumptive identification of *Trichophyton* spp. was made. Terbinafine was added but was exchanged for voriconazole and liposomal amphotericin B when *N. obscura* was identified. Thirty days after admission, magnetic resonance imaging of the central nervous system showed diffuse, embolic-looking ischemia. Viral PCRs were negative in cerebrospinal fluid. Serum  $\beta$ -D-glucan was strongly positive ( $>500$  pg/mL), and serum galactomannan was negative. Liver biopsy confirmed adult T-cell lymphoma or leukemia associated with human T-cell lymphotropic virus type 1 positivity. The patient died 3 weeks after admission despite intensive care and antifungal treatment.

Patient 6 was a 27-year-old woman from Guinea who was breast-feeding. She had been living in France since September 2017 and was seen at a tuberculosis control center in October 2018. A chest radiograph showed a mediastinal mass, which was confirmed by a chest CT scan. The mass ( $7 \times 5 \times 5$  cm) invaded the left upper lobe, and thickening of the anterior arch of the second left rib was observed. She had no notable medical history. Pathologic examination of the surgically resected mediastinal mass showed hyphae inside an inflammatory and fibrous reaction invading the thymus, the brachiocephalic veins, the left upper lobe, and the chest wall. Serum  $\beta$ -D-glucan was positive (306 pg/mL). A first presumptive identification on culture was of *Trichophyton* spp. Posaconazole was started, then switched with voriconazole when *N. obscura* was identified. A reduction in mass size (from  $71 \times 39$  mm to  $62 \times 36$  mm) was observed on a CT scan after 7 months of treatment. The investigations of Card9 and Stat1 mutations, 2 genes known to be responsible for higher susceptibility to invasive fungal infections (9), showed wild type genotypes. Follow-up after that point was not possible.

Patient 7 was a 38-year-old man from Mali who was hospitalized for visual disturbance, retroorbital pain, and vomiting in September 2018. He had been living in France since 1990, making regular visits to relatives in Mali. He had undergone a renal transplant

in 2015 and was receiving mycophenolate mofetil, tacrolimus, and prednisone (5 mg/d). He had experienced an acute rejection in March 2018, which was treated by high-dose methylprednisone. A brain CT scan showed hypodense lesions with mass effect. Results of magnetic resonance imaging without injection supported the diagnosis of glioblastoma. A cerebral biopsy showed numerous branched hyphae. *Candida* spp. infection was suspected, and liposomal amphotericin B (5 mg/d) was started in combination with fluconazole IV (200 mg/d). The treatment resulted in an improvement of the visual disturbance, and a new magnetic resonance imaging result confirmed the reduction of the mass effect. Culture results were positive, and the final identification made was *Nannizziopsis* spp. Serum  $\beta$ -D-glucan was strongly positive ( $>500$  pg/mL), and serum galactomannan was negative. On October 9, fluconazole was switched for voriconazole, and the liposomal amphotericin B was maintained. Meanwhile, the patient experienced a chronic rejection of the graft, and hemodialysis was restarted on November 23. He was alive as of 12 months later.

Patient 8 was a 79-year-old man from Mali who had been living in France since 1963 (his most recent trip to Mali occurred in 2016). In August 2019, he sought care for an ulcerative lesion of the fifth right finger that had been evolving for several months. He had undergone a renal transplant in 2014 and was receiving mycophenolate mofetil, tacrolimus, and prednisone (5 mg/d). A pulmonary nodule was observed in 2017 and was only surveyed. Because of a recent increase in size (from 9 to 13 cm in diameter), a PET-CT scan was performed in April 2019 and showed multiple hypermetabolic pulmonary, abdominal, and muscular (left thigh) nodules. The pulmonary nodule was surgically removed in June 2019, and a necrotic abscess with hyphae was observed by the pathologist (no culture was performed). The evolution was indolent, although the patient had lost 10 kg in 6 months. In August 2019, a skin biopsy showed hyphae, and the culture was identified as *N. obscura* upon sequencing. Serum  $\beta$ -D-glucan was positive (255 pg/mL), and serum galactomannan was negative. Itraconazole was started in August 2019. The patient had been seen in July 2018 because of the same ulcerative lesion of his right hand. A swab specimen yielded a mold colony identified as *Trichophyton rubrum*, which was considered not clinically relevant. The identification of the stored isolate yielded *N. obscura*, which confirmed that the infection had been ongoing for  $\geq 1$  year. The patient was well as of 4 months after starting azole therapy.

Patient 9 was a 65-year-old man from Mali who had been living in France for >20 years. In December 2019, he sought care for a mass in front of the left clavicle that had appeared 6 months earlier during a stay in Bamako, Mali. The patient had undergone a renal transplant in 2018 and was receiving cyclosporine, tacrolimus, and prednisone (5 mg/d). A CT scan showed bone lysis of the clavicle with a subcutaneous abscess. A biopsy was performed, and the pathologist reported inflammation with hyphae. Spontaneous fistula occurred, yielding pus. *Nannizziopsis* sp. was identified in the culture. A PET-CT showed hypermetabolism of the left clavicle, and the presternal region extended to the manubrium along with hypermetabolism of a pulmonary nodule of the lingula. Serum  $\beta$ -D-glucan results were positive (>520 pg/mL). Treatment with voriconazole was started and a reappraisal scheduled after 12 weeks.

## Materials and Methods

### Morphologic Identification and Antifungal-Susceptibility Testing

Ten clinical isolates (2 isolates for patient 8) were checked for purity and subsequently subcultured on potato dextrose agar (PDA) (BD Diagnostic Systems, <https://www.bd.com>) and malt extract agar (MEA) 2% (Oxoid, <http://www.oxoid.com>) for 15 days at 30°C, 37°C, and 40°C to study fungal growth and sporulation. The type strain of *N. obscura* (isolate no. UAMH5875) was analyzed in parallel. Microscopic characteristics were examined on 5- to 7-day-old MEA slide cultures incubated at 30°C. Antifungal-susceptibility profiles were screened according to a slightly modified European Committee on Antimicrobial Susceptibility Testing procedure (10). All antifungal drugs were purchased from Alsachim (<https://www.alsachim.com>).

### Molecular Characterization and Phylogenetic Analysis

We performed DNA extraction and amplified fragments of the internal transcribed region (ITS), the D1-D2 region of the large subunit (LSU) ribosomal DNA, and the actin gene (11) (Appendix, <https://wwwnc.cdc.gov/EID/article/26/9/20-0276-App1.pdf>). We conducted a preliminary similarity searching using BLASTn (<https://blast.ncbi.nlm.nih.gov>) against curated fungal reference databases. We conducted multiple sequence alignments and single-gene phylogenies in MEGA7 (12). In addition to the clinical isolates and the type strain of *N. obscura*, we incorporated the corresponding sequences of *N. draconii*, *N. chlamydospora*, *N. guarroi*, *N. vriesii*, and *N. arthrosporioides*

that are published in GenBank (Appendix). *N. hominis* was not included because of the lack of LSU and actin sequences in the public databases. Phylogenetic analysis was done with a neighbor-joining method by using MEGA7 and with the maximum-likelihood method by using PhyML 3.0 (13) subjected to smart model selection at the NGPhylogeny integrative web service (<https://ngphylogeny.fr>) (14).

### Ethics Considerations

We obtained approval from the Commission Nationale de l'Informatique et des Libertés, the national data-protection agency in France (approval no. 903395). This step ensured that the patients' data were kept anonymous according to national regulations.

## Results

### Morphology

All clinical strains and the type strain grew well on PDA at 30°C and 37°C. No growth was observed at 40°C. Cultures on PDA and MEA at 30°C were white with low aerial mycelium and a velvety to powdery texture, rarely zonate, or heaped and with a yellowish coloring on the reverse (Figure 1, panel C). In general, microscopic observations showed the typical, although nonspecific, features of the genus *Nannizziopsis* (e.g., hyaline, septate, smooth-walled hyphae). All isolates produced sessile conidia and arthroconidia, and some produced short hyphal branches in a wavelike motion (undulate hyphae) (Figure 1, panels D-F) (5).

### Antifungal Susceptibility Testing

The MICs or minimal effective concentrations (MECs) of all 8 antifungals were low except for 1 strain. Median MICs were 0.25 mg/L (range 0.06–1 mg/L) for amphotericin B, 0.125 mg/L (range 0.014–4 mg/L) for itraconazole, 0.06 mg/L (range 0.03–2 mg/L) for voriconazole, 0.06 mg/L (range 0.014–2 mg/L) for posaconazole, 0.125 mg/L (range 0.06–2 mg/L) for isavuconazole, and 0.06 mg/L (range 0.014–0.5 mg/L) for terbinafine. Median MEC was 0.5 mg/L (range 0.25–1 mg/L) for caspofungin and 0.015 mg/L (range 0.015–0.06 mg/L) for micafungin.

### Molecular Characterization and Phylogenetic Analyses

Similarity comparisons in public databases showed that all isolates belong to the genus *Nannizziopsis* and had percentage identity ranges of 96.0%–99.8% (475 bp length) for LSU, 88.0%–99.0% (>700 bp length) for ITS, and 85.0%–98.7% (>500 bp length) for actin genes. *N. guarroi* (GenBank accession no. MH874904) had the highest number of hits for LSU, whereas *N. vriesii*

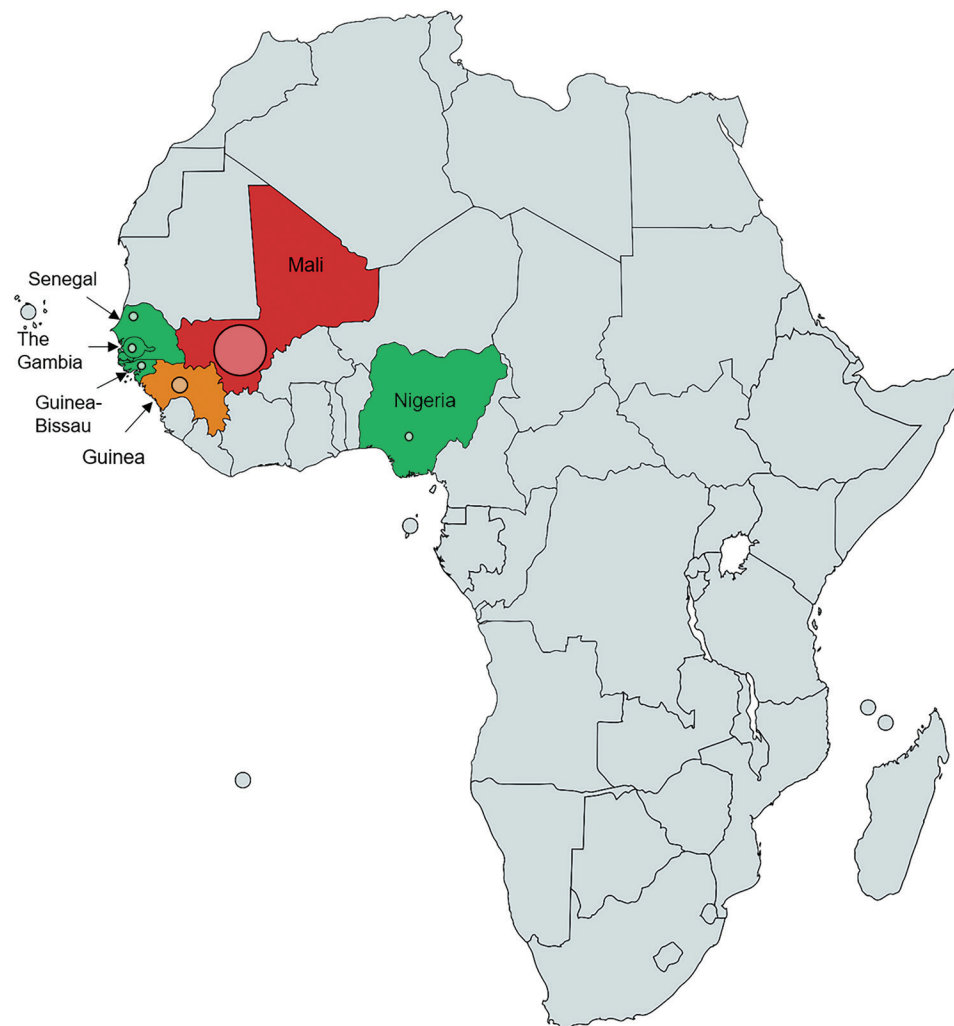

transplantation (8 patients) after 2006; the most frequent clinical localizations were subcutaneous tissues (8 patients) and lung (7 patients) (Tables 1, 2). For some patients, the infection manifested as disseminated disease with brain abscess, lung nodules, or positive blood culture (Tables 1, 2). The association of serum  $\beta$ -D-glucan positivity and galactomannan negativity (7 and 6 patients tested in the 9-patient series, respectively) seems a useful adjunct, albeit unspecific. As a consequence, the suspicion of *Nannizziopsis* spp. infection cannot rely on a specific clinical manifestation and requires a tissue biopsy.

Our molecular study places all 10 *N. obscura* isolates (including 2 recovered from patient 8) into a well-supported phylogenetic lineage, separate from reptile isolates (Figure 2). Recent taxonomic revisions for the former *Chrysosporium* anamorph of *N. vriesii* complex resulted in the assignment of several species within the genus *Nannizziopsis* or within the 2 new genera of *Paranannizziopsis* and *Ophiodiomyces*

(1,5). So far, only 2 species (*N. obscura* and *N. hominis*) have been definitely implicated in human pathology (3,5). The species *N. infrequens* was determined not to be responsible for an invasive infection and was disregarded by clinicians (16). Thus, *N. hominis* was reported in 3 patients before 2000, and *N. obscura* was reported in 4 patients after 2005 (5) and in 9 cases since then. *N. infrequens* and *N. hominis* exhibit good growth at 35°C, in contrast to the *Nannizziopsis* species implicated in reptile infections (5). Although our study clearly differentiates the human *N. obscura* isolates from our case series from the reptile isolates, the modest branch support value for the *N. obscura* clade (0.71 by maximum-likelihood method) suggests the possibility of potential new species. More taxa and additional gene sequences should be studied to investigate this hypothesis.

The issue of the portal of entry remains unclear. Subcutaneous nodules, ulcerative skin lesions, or both are frequently noted (e.g., in patients 2, 3, 4, 5,



**Figure 3.** Geographic distribution of 13 patients infected by *Nannizziopsis obscura* in West Africa. The different colors represent the number of cases in each country: red for 7 cases, orange for 2 cases, and green for only 1 reported case. The diameter of the circle indicated for each country is proportional to the number of cases reported.



8, and 9) (Table 1) and could have been the initial site of infection. Skin can be suspected because *Nannizziopsis* species are keratinophilic and cause extensive dermatitis with erosions and subsequent invasion of the subcutaneous structures in reptiles (1,2). When specifically investigated in this case series (i.e., patients 3 and 4) (Table 1), no *Nannizziopsis* organisms were recovered from skin or nail samples, even when patients had dermatomycoses or onychia. On the other hand, the frequency of dissemination suggests inhalation as a possible route, with subcutaneous nodules as tissue localizations other than lung as a consequence of blood dissemination. Therefore, the infection scenario described for reptiles might not apply to humans.

We cannot provide firm recommendations for antifungal treatment because of the low number of patients in our study. The MICs show no intrinsic antifungal resistance. Azole therapy appears to be the first option, but the choice between posaconazole or voriconazole depends on the pharmacokinetics of each drug and its interactions with other medications. Decrease of immunosuppressive therapy might also contribute to improvement, and surgery can be a major part of treatment for some abscesses. However, as for many invasive fungal diseases, the final prognosis depends on that of the underlying disease.

The main epidemiologic observation is the geographic origin of the patients. All came from sub-Saharan West Africa or Africa when national origin was reported (Tables 1, 2; Figure 3). The preferred migration routes explained by historical reasons—the Gambia to England route (7) and Mali, Senegal, and Guinea to France route—observed in our case-series and in the literature (6), might have introduced bias. However, France and England also have immigrants from other parts of Africa, and *Nannizziopsis* spp. infections are described only in patients from semi-arid countries. For the previously reported patients from Nigeria (4,5), the exact origin was not reported, but Nigeria also covers semiarid tropical zones. In patients for whom the information was known, the delay between the last trip to Africa and the onset of symptoms varied between 2 months and 3 years (Table 1). Patients could carry latent forms of the fungus and have onset of an opportunistic infection when their immunity fails, as described for other fungi, such as *Cryptococcus neoformans* (17) and *Histoplasma* spp. or other endemic mycoses (18).

These 9 new cases and the previously reported cases (1,3–7) highlight the difficulties in identifying the *N. obscura* species complex. These fungal infections

are likely underdiagnosed because of features shared with more common species, such as *Trichophyton* spp. or *Trichosporon* spp. Matrix-assisted laser desorption/ionization time-of-flight mass spectrometry should accelerate the process of identifying organisms and updating public databases, such as the online mass spectrometry platform (<https://msi.happy-dev.fr>), which now includes a *N. obscura* profile. Up to now, these deep infections seemed to involve T-cell immunosuppressed patients with frequent dissemination or multifocus localizations. These molds are probably endemic in sub-Saharan Africa, but their precise geographic repartition and natural ecology remain to be established. Environmental studies would be necessary to further investigate the natural ecology of these molds, as has been done recently for the emerging *Emergomyces africanus* (19).

### Acknowledgments

The authors thank all the clinicians who cared for the patients, especially Aude Barnier in the case of patient 6. We thank Mohammad Akhondi for his ITS2 sequencing; Cécile Gautier for technical assistance regarding culture of strains, MIC determinations, and PCR tests; and Eurofins Genomics France for strain sequencing. We are also deeply thankful to Françoise Dromer, who commented on the manuscript.

The National Reference Center for Invasive Mycoses and Antifungals is supported by the French Center for Diseases Control (Santé Publique France) and Institut Pasteur in Paris. The funders had no role in the study design, data collection, or analysis or interpretation of data.

### About the Author

Dr. Garcia-Hermoso is a research engineer at the Centre National de Référence Mycoses Invasives et Antifongiques. Her main research focuses on the polyphasic identification of filamentous fungi causing invasive mycosis in humans and the phylogenetic relationship among different groups of fungal species.

### References

1. Stchigel AM, Sutton DA, Cano-Lira JF, Cabañes FJ, Abarca L, Tintelnot K, et al. Phylogeny of chryso sporidia infecting reptiles: proposal of the new family *Nannizziopsiaceae* and five new species. *Persoonia*. 2013;31:86–100. <https://doi.org/10.3767/003158513X669698>
2. Cabañes FJ, Sutton DA, Guarro J. *Chryso sporium*-related fungi and reptiles: a fatal attraction. *PLoS Pathog*. 2014;10:e1004367.
3. Stillwell WT, Rubin BD, Axelrod JL. *Chryso sporium*, a new causative agent in osteomyelitis. A case report. *Clin Orthop Relat Res*. 1984;184:190–2.

4. Steininger C, van Lunzen J, Sobottka I, Rohde H, Horstkotte MA, Stellbrink H-J. Mycotic brain abscess caused by opportunistic reptile pathogen. *Emerg Infect Dis*. 2005;11:349–50. <https://doi.org/10.3201/eid1102.040915>
5. Sigler L, Hambleton S, Paré JA. Molecular characterization of reptile pathogens currently known as members of the chrysosporium anamorph of *Nannizziopsis vriesii* complex and relationship with some human-associated isolates. *J Clin Microbiol*. 2013;51:3338–57. <https://doi.org/10.1128/JCM.01465-13>
6. Nourrisson C, Vidal-Roux M, Cayot S, Jacomet C, Bothorel C, Ledoux-Pilon A, et al. Invasive infections caused by *Nannizziopsis* spp. molds in immunocompromised patients. *Emerg Infect Dis*. 2018;24:549–52. <https://doi.org/10.3201/eid2403.170772>
7. Baggott A, McGann H, Barton R, Ratner J. Disseminated *Nannizziopsis obscura* infection in a renal transplant patient—the first reported case. *Med Mycol Case Rep*. 2017;17:20–4. <https://doi.org/10.1016/j.mmcr.2017.06.002>
8. Fisher MC, Henk DA, Briggs CJ, Brownstein JS, Madoff LC, McCraw SL, et al. Emerging fungal threats to animal, plant and ecosystem health. *Nature*. 2012;484:186–94. <https://doi.org/10.1038/nature10947>
9. Lanternier F, Cypowyj S, Picard C, Bustamante J, Lortholary O, Casanova J-L, et al. Primary immunodeficiencies underlying fungal infections. *Curr Opin Pediatr*. 2013;25:736–47. <https://doi.org/10.1097/MOP.0000000000000031>
10. Guégan S, Garcia-Hermoso D, Sitbon K, Ahmed S, Moguelet P, Dromer F, et al.; French Mycosis Study Group. Ten-year experience of cutaneous and/or subcutaneous infections due to coelomycetes in France. *Open Forum Infect Dis*. 2016;3:ofw106. <https://doi.org/10.1093/ofid/ofw106>
11. Garcia-Hermoso D, Hoinard D, Gantier J-C, Grenouillet F, Dromer F, Dannaoui E. Molecular and phenotypic evaluation of *Lichtheimia corymbifera* (formerly *Absidia corymbifera*) complex isolates associated with human mucormycosis: rehabilitation of *L. ramosa*. *J Clin Microbiol*. 2009;47:3862–70. <https://doi.org/10.1128/JCM.02094-08>
12. Kumar S, Stecher G, Tamura K. MEGA7: Molecular Evolutionary Genetics Analysis version 7.0 for bigger datasets. *Mol Biol Evol*. 2016;33:1870–4. <https://doi.org/10.1093/molbev/msw054>
13. Guindon S, Dufayard J-F, Lefort V, Anisimova M, Hordijk W, Gascuel O. New algorithms and methods to estimate maximum-likelihood phylogenies: assessing the performance of PhyML 3.0. *Syst Biol*. 2010;59:307–21. <https://doi.org/10.1093/sysbio/syq010>
14. Lemoine F, Correia D, Lefort V, Doppelt-Azeroual O, Mareuil F, Cohen-Boulakia S, et al. NGPhylogeny.fr: new generation phylogenetic services for non-specialists. *Nucleic Acids Res*. 2019;47(W1):W260–5. <https://doi.org/10.1093/nar/gkz303>
15. Rouzaud C, Chosidow O, Brocard A, Fraïtag S, Scemla A, Anglicheau D, et al.; French Mycoses Study Group. Severe dermatophytosis in solid organ transplant recipients: a French retrospective series and literature review. *Transpl Infect Dis*. 2018;20:e12799. <https://doi.org/10.1111/tid.12799>
16. Brandt ME, Gaunt D, Iqbal N, McClinton S, Hambleton S, Sigler L. False-positive *Histoplasma capsulatum* Gen-Probe chemiluminescent test result caused by a *Chrysosporium* species. *J Clin Microbiol*. 2005;43:1456–8. <https://doi.org/10.1128/JCM.43.3.1456-1458.2005>
17. Garcia-Hermoso D, Janbon G, Dromer F. Epidemiological evidence for dormant *Cryptococcus neoformans* infection. *J Clin Microbiol*. 1999;37:3204–9. <https://doi.org/10.1128/JCM.37.10.3204-3209.1999>
18. Brunet K, Alanio A, Lortholary O, Rammaert B. Reactivation of dormant/latent fungal infection. *J Infect*. 2018;77:463–8. <https://doi.org/10.1016/j.jinf.2018.06.016>
19. Schwartz IS, Lerm B, Hoving JC, Kenyon C, Horsnell WG, Basson WJ, et al. *Emergomyces africanus* in soil, South Africa. *Emerg Infect Dis*. 2018;24:377–80. <https://doi.org/10.3201/eid2402.171351>

---

Address for correspondence: Dea Garcia-Hermoso, Institut Pasteur, Centre National de la Recherche Scientifique, Centre National de Référence Mycoses Invasives et Antifongiques, Unité de Mycologie Moléculaire, UMR2000, 28 rue du Dr. Roux, 75015 Paris, France; email: dea.garcia-hermoso@pasteur.fr

# Invasive Infections with *Nannizziopsis obscura* Species Complex in 9 Patients from West Africa, France, 2004–2020

## Appendix

### Materials and Methods

#### Molecular Characterization and Phylogenetic Analysis

For the genomic DNA extraction  $\approx 100$  mg of mycelium from a 5 day-old PDA culture at 30°C was suspended in 700  $\mu$ L of ATL lysing solution (Qiagen, Germantown, MD, USA) containing 500  $\mu$ L of ceramic beads, and disrupted on a MAGNA Lyser (Roche Diagnostics, Mannheim, Germany) instrument (three runs of 30s at 7,000 rpm). DNA was then purified using NucleoMag Plant (Macherey-Nagel, Düren, Germany) and the semi-automated KingFisher Flex magnetic particle processor (Thermo Fisher Scientific, Vantaa, Finland). Sequencing of PCR ITS, LSU and actin products was performed at Eurofins sequencing facility by using the cycle sequencing technology (dideoxy chain termination / cycle sequencing) on ABI 3730XL sequencing machines (Applied Biosystems). Consensus sequences were determined using the Sequencher version 5.4.6 sequence analysis software (Gene Codes Corporation, Ann Arbor, MI USA). Preliminary sequence similarity searching (BLASTn) was performed against curated fungal reference databases available at the online MycoBank database (<http://www.mycobank.org/>) and the NCBI GenBank (<http://www.ncbi.nlm.nih.gov>). Multiple sequence alignments were carried out using MAFFT v.7.308 with Geneious v11.0.5 with default settings. Single gene phylogenies for all three loci and estimation of the best substitution models were inferred using were inferred using MEGA7. The concatenated alignment was submitted to Neighbor joining (NJ) analysis using MEGA7 (1) and to Maximum likelihood (ML) analysis in the web server NGPhylogeny.fr. For NJ analyses of the combined dataset, the substitution model applied was Tajima-Nei method with a gamma distribution. Robustness of the branches was assessed by bootstrap analysis with 1000 replicates. For ML tree construction, the selected model

by Smart Model Selection (SMS) was GTR general time-reversible model according Akaike Information Criterion (AIC) test criterion. Internal branch reliability was assessed using the aLRT test (SH-Like) (2).

**Appendix Table.** GenBank accession numbers for the *Nannizziopsis obscura* species complex sequences reported in this study and those available in the literature

Patient no. (strain no. or reference)	GenBank accession numbers		
	ITS2	LSU	Actin
P1 (CNRMA4.1162)	MN982937	MN982951	MT024770
P2 (CNRMA 9.1232)	MN982938	MN982952	MT024771
P3 (CNRMA17.78)	MN982939	MN982953	MT024772
P4 (CNRMA17.507)	MN982940	MN982954	MT024773
P5 (CNRMA18.682)	MN982941	MN982955	MT024774
P6 (CNRMA18.740)	MN982942	MN982956	MT024775
P7 (CNRMA19.38)	MN982943	MN982957	MT024776
P8 (CNRMA19.607)	MN982944	MN982958	MT024777
P9 (CNRMA20.123)	MT345076	MT341813	MT350285
Stilwell, 1984 (3)	NR111878	NA	NA
Steiniger 2005 (4)	HF547869	HF547853	HF547877
Baggott 2017 (5)	NA	NA	NA
Nourrisson 2018 (6)	KY771168	NA	NA
Nourrisson 2018 (6)	KY771169	NA	NA

## References

1. Kumar S, Stecher G, Tamura K. MEGA7: Molecular Evolutionary Genetics Analysis version 7.0 for bigger datasets. *Mol Biol Evol.* 2016;33:1870–4. [PubMed](#)  
<https://doi.org/10.1093/molbev/msw054>
2. Anisimova M, Gascuel O. Approximate likelihood-ratio test for branches: a fast, accurate, and powerful alternative. *Syst Biol.* 2006;55:539–52. [PubMed](#)  
<https://doi.org/10.1080/10635150600755453>
3. Stillwell WT, Rubin BD, Axelrod JL. *Chrysosporium*, a new causative agent in osteomyelitis. A case report. *Clin Orthop Relat Res.* 1984; (184):190–2. [PubMed](#)
4. Steininger C, van Lunzen J, Sobottka I, Rohde H, Horstkotte MA, Stellbrink H-J. Mycotic brain abscess caused by opportunistic reptile pathogen. *Emerg Infect Dis.* 2005;11:349–50. [PubMed](#)  
<https://doi.org/10.3201/eid1102.040915>
5. Baggott A, McGann H, Barton R, Ratner J. Disseminated *Nannizziopsis obscura* infection in a renal transplant patient—the first reported case. *Med Mycol Case Rep.* 2017;17:20–4. [PubMed](#)  
<https://doi.org/10.1016/j.mmcr.2017.06.002>
6. Nourrisson C, Vidal-Roux M, Cayot S, Jacomet C, Bothorel C, Ledoux-Pilon A, et al. Invasive infections caused by *Nannizziopsis* spp. molds in immunocompromised patients. *Emerg Infect Dis.* 2018;24:549–52. [PubMed](#) <https://doi.org/10.3201/eid2403.170772>