



HAL
open science

Next-Generation Sequencing for Diagnosis and Tailored Therapy: A Case Report of Astrovirus-Associated Progressive Encephalitis

M.-L. Frémond, P. Pérot, E. Muth, G. Cros, M. Dumarest, N. Mahlaoui, D. Seilhean, I. Desguerre, C. Hébert, N. Corre-Catelin, et al.

► **To cite this version:**

M.-L. Frémond, P. Pérot, E. Muth, G. Cros, M. Dumarest, et al.. Next-Generation Sequencing for Diagnosis and Tailored Therapy: A Case Report of Astrovirus-Associated Progressive Encephalitis. *Journal of the Pediatric Infectious Diseases Society*, 2015, 4 (3), pp.e53-e57. 10.1093/jpids/piv040 .
pasteur-02452610

HAL Id: pasteur-02452610

<https://pasteur.hal.science/pasteur-02452610v1>

Submitted on 23 Jan 2020

HAL is a multi-disciplinary open access archive for the deposit and dissemination of scientific research documents, whether they are published or not. The documents may come from teaching and research institutions in France or abroad, or from public or private research centers.

L'archive ouverte pluridisciplinaire **HAL**, est destinée au dépôt et à la diffusion de documents scientifiques de niveau recherche, publiés ou non, émanant des établissements d'enseignement et de recherche français ou étrangers, des laboratoires publics ou privés.

Next-Generation Sequencing for Diagnosis and Tailored Therapy: A Case Report of Astrovirus-Associated Progressive Encephalitis

M.-L. Frémond,^{1,2} P. Pérot,³ E. Muth,⁴ G. Cros,^{1,2} M. Dumarest,³ N. Mahlaoui,^{1,2,5,6} D. Seilhean,⁷ I. Desguerre,⁸ C. Hébert,⁴ N. Corre-Catelin,⁹ B. Neven,^{1,2} M. Lecuit,^{1,10,11} S. Blanche,^{1,2} C. Picard,^{1,6} and M. Eloit^{3,4}

¹Unité d'Immuno-Hématologie et Rhumatologie Pédiatrique, Hôpital Universitaire Necker-Enfants Malades, Assistance Publique-Hôpitaux de Paris, France; ²Université Paris Descartes, Sorbonne Paris Cité, Institut Imagine, France; ³Institut Pasteur, Biology of Infection Unit, Institut National de la Santé et de la Recherche Médicale (INSERM) U1117, Pathogen Discovery Laboratory, Paris, France; ⁴PathoQuest, Paris, France; ⁵Laboratoire de Génétique Humaine des Maladies Infectieuses, Branche Necker, INSERM U1163, Paris, France; ⁶Centre de Référence Déficits Immunitaires Héréditaires, Hôpital Universitaire Necker-Enfants Malades, Assistance Publique-Hôpitaux de Paris, France; ⁷Département de Neuropathologie, Hôpital Universitaire Pitié-Salpêtrière, Université Pierre et Marie Curie, Sorbonne Universités, Paris, France; ⁸Université Paris Descartes, Unité de Neuropédiatrie, Hôpital Universitaire Necker-Enfants Malades, Paris, France; ⁹Investigation Clinique et Accès aux Ressources Biologiques, Institut Pasteur, Paris, France; ¹⁰Paris Descartes University, Sorbonne Paris Cité, Division of Infectious Diseases and Tropical Medicine, Necker-Enfants Malades University Hospital, Institut Imagine, France; and ¹¹Institut Pasteur, Biology of Infection Unit, INSERM U1117, Paris, France

Corresponding Author: Marc Eloit, DVM, PhD, Institut Pasteur, Biology of Infection Unit, INSERM U1117, Laboratory of Pathogen Discovery, Department of Virology, 28 rue du Docteur Roux, F-75724 Paris, France. E-mail: marc.eloit@pasteur.fr.

Received April 22, 2015; accepted June 9, 2015; electronically published July 12, 2015.

A boy with X-linked agammaglobulinemia experienced progressive global motor decline, cerebellar syndrome, and epilepsy. All standard polymerase chain reactions for neurotropic viruses were negative on cerebrospinal fluid and brain biopsy. Next-generation sequencing allowed fast identification of a new astrovirus strain (HAsV-VA1/HMO-C-PA), which led to tailor the patient's treatment, with encouraging clinical monitoring over 1 year.

Key words. agammaglobulinemia; astrovirus; Bruton; encephalitis.

INTRODUCTION

Viral encephalitis is a major cause of morbidity and mortality in patients with inherited primary immunodeficiency (PID) such as X-linked agammaglobulinemia (XLA) [1]. Encephalitis of unknown etiology also constitutes a major challenge, in particular in immunocompromised patients, despite extensive laboratory testing including cultures, reverse transcription-polymerase chain reaction (RT-PCR) and amplicon sequencing [2, 3]. Failure to identify the etiology in infectious encephalitis impairs or delays appropriate therapeutics and increases morbidity and mortality associated with these diseases, notably in patients with PIDs. Infectious encephalitis of unknown etiology probably account for most of undiagnosed progressive cognitive decline in XLA patients. Next-generation sequencing (NGS) is becoming an alternative diagnosis tool for infectious diseases [4]. In this study, we report the case of a boy with unidentified encephalitis in the context of XLA in which NGS led to the identification of a new astrovirus strain related to the VA1/HMO-C group and allowed

tailored therapy, with encouraging clinical monitoring over 1 year.

CASE REPORT

A 14-year-old boy with XLA, a genetic disorder affecting B-cell differentiation due to hemizygous mutation in the Bruton tyrosine kinase coding gene, was admitted to the immunology unit with a progressive cognitive decline and recurring seizures over 1 year. He had no peripheral B cell and showed a profound agammaglobulinemia. He was put on substitutive polyvalent intravenous immunoglobulins (IVIG) every 3 weeks and was well until, at 10 years of age, he started to display myoclonic epilepsy with no viral finding (cerebrospinal fluid [CSF], blood, sputum, and stools). A cognitive impairment was noted over the last 4 years (loss of 30 points of Intelligence Quotient [Wechsler Intelligence Scale for Children, WISC-IV]). He was unable to read or write, and his speech was impaired. Clinical examination found ataxia, erratic myoclonies, and dysarthria. In June 2013, brain magnetic resonance

imaging (MRI) showed diffuse cortical-subcortical brain atrophy and periventricular hypersignals (Figure 1A). Electroencephalography revealed irregular slow-wave activity associated with bilateral frontotemporal spikes but no epileptic discharges. Cerebrospinal fluid analysis was normal for white cell count, for glucose and protein

concentrations, and was negative by real-time PCR and RT-PCR for a comprehensive list of neurotropic viruses (Supplementary Table S1). Brain biopsy was performed in the right frontal lobe in February 2014. Histologic findings were consistent with acute pan-encephalitis (Figure 1B), and all standard PCR and RT-PCR for neurotropic viruses

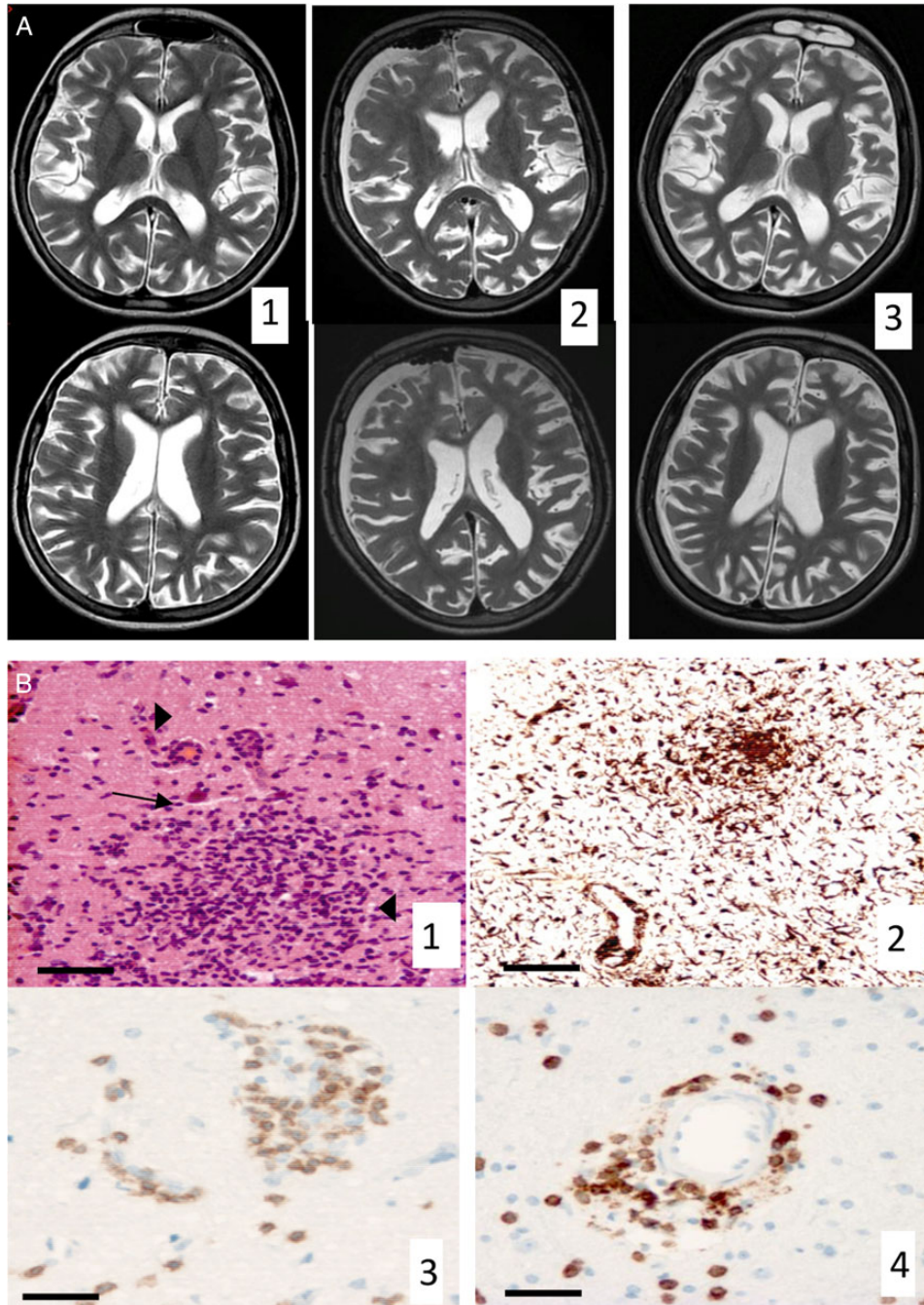


Figure 1. The clinical case is illustrated. (A) Results of brain magnetic resonance imaging (MRI) in T2-weighted sequences performed on June 2013 (1) and on February 2014 after brain biopsy (2), showing global white and gray matter atrophy and periventricular hypersignals. Brain MRI performed on September 2014 (3) showed no progression in brain atrophy or increasing in periventricular hypersignals. (B) Results of brain biopsy showing the following: (1) microglial nodules (arrow) and perivascular infiltrates (arrow heads) in the cortex and white matter (hematoxylin and eosin stain, bar = 100 μ m); (2) IBA1 immunohistochemistry confirming diffuse microglial activation (WAKO rabbit polyclonal anti-IBA1, 1:500) (bar = 100 μ m). Perivascular cuffs of mononuclear cells include T lymphocytes (3) CD3⁺ (Ventana monoclonal rabbit antibody 1:500) and (4) CD8⁺ (FLEX ready-to-use monoclonal mouse antibody) (bar = 50 μ m). There is no feature of Creutzfeldt-Jakob disease.

were negative on this biopsy sample (Supplementary Table S1). Total RNAs, as a signature of viral, bacterial, fungal, or protozoan gene expression, were deep sequenced by NGS and analyzed. Large fragments of an astrovirus genome were identified, showing high levels of homology with the VA1/HMO-C clade (a clade distant to those screened by standard RT-PCR). The complete genome was obtained, and this new strain was named HAstV-VA1/HMO-C-PA. It was striking to discover that HAstV-VA1/HMO-C-PA is closely related to 3 astrovirus strains that have been reported recently in human cases of encephalitis, in different immunocompromised contexts including XLA [5–7]. Specific RT-PCR were designed and were positive on the brain biopsy sample (Supplementary Figure S3) but not on the CSF previously (June 2013) and concomitantly (March 2014) sampled (for detailed information on methods and results, see Supplementary Data). This virus identification led to an adaptation of treatment and prescription of high-dose IVIG 1 g/kg per day, quickly tapered to 1 g/kg twice and then once a week due to mild clinical intolerance, and 3 bolus of methylprednisolone (1 g/1.73 m² for 3 consecutive days). The patient also received intravenous ribavirin for 7 days (30 mg/kg per day, then 15 mg/kg every 6 hours for 4 days, followed by 8 mg/kg every 8 hours for 3 days) and then daily oral ribavirin and 50 µg pegylated interferon (PEG-IFN) alpha-2b per week. He is currently under daily oral ribavirin (800 mg/day, which was later adjusted based on hematologic tolerance) and 50 µg PEG-IFN alpha-2b and 1 g/kg IVIG per week. At month 12 of follow-up, progression in motor behavior and mild memory improvement has been noted. Measured WISC-IV was stable and epilepsy was controlled. Brain atrophy and periventricular hypersignals remained stable upon brain MRI control.

Ethic Statement

Next-generation sequencing analysis was performed on the brain biopsy done for standard diagnostic. Written consent was obtained from the parents for his inclusion in the “Pathodisc” study, which was aimed at identifying pathogens in infectious syndromes of unknown etiology by NGS. The Pathodisc study was approved by the French Ethical Committee, CPP Ile de France IV, including College I and College II (on January 26, 2010 under the code 2009/31NICB), and declared to the French Research Ministry under the code DC 2009–1067 collection 25, amendment to the file 2008–68, collection n°1, following the French regulation. It was also approved by the French Privacy Agency (Commission de l’Informatique et des Libertés) on August 11, 2011. The samples were managed by the ICAReB platform, with regards to bio-resource ethical compliance, transport, registering and coding.

DISCUSSION

The *Astroviridae* family comprises nonenveloped, positive sense, single-stranded enteric RNA viruses, typically 28–30 nm in diameter. One of the genera, *Mamastrovirus*, comprises viruses infecting mammals including a clade corresponding to human astroviruses 1–8 (HAstVs 1–8) (Figure 2B) [8]. Another clade, closer to porcine, mink, and ovine astroviruses, has been identified in a case of human gastroenteritis [9] and is referred to as the VA1/HMO-C clade. In 2010, a member of this clade was identified as responsible for persistent brain infection leading to dementia and death in a boy with XLA in the United States [5], and in 2015 2 independent cases coming from the United Kingdom have supported the involvement of VA1/HMO-C strains in 2 other fatal cases of encephalitis [6, 7]. Thus, we hypothesize that infections by astroviruses belonging to the clade VA1/HMO-C, thought to be highly prevalent in the human population [10], remain underdiagnosed and might therefore account for a part of nonidentified progressive neurodegeneration in immunocompromised patients. Beyond the VA1/HMO-C group, it should be noted that HAstV4 has been identified, post mortem, in the brain tissue of a 7-month-old boy with severe combined immunodeficiency in the context of disseminated multiorgan infection [11]. More generally, astroviruses have begun to be recognized as causative agents of encephalitis and neurological disorders in cattle [12, 13] and mink [14], although not belonging to the VA1/HMO-C group, which may suggest different or even species-specific mechanisms of neurotropic infection. Therefore, astroviruses, and in particular members of the VA1/HMO-C clade, complete the list of enteric viruses that, like some enteroviruses (poliovirus vaccine strain, coxsackie viruses, and echoviruses) [15–17], may disseminate to the central nervous system despite IVIG reconstitution. Based on other RNA-virus treatment approaches in this setting [18], treatment was modified upon the diagnosis of astrovirus infection, to include higher doses of IVIG, ribavirin, and PEG-IFN alpha-2b. Mild cognitive improvement was noted after a 12-month follow up, although it is difficult to assess the impact of treatment on the course of the disease.

This study illustrates the strength of deep sequencing applied to the diagnosis of infectious diseases, not only in revealing the presence of unpredicted infectious agents in patients’ samples but also in identifying genetic virus variants that may not be detected by generic PCRs. This seems particularly relevant for most RNA viruses, whose genomes are highly variable. In the present case, although astroviruses were thought to be a possible etiology, standard PCR was unable to detect the pathogen due its genetic

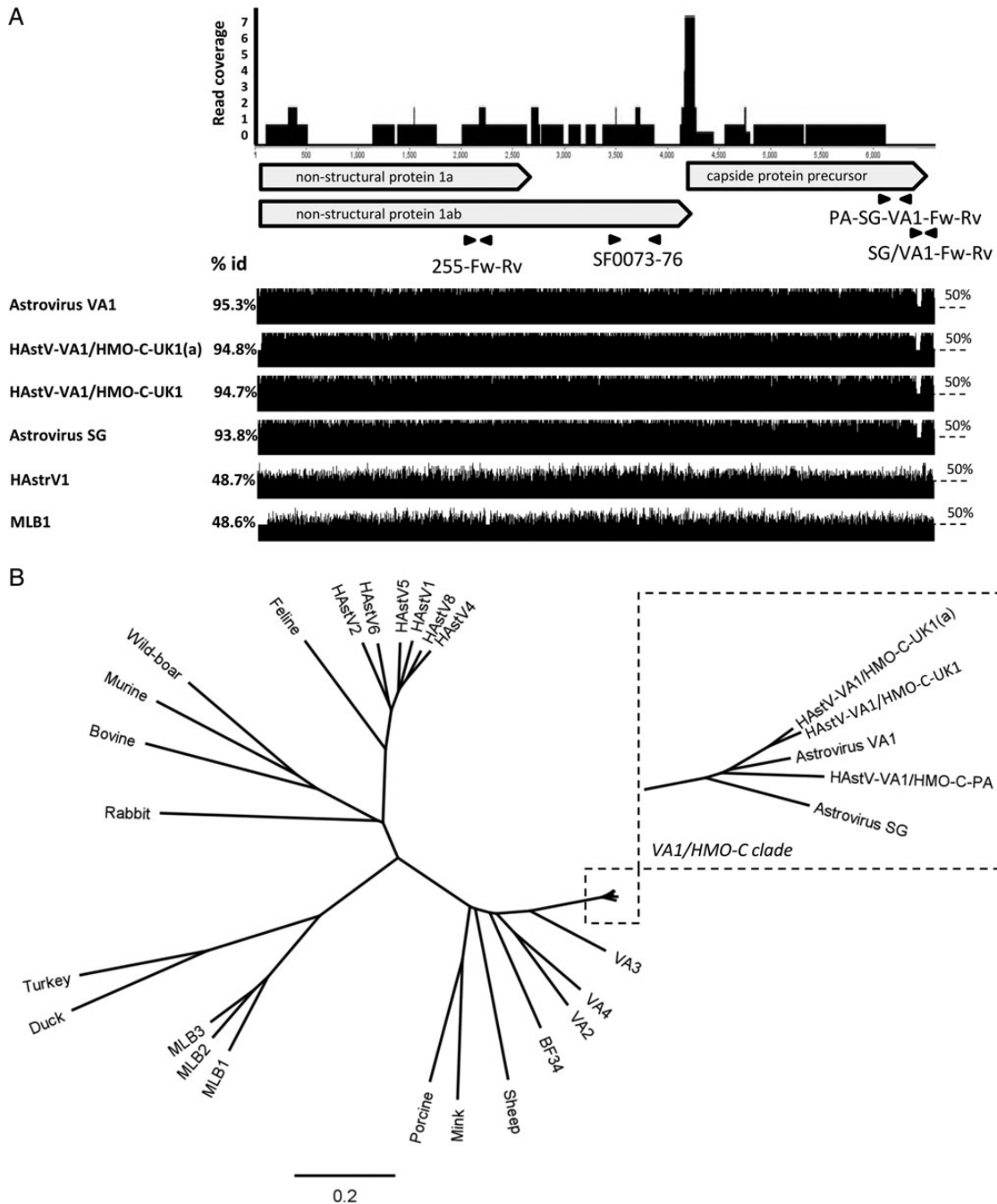


Figure 2. Astrovirus identification by NGS and sequences analysis. (A) Upper part: a total of 68 reads assembled or not in contigs are mapped to the closest astrovirus strain, astrovirus VA1 (FJ973620), to illustrate the genome coverage (see details about genome finishing in Supplementary Figure S1). Polymerase chain reaction primers used in this study (Astro-255; SF0073/76; PA-SG-VA1) or by others (SG/VA1) are depicted in relation to their genomic location. Bottom part: percentage of identity between strain HAstrV-VA1/HMO-C-PA and other close (HAstrV-VA1/HMO-C-UK1, HAstrV-VA1/HMO-C-UK1(a), astrovirus VA1, astrovirus SG) or more distant (HAstrV1, MLB1) human astroviruses. (B) Phylogenetic analysis based on whole genomes, showing representative astrovirus strains and highlighting the VA1/HMO-C clade, which features HAstrV-VA1/HMO-C-PA (all accession numbers are detailed in the Supplementary Data).

distance from the HAstVs 1–8 clade. Even within the VA1/HMO-C clade, variations in sequences still exist and may be responsible for the failure of generic PCR amplification (for an illustration, see Supplementary Figure S2). Overall, this study is a striking illustration of (1) the limit of targeted, gene-specific approaches applied to the diagnosis of

viral diseases and (2) the strength of NGS, for which no a priori on-target sequence is needed.

CONCLUSIONS

Using optimized pipelines and sequencers, results can be delivered within a time short enough for a medical decision

shift and clinical benefit [4]. In our case, virus identification was obtained less than 3 days from reception of the sample. Our results extend to viral diseases the demonstration of the usefulness of NGS shown for bacterial diseases, drawn from a case of neuroleptospirosis in a boy with a severe combined immunodeficiency, for which the diagnosis was only established by NGS and led to a rapid and efficient treatment [19]. Because of its increasing availability in the clinics, NGS will probably be applied in a first step to cases where an infectious etiology is likely despite negative extensive search for infectious agents by all available conventional methods.

Supplementary Data

Supplementary materials are available at the *Journal of the Pediatric Infectious Diseases Society* online (<http://jpid.oxfordjournals.org>).

Acknowledgments

We thank the platform Investigation Clinique et Accès aux Ressources Biologiques (Institut Pasteur, Paris) for help in the management of biological samples.

Financial support. This work was funded by the French Government's Investissement d'Avenir program, Laboratoire d'Excellence "Integrative Biology of Emerging Infectious Diseases" (Grant Number ANR-10-LABX-62-IBEID), and Institut National de la Santé et de la Recherche Médicale.

Potential conflicts of interest. All authors: No reported conflicts.

All authors have submitted the ICMJE Form for Disclosure of Potential Conflicts of Interest.

References

1. Winkelstein JA, Marino MC, Lederman HM, et al. X-linked agammaglobulinemia: report on a United States registry of 201 patients. *Medicine (Baltimore)* 2006; 85:193–202.
2. Tack DM, Holman RC, Folkema AM, et al. Trends in encephalitis-associated deaths in the United States, 1999–2008. *Neuroepidemiology* 2014; 43:1–8.
3. Glaser CA, Honarmand S, Anderson LJ, et al. Beyond viruses: clinical profiles and etiologies associated with encephalitis. *Clin Infect Dis* 2006; 43:1565–77.
4. Lecuit M, Eloit M. The diagnosis of infectious diseases by whole genome next generation sequencing: a new era is opening. *Front Cell Infect Microbiol* 2014; 4:25.
5. Quan PL, Wagner TA, Briese T, et al. Astrovirus encephalitis in boy with X-linked agammaglobulinemia. *Emerg Infect Dis* 2010; 16:918–25.
6. Naccache SN, Peggs KS, Mattes FM, et al. Diagnosis of neuroinvasive astrovirus infection in an immunocompromised adult with encephalitis by unbiased next-generation sequencing. *Clin Infect Dis* 2015; 60:919–23.
7. Brown JR, Morfopoulou S, Hubb J, et al. Astrovirus VA1/HMO-C: an increasingly recognized neurotropic pathogen in immunocompromised patients. *Clin Infect Dis* 2015; 60:881–8.
8. De Benedictis P, Schultz-Cherry S, Burnham A, Cattoli G. Astrovirus infections in humans and animals – molecular biology, genetic diversity, and interspecies transmissions. *Infect Genet Evol* 2011; 11:1529–44.
9. Finkbeiner SR, Li Y, Ruone S, et al. Identification of a novel astrovirus (astrovirus VA1) associated with an outbreak of acute gastroenteritis. *J Virol* 2009; 83:10836–9.
10. Burbelo PD, Ching KH, Esper F, et al. Serological studies confirm the novel astrovirus HMOastV-C as a highly prevalent human infectious agent. *PLoS One* 2011; 6:e22576.
11. Wunderli W, Meerbach A, Gungör T, et al. Astrovirus infection in hospitalized infants with severe combined immunodeficiency after allogeneic hematopoietic stem cell transplantation. *PLoS One* 2011; 6:e27483.
12. Li L, Diab S, McGraw S, et al. Divergent astrovirus associated with neurologic disease in cattle. *Emerg Infect Dis* 2013; 19:1385–92.
13. Bouzalas IG, Wüthrich D, Walland J, et al. Neurotropic astrovirus in cattle with nonsuppurative encephalitis in Europe. *J Clin Microbiol* 2014; 52:3318–24.
14. Blomström AL, Widén F, Hammer AS, et al. Detection of a novel astrovirus in brain tissue of mink suffering from shaking mink syndrome by use of viral metagenomics. *J Clin Microbiol* 2010; 48:4392–6.
15. Conley ME, Dobbs AK, Farmer DM, et al. Primary B cell immunodeficiencies: comparisons and contrasts. *Annu Rev Immunol* 2009; 27:199–227.
16. Chun JK, Lee TJ, Song JW, et al. Analysis of clinical presentations of Bruton disease: a review of 20 years of accumulated data from pediatric patients at Severance Hospital. *Yonsei Med J* 2008; 49: 28–36.
17. Halliday E, Winkelstein J, Webster AD. Enteroviral infections in primary immunodeficiency (PID): a survey of morbidity and mortality. *J Infect* 2003; 46:1–8.
18. Tan CW, Lai JK, Sam IC, Chan YF. Recent developments in antiviral agents against enterovirus 71 infection. *J Biomed Sci* 2014; 21:14.
19. Wilson MR, Naccache SN, Samayoa E, et al. Actionable diagnosis of neuroleptospirosis by next-generation sequencing. *N Engl J Med* 2014; 370:2408–17.