



HAL
open science

Mucor irregularis-associated cutaneous mucormycosis: Case report and review

Blandine Rammaert, Cécile Angebault, Anne Scemla, Sylvie Fraitag, Nathalie Lerolle, Marc Lecuit, Marie-Elisabeth Bougnoux, Olivier Lortholary

► To cite this version:

Blandine Rammaert, Cécile Angebault, Anne Scemla, Sylvie Fraitag, Nathalie Lerolle, et al.. Mucor irregularis-associated cutaneous mucormycosis: Case report and review. Medical Mycology Case Reports, 2014, 6, pp.62-65. 10.1016/j.mmcr.2014.07.005 . pasteur-02391553

HAL Id: pasteur-02391553

<https://pasteur.hal.science/pasteur-02391553>

Submitted on 3 Dec 2019

HAL is a multi-disciplinary open access archive for the deposit and dissemination of scientific research documents, whether they are published or not. The documents may come from teaching and research institutions in France or abroad, or from public or private research centers.

L'archive ouverte pluridisciplinaire **HAL**, est destinée au dépôt et à la diffusion de documents scientifiques de niveau recherche, publiés ou non, émanant des établissements d'enseignement et de recherche français ou étrangers, des laboratoires publics ou privés.




Distributed under a Creative Commons Attribution - NonCommercial - NoDerivatives 4.0 International License



ELSEVIER

Contents lists available at ScienceDirect

Medical Mycology Case Reports

journal homepage: www.elsevier.com/locate/mmcr

Mucor irregularis-associated cutaneous mucormycosis: Case report and review



Blandine Rammaert^a, Cécile Angebault^b, Anne Scemla^c, Sylvie Fraitag^d, Nathalie Lerolle^a, Marc Lecuit^{a,e,f}, Marie-Elisabeth Bougnoux^b, Olivier Lortholary^{a,g,*}

^a Université Paris-Descartes, Sorbonne Paris Cité, APHP, Service des Maladies Infectieuses et Tropicales, Hôpital Necker-Enfants Malades, Centre d'Infectiologie Necker-Pasteur, Institut Imagine, 75015 Paris, France

^b Université Paris-Descartes, Sorbonne Paris Cité, APHP, Service de Microbiologie, Unité de Parasitologie-Mycologie, Hôpital Necker-Enfants Malades, 75015 Paris, France

^c Université Paris-Descartes, Sorbonne Paris Cité, APHP, Service de Transplantation Rénale, Hôpital Necker-Enfants Malades, 75015 Paris, France

^d Université Paris-Descartes, Sorbonne Paris Cité, APHP, Département de Pathologie, Hôpital Necker-Enfants Malades, 75015 Paris, France

^e Institut Pasteur, Unité de Biologie des Infections, 75015 Paris, France

^f Inserm U1117, 75015 Paris, France

^g Institut Pasteur, Unité de Mycologie Moléculaire, CNRS URA 3012, 75015 Paris, France

ARTICLE INFO

Article history:

Received 23 June 2014

Accepted 10 July 2014

Keywords:

Invasive fungal disease

Mucorales

Solid organ transplantation

Mucormycoses

Amphotericin B

ABSTRACT

Solid organ transplant recipients are at risk for invasive fungal diseases, and are also exposed to healthcare-associated mucormycosis. Mainly causing localized cutaneous mucormycosis, *Mucor irregularis* infection is reported for the first time in a kidney-transplant recipient. A healthcare-associated origin was highly suspected in this case. We performed a literature review and highlight the characteristics of this very rare fungus.

© 2014 International Society for Human and Animal Mycology. International Society for Human and Animal Mycology Published by Elsevier B.V. This is an open access article under the CC BY-NC-SA license (<http://creativecommons.org/licenses/by-nc-sa/3.0/>).

1. Introduction

Cutaneous localizations are frequently observed in healthcare-associated mucormycosis [1]. In this setting, highly immunosuppressed patients such as those with hematological malignancy or transplantation are particularly at risk. In one study mucormycosis accounted for 2.3% of invasive fungal diseases in solid organ transplantation (SOT), with a mortality rate often approaching 50% [2]. While the highest incidence rate was observed in liver transplant recipients, the estimated mucormycosis incidence in kidney transplant recipients ranged from 0.2% to 1.2% [3]. In a large cohort of patients with invasive fungal diseases from 23 US transplant centers, cutaneous localization accounted for 13% of the 28 mucormycosis cases [2]. The diagnosis of mucormycosis is often delayed in SOT [4], but this is highly dependent on the infected site. However, even though skin localizations can be easily documented by skin biopsies, species identification remains difficult. In fact, in healthcare-associated mucormycosis, more than 30% of *Mucorales* species responsible for cutaneous involvement were unidentified [1].

We report a subacute cutaneous mucormycosis in a kidney transplant recipient due to a very rare *Mucorale* species. It is possible that the infection was healthcare-associated. To our knowledge, this is the first reported case of *Mucor irregularis* infection in a solid organ transplant recipient. However, the management of mucormycosis in the SOT population differs from treatment in hematological patients, and the management of this specific *Mucorale* species is discussed.

2. Case

A 69 year-old woman was admitted in March 2012 for subcutaneous nodular lesions on the back of the left hand and left elbow (Fig. 1). She had chronic renal failure secondary to a hemolytic uremic syndrome and had received two kidney transplants from cadaveric donors in 1987 and 1993. Her baseline creatinine serum level was 150 µmol/L. Her current immunosuppressive therapy was cyclosporine 50 mg b.i.d., azathioprine 50 mg/d and prednisolone 5 mg/d. One year earlier, she was diagnosed with an epidermoid carcinoma on the right leg, which was treated with radiation therapy. She also had a history of gout.

* Corresponding author.

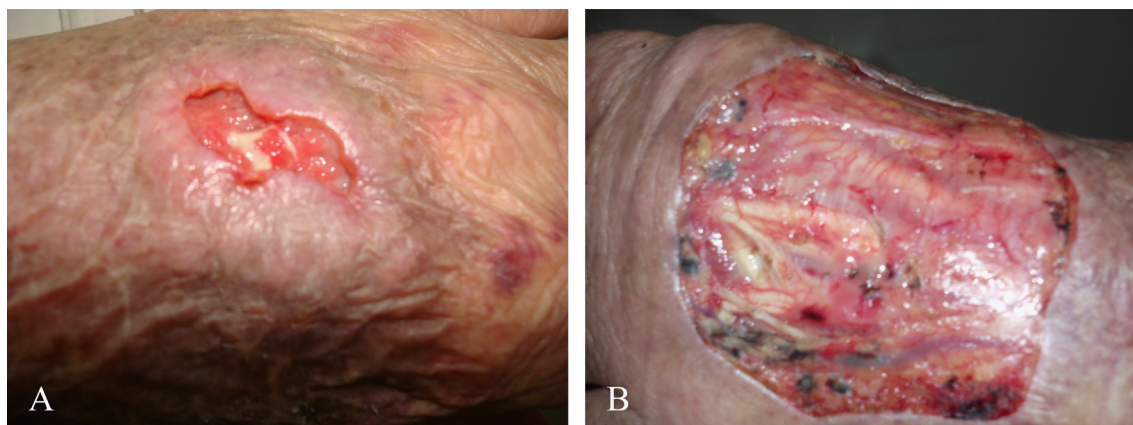


Fig. 1. Cutaneous mucormycosis due to *Mucor irregularis* in a kidney-transplanted recipient. (A) Cutaneous lesions before liposomal amphotericin B treatment. (B) After large debridement on day +13 of liposomal amphotericin B.

At the end of January 2012, she had corticosteroid infiltrations on the left radiocarpal and right metacarpus-phalangeal joints for a gout flare-up. Three weeks later, five-millimeter white subcutaneous nodules appeared, first on the left hand and then on the left elbow. The patient did not report previous injury to the left arm. She mentioned that she applied a moisturizer on both arms daily, but did not recall any contact with plants or animals.

On admission (day 0), the hand nodules had become ulcerated and purulent (Fig. 1A). Overall, the lesions were painless and the patient had no fever. No sign of arthritis or neurological abnormality were noted. Blood test results showed 6000 leukocytes/mm³, 800 lymphocytes/mm³, 200,000 platelets/mm³, hemoglobin 10.8 g/dL, C-reactive protein 6 mg/L, creatinine 195 μmol/L, glucose 16.4 mmol/L with HbA1c 8.1%, iron level 14 μmol/L, ferritin 774 μg/L, and LDH 548 UI/L. A skin biopsy was performed and histopathologic findings showed non-caseating eosinophilic necrosis, granulomatous histiocytic infiltrate, and multinucleate giant cells in the dermis and subcutis. Necrotic areas were surrounded by large, irregular, non-septate, wide-angle branching hyphae on periodic acid–Schiff and Grocott stainings (Fig. 2).

Cultures of biopsy specimens on Sabouraud chloramphenicol agar slants (BioRad Laboratories, Marnes-La-Coquette, France) incubated at 30 °C and 35 °C were positive (day +5) with profuse fluffy whitish colonies presenting a lemon-yellow reverse. The identification was performed by sequencing of the ITS1–5.8S–ITS2 region of the ribosomal DNA using the universal primers ITS1–ITS4 [5]. The nucleotide sequence (deposited in Genbank under accession number KJ472786) had 100% identity over 451 bp for *M. irregularis* (formerly *Rhizomucor variabilis* var. *variabilis* [6]), compared to the nucleotide sequences of strains CMFCCC B 50 m and CBS 654.78 published under GenBank accession numbers JX976252 and JX976261 [7]. Minimal inhibitory concentrations, measured by the *E*-test agar diffusion method (bioMérieux SA, Marcy l'Etoile, France), were respectively 0.094, 12, 8 and > 32 μg/ml to amphotericin B (AmB), itraconazole, posaconazole and voriconazole, respectively.

To assess whether mucormycosis was localized to the skin or disseminated, we performed sinus, chest and abdominal computed tomography, as well as plain films of the left arm, and a cerebral magnetic resonance. All were normal. Cyclosporine and prednisolone were tapered and azathioprine was discontinued. Concurrent type 2 diabetes was balanced with oral medication. Liposomal amphotericin B (L-AmB) was immediately introduced at 3 mg/kg/day, and then increased at 5 mg/kg/day (day +9) due to progression of the lesions. During the course of therapy, the patient showed signs of L-AmB nephrotoxicity with serum creatinine increasing up to 380 μmol/L and respiratory distress due to

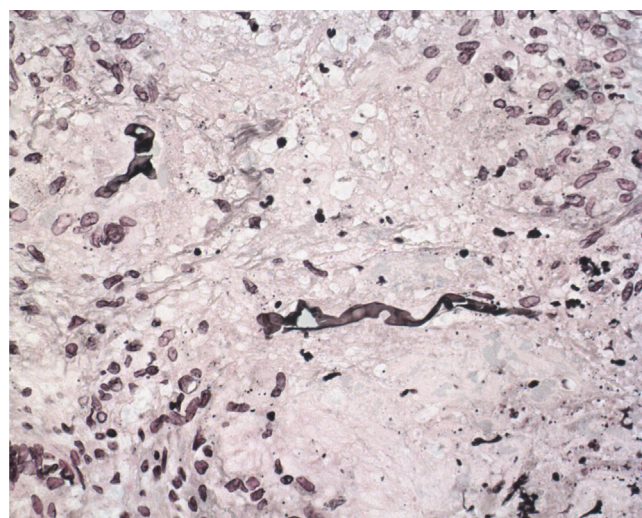


Fig. 2. Histopathological examination of skin biopsy in a cutaneous mucormycosis due to *Mucor irregularis*. Within the dermis is a heavy mixed granulomatous and suppurative infiltrate extending to the subcutis. Fungi are located within histiocytic granulomas showing a large number of giant multinucleate cells. *Mucor irregularis* hyphae are very broad, non-septate and branch at 90°. They appear often twisted (Gomori–Grocott staining; × 400).

pulmonary edema. Dialysis was performed twice. Given the severe nephrotoxicity to L-AmB, the drug was discontinued (day +21). The patient received a total of 1.1 g of L-AmB over 3 weeks. Extensive surgical debridement of the left hand and elbow was performed on day +13 (Fig. 1B). Progressive local improvement was noted in the following weeks. One month post-surgery (day +30), a skin graft was successfully performed. No mucormycosis relapse was noted 2 years after treatment discontinuation.

Suspecting a healthcare-associated infection, we attempted to look the presence of fungi in the corticosteroid vial, but it unfortunately could not be analyzed. However, no mucormycosis in patients receiving steroids infiltration was reported to the French National Institute for Health Surveillance (InVS) during the same period. In addition, the patient's skin moisturizer was also cultured on Sabouraud agar slants but no fungus was isolated.

3. Discussion

In 1999, Voigt et al. reported that *R. variabilis* was misplaced in the *Rhizomucor* clade and would be better positioned within

Table 1
Proven cases of *Mucor irregularis* published in the literature.

Country	Age of cases	Gender	Localization	Comorbidities	Disease duration	Treatment	Duration	Outcome	Ref.
India	18	M	Rhinofacial	None	12 years	Debridement; systemic fluconazole	60 days	Improved	[12]
	50	M	Arm	None	6 months	Local fluconazole Fluconazole	90 days 2 months	Lost to follow up Lost to follow up	[13]
Japan	78	M	Legs	Type 2 diabetes, bladder cancer, rheumatoid arthritis, steroids	3 months	Debridement+L-AmB 5 mg/kg/day	12 weeks	Cured at EOT; no further follow-up	[14]
China	37	F	Face, sinus	None	10 years	d-AmB total dose 1.5 g Itraconazole	3 months 2 months	Cured at 3-month follow up	[14]
	37	F	Hand	None	18 years	Ketoconazole	ND	Recurrence	[10]
	54	F	Face	None	16 years	Fluconazole	ND	Recurrence	[10]
	33	M	Arm	None	7 years	Itraconazole+terbinafine; d-AmB total dose 42.3 mg/kg	ND	Cured at EOT	[10]
	5	F	Face	None	7 months	Itraconazole+ terbinafine+bifonazole; d-AmB total dose 50 mg/kg	ND	Cured at EOT	[10]
	40	F	Cheek	None	9 years	d-AmB total dose 3.2 mg/kg; itraconazole	ND	Cured at EOT	[10]
	57	M	Rhinofacial	None	3 years	Itraconazole	3 months	Cured at EOT; no further follow-up	[9]
	35	M	Rhino-facial	None		L-AmB+terbinafine	2 months	Cured at 1-year follow up	[11]
USA	57	M	Arms	Rheumatoid arthritis, acute myeloid leukemia, neutropenia, steroids	Few days	d-AmB total dose 770 mg ABLC total dose 6.3 g Posaconazole	10 days 17 days 3 months	Cured at EOT; died from leukemia	[15]
USA	14	F	Palate	Hematopoietic stem cell transplant recipient	2 weeks	Posaconazole Posaconazole +Caspofungin L-AmB+caspofungin	2 weeks 6 weeks 2 weeks	Improved after 4 weeks of treatment; died from <i>Hormographiella aspergillata</i> infection	[16]

d-AmB: amphotericin B deoxycholate; L-AmB: liposomal AmB; ABLC: amphotericin B lipid complex; EOT: end of therapy; ND: no data.

Mucor spp. [8], and its name was changed to *M. irregularis*. This species was not reported in the recent French retrospective cohort of patients with mucormycosis [4]. However, it has occasionally been responsible for cutaneous mucormycosis in China [9–11], India [12,13], Japan [14], USA [15,16] and Australia [17]. The 12 documented cases are presented in Table 1. Infections were all proven by skin or mucosal biopsies, with DNA sequencing of cultured isolates for cases published since 2009. This fungus exhibits a specific cutaneous tropism involving the uncovered skin. Chronic lesions lasting from several months to years have been described in immunocompetent patients [9–13]. Although the incubation period is unknown, the infection seems to develop within few days in neutropenic patients [15,16], and rapidly in other immunocompromised hosts [14]. Histopathological examination shows inflammatory granuloma in the dermis of patients with chronic infections [10–13], whereas it reveals dermis abscesses without granuloma in more acute forms [15]. Although cutaneous mucormycosis due to other species of *Mucorales* often causes disseminated disease, *M. irregularis* infection can be localized, as in this case. Nevertheless, progressive tissue invasion and dissemination should be assessed, given the vascular tropism of these aggressive fungi, especially in immunocompromised hosts. Liposomal amphotericin B, ≥ 5 mg/kg/day, is the optimal treatment of these destructive mycoses and monotherapy is recommended as first line treatment [18]. Posaconazole can be used as maintenance therapy, but some *Mucorales* species exhibit high MIC values to posaconazole. *M. irregularis* posaconazole MIC values are only rarely reported in the literature, but some authors reported MIC ranging from 0.25 to 2 μ g/ml using the microdilution reference method [12,19]. Caspofungin alone has no activity against *Mucorales*. However, it already showed a good synergistic

activity *in vitro* in combination with amphotericin B [20]. *In vivo* positive effect of Caspofungin was seldom observed and always in combination with other antifungal drugs. In this case, liposomal amphotericin B had to be stopped because of nephrotoxicity and the other therapeutic option, posaconazole, could not be used due to other MIC values.

Surgery probably had a major impact on the favorable outcome in this case, since amphotericin B could not be prolonged more than one month and limited cumulative dose of 1.1 g was administered. Surgery has not been systematically performed for *M. irregularis* infections in the literature (Table 1). The need for surgery seems to mainly depend on lesion extension and patient's overall condition. Hematological conditions, such as thrombocytopenia and neutropenia often increase risks associated with invasive procedures. Thus, neither of the two neutropenic cases had surgery to control the infection [15,16]. Extensive tissue debridement could be necessary to avoid progression, decrease fungal load, and allow for better diffusion of antifungal drugs through non-necrotic areas, especially in solid organ transplant recipients.

In our case, a healthcare-associated mucormycosis could not be ruled out. A recent literature review showed that 24% of the 169 patients with a healthcare-associated mucormycosis were solid organ recipients, 35% being kidney-transplanted [1]. Diabetes was a cofactor in 57% of SOT cases, as in our case. Furthermore, corticosteroids injections have already been associated with localized cutaneous mucormycosis [1]. Unfortunately we failed to demonstrate a link with steroids infiltrations or with the moisturizing cream used by the patient. However, the break in skin integrity due to the corticosteroid injection may have constituted a portal of entry for the *Mucorales* in the sub-cutaneous tissue.

Inappropriate skin disinfection prior to the injection could also have contributed to the infection. Other potential environmental sources such as water, with which the breached skin could have been in contact with, were not investigated. Water is indeed a potential reservoir for fungi that infection control specialists and clinicians should not underestimate [17]. This case also highlights the limitations associated with investigating an isolated case of suspected healthcare-associated invasive mucormycosis.

Conflict of interest statement

BR has received travel grants from Gilead Sciences and MSD. OL is a consultant for Gilead Sciences, and has received grants or speaker's fees from MSD, Roche, Astellas, Gilead Sciences and Pfizer. MEB has received travel grants or speaker's fees from Ademtech, MSD, Gilead Sciences, Astellas, and Pfizer. Other authors declared no conflict of interest.

Acknowledgments

We thank Dr. Anne Desjardins (Centre Hospitalier Universitaire de Québec; Hôtel-Dieu de Québec (CHUQ-HDQ), Université Laval) for her kindly review.

References

- [1] Ramaert B, Lanternier F, Zahar J-R, Dannaoui E, Bougnoux M-E, Lecuit M, et al. Healthcare-associated mucormycosis. *Clin Infect Dis* 2012;54:S44–54.
- [2] Pappas PG, Alexander BD, Andes DR, Hadley S, Kauffman CA, Freifeld A, et al. Invasive fungal infections among organ transplant recipients: results of the transplant-associated infection surveillance network (TRANSNET). *Clin Infect Dis* 2010;50:1101–11.
- [3] Petrikkos G, Skiada A, Lortholary O, Roilides E, Walsh TJ, Kontoyiannis DP. Epidemiology and clinical manifestations of mucormycosis. *Clin Infect Dis* 2012;54:S23–34.
- [4] Lanternier F, Dannaoui E, Morizot G, Elie C, Garcia-Hermoso D, Huerre M, et al. A global analysis of mucormycosis in France: the RetroZygo study (2005–2007). *Clin Infect Dis* 2012;54:S35–43.
- [5] White T, Bruns T, Lee S. Amplification and direct sequencing of fungal ribosomal RNA genes for phylogenetics. In: Innis A, Gelfand DH, Sninsky JJ, White TJ, editors. *PCR protocols: a guide to the methods and applications*. New York: Academic Press; 1990. p. 315–22.
- [6] Alvarez E, Cano J, Stchigel AM, Sutton DA, Fothergill AW, Salas V, et al. Two new species of *Mucor* from clinical samples. *Med Mycol* 2011;49:62–72.
- [7] Lu XL, Najafzadeh MJ, Dolatabadi S, Ran YP, Gerrits van den Ende AH, Shen YN, et al. Taxonomy and epidemiology of *Mucor irregularis*, agent of chronic cutaneous mucormycosis. *Persoonia* 2013;30:48–56.
- [8] Voigt K, Cigelnik E, O'donnell K. Phylogeny and PCR identification of clinically important Zygomycetes based on nuclear ribosomal-DNA sequence data. *J Clin Microbiol* 1999;37:3957–64.
- [9] Zhao Y, Zhang Q, Li L, Zhu J, Kang K, Chen L. Primary cutaneous mucormycosis caused by *Rhizomucor variabilis* in an immunocompetent patient. *Mycopathologia* 2009;168:243–7.
- [10] Lu X, Liu Z, Shen Y, She X, Lu G, Zhan P, et al. Primary cutaneous zygomycosis caused by *rhizomucor variabilis*: a new endemic zygomycosis? A case report and review of 6 cases reported from China *Clin Infect Dis* 2009;49:e39–43.
- [11] Li DM, Lun LD. *Mucor irregularis* infection and lethal midline granuloma: a case report and review of published literature. *Mycopathologia* 2012;174:429–39.
- [12] Hemashettar BM, Patil RN, O'Donnell K, Chaturvedi V, Ren P, Padhye AA. Chronic rhinofacial mucormycosis caused by *Mucor irregularis* (*Rhizomucor variabilis*) in India. *Clin Microbiol* 2011;49:2372–5.
- [13] Patil AB, Chandrmohan K, Shivaprakash MR, Nadgir SD, Lakshminarayana SA. *Rhizomucor variabilis*: a rare causative agent of primary cutaneous zygomycosis. *Indian J Med Microbiol* 2013;31:302–5.
- [14] Tomita H, Muroi E, Takenaka M, Nishimoto K, Kakeya H, Ohno H, et al. *Rhizomucor variabilis* infection in human cutaneous mucormycosis. *Clin Exp Dermatol* 2011;36:312–4.
- [15] Schell WA, O'Donnell K, Alspaugh JA. Heterothallic mating in *Mucor irregularis* and first isolate of the species outside of Asia. *Med Mycol* 2011;49:714–23.
- [16] Abuali MM, Posada R, Del Toro G, Roman E, Ramani R, Chaturvedi S, et al. *Rhizomucor variabilis* var. *regularior* and *Hormographiella aspergillata* infections in a leukemic bone marrow transplant recipient with refractory neutropenia. *J Clin Microbiol* 2009;47:4176–9.
- [17] Ribeiro NFF, Heath CH, Kierath J, Rea S, Duncan-Smith M, Wood FM. Burn wounds infected by contaminated water: case reports, review of the literature and recommendations for treatment. *Burns* 2010;36:9–22.
- [18] Skiada A, Lanternier F, Groll AH, Pagano L, Zimmerli S, Herbrecht R, et al. European conference on infections in leukemia. Diagnosis and treatment of mucormycosis in patients with hematological malignancies: guidelines from the 3rd European conference on infections in leukemia (ECIL 3). *Haematologica* 2013;98:492–504.
- [19] Alastruey-Izquierdo A, Castelli MV, Cuesta I, Monzon A, Cuenca-Estrella M, Rodriguez-Tudela JL. Activity of posaconazole and other antifungal agents against *Mucorales* strains identified by sequencing of internal transcribed spacers. *Antimicrob Agents Chemother* 2009;53:1686–9.
- [20] Zhang S, Li R, Yu J. Drug combinations against *Mucor irregularis* in vitro. *Antimicrob Agents Chemother* 2013;57:3395–7.