



HAL
open science

Recent advances in the understanding and management of mucormycosis

Benoît Pilmis, Alexandre Alanio, Olivier Lortholary, Fanny Lanternier

► To cite this version:

Benoît Pilmis, Alexandre Alanio, Olivier Lortholary, Fanny Lanternier. Recent advances in the understanding and management of mucormycosis. *F1000Research*, 2018, 7, pp.1429. 10.12688/f1000research.15081.1 . pasteur-02193174

HAL Id: pasteur-02193174

<https://pasteur.hal.science/pasteur-02193174>

Submitted on 24 Jul 2019

HAL is a multi-disciplinary open access archive for the deposit and dissemination of scientific research documents, whether they are published or not. The documents may come from teaching and research institutions in France or abroad, or from public or private research centers.

L'archive ouverte pluridisciplinaire **HAL**, est destinée au dépôt et à la diffusion de documents scientifiques de niveau recherche, publiés ou non, émanant des établissements d'enseignement et de recherche français ou étrangers, des laboratoires publics ou privés.



Distributed under a Creative Commons Attribution 4.0 International License



REVIEW

Recent advances in the understanding and management of mucormycosis [version 1; referees: 2 approved]

Benoit Pilmis^{1,2}, Alexandre Alanio³⁻⁵, Olivier Lortholary^{1,4,5}, Fanny Lanternier^{1,4,5}

¹Paris Descartes University, Sorbonne Paris Cité, Infectious Diseases Unit, Necker-Enfants Malades University Hospital, AP-HP, Imagine Institute, Paris, France

²Antimicrobial Stewardship Team, Microbiology Unit, Groupe Hospitalier Paris Saint Joseph, Paris, France

³Université Paris Diderot, Sorbonne Paris Cité, Laboratoire de Parasitologie-Mycologie, Hôpital Saint-Louis, Groupe Hospitalier Lariboisière, Saint-Louis, Fernand Widal, AP-HP, Paris, France

⁴Molecular Mycology Unit, Institut Pasteur, CNRS UMR2000, Paris, France

⁵Centre National de Référence Mycoses invasives et Antifongiques, Institut Pasteur, Paris, France

V1 First published: 07 Sep 2018, 7(F1000 Faculty Rev):1429 (doi: 10.12688/f1000research.15081.1)

Latest published: 07 Sep 2018, 7(F1000 Faculty Rev):1429 (doi: 10.12688/f1000research.15081.1)

Abstract

Mucormycoses were difficult-to-manage infections owing to limited diagnostic tools and therapeutic options. We review here advances in pathology understanding, diagnostic tools including computed tomography, and serum polymerase chain reaction and therapeutic options.

Keywords

Mucormycosis, Reverse Halo sign, PCR, Isavuconazole, Liposomal amphotericin B

Open Peer Review

Referee Status:

	Invited Referees	
	1	2
version 1 published 07 Sep 2018		

F1000 Faculty Reviews are commissioned from members of the prestigious F1000 Faculty. In order to make these reviews as comprehensive and accessible as possible, peer review takes place before publication; the referees are listed below, but their reports are not formally published.

- Arunaloke Chakrabarti**, Postgraduate Institute of Medical Education and Research, India
- Immaculata Xess**, All India Institute of Medical Sciences, India

Discuss this article

Comments (0)

Corresponding author: Fanny Lanternier (fanny.lanternier@aphp.fr)

Author roles: **Pilmis B:** Writing – Original Draft Preparation; **Alanio A:** Writing – Review & Editing; **Lortholary O:** Writing – Review & Editing; **Lanternier F:** Conceptualization, Supervision, Writing – Review & Editing

Competing interests: FL is a speaker for bureau Gilead, Basilea, MSD. Conculancy Basilea. She received research grant from Gilead Sciences. OL has been a consultant for Gilead Sciences, a speakers' bureau for Pfizer, Novartis, Astellas, Merck, and Gilead Sciences, and has received research grants from Gilead Sciences. AA has received travel grant from MSD, Gilead and Astella and honoraria from Pathoquest and Gilead outside the submitted work. BP has no competing interests to declare.

Grant information: The author(s) declared that no grants were involved in supporting this work.

Copyright: © 2018 Pilmis B *et al.* This is an open access article distributed under the terms of the [Creative Commons Attribution Licence](#), which permits unrestricted use, distribution, and reproduction in any medium, provided the original work is properly cited.

How to cite this article: Pilmis B, Alanio A, Lortholary O and Lanternier F. **Recent advances in the understanding and management of mucormycosis [version 1; referees: 2 approved]** *F1000Research* 2018, 7(F1000 Faculty Rev):1429 (doi: [10.12688/f1000research.15081.1](https://doi.org/10.12688/f1000research.15081.1))

First published: 07 Sep 2018, 7(F1000 Faculty Rev):1429 (doi: [10.12688/f1000research.15081.1](https://doi.org/10.12688/f1000research.15081.1))

Introduction

Mucormycoses are life-threatening fungal infections mostly occurring in hematology, solid organ transplant, or diabetic patients, it may also affect immunocompetent patients following a trauma or burn¹. Nosocomial or community outbreaks have been described². Mucormycosis is characterized by host tissue infarction and necrosis resulting from vasculature invasion by hyphae starting with a specific interaction with endothelial cells. Most common clinical presentations are rhino-orbito-cerebral and pulmonary. Multicenter and single-center studies have reported an increasing incidence probably due to an increase in the at-risk population and improved diagnostic tools^{3,4}. In a French study, mucormycosis incidence increased by 7.3% per year, especially in patients with neutropenia⁵.

These infections are difficult to manage for several reasons⁶. Firstly, diagnosis is difficult because of clinico-radiological similarities with invasive aspergillosis and historical lack of diagnostic tools. However, new tools in serum and tissue as well as the recognition of highly suggestive radiological signs recently modified diagnostic possibilities. Secondly, treatment is an emergency and combines surgery, which is frequently required owing to the angioinvasive and necrotic character of infection⁷, and antifungal treatment. Primary *in vitro* resistance to several antifungal drugs limits therapeutic options⁸. However, recent data enlarge the antifungal armamentarium with the US Food and Drug Administration's and European Medicines Agency's approval of the new triazole isavuconazole. However, comparative clinical data are lacking, and the respective places of polyenes and different azoles need to be discussed.

Moving towards improved mucormycosis understanding

Human mucormycoses are caused by a wide range of pathogenic species. Mucormycosis location is linked to the *mucorales* species; *Rhizopus arrhizus* (Figure 1) is present in 85% of rhino-cerebral forms, compared with only 17% of non-rhino-cerebral forms in the French RetroZygo study⁹. This finding could be explained by virulence differences between *Mucorales* species. In experimental studies, ketoacidosis has been found to predispose mice to *Rhizopus* spp. but not *Lichtheimia* spp. infection^{10,11}. In parallel, corticosteroid treatment enhanced the susceptibility of mice to lung infections caused by *Lichtheimia corymbifera* or *Lichtheimia ramosa*^{10,11}.

Mucormycosis' clinical presentation is also related to underlying conditions. Rhino-cerebral mucormycosis is the most common form in patients with diabetes mellitus¹, while pulmonary mucormycosis occurs most often in patients with hematological malignancies¹². Radiological findings in patients with pulmonary mucormycosis are also related to immunological status¹³. Although unusual, lately there have been diagnoses made in the gastrointestinal system. The stomach is more frequently involved, and then the colon. Symptoms are abdominal pain and gastro-intestinal bleeding¹⁴. Diagnosis is suspected on endoscopic findings with necrotic lesions that can lead to perforation and peritonitis¹⁵.

Mucorales can gain entry to a susceptible host through inhalation, ingestion of contaminated food, or abraded skin. These routes result in rhino-orbito-cerebral, pulmonary, gastrointestinal, or cutaneous/wound infections. One of the characteristic features of mucormycosis is its angioinvasive property, resulting in vascular thromboses and ultimately tissue necrosis. Ketoacidosis and deferoxamine are known to predispose to mucormycosis, revealing the importance of hyperglycemia, iron, and acidifying ketone bodies in *mucorales* virulence. Angioinvasion was reported to be related to the interaction between a spore-coating protein family (CotH) on *Rhizopus* spp. surface and endothelium glucose regulator protein 78 (GRP78) expressed at the surface of endothelial cells. This interaction triggers host cell injury and subsequent fungus hematogenous dissemination¹⁶. Elevated levels of serum glucose, iron, and ketone bodies increase fungal growth and induce the expression of GRP78 and CotH, resulting in increased ability of *Rhizopus* to invade host tissues and explaining the susceptibility of diabetic and deferoxamine-treated patients to mucormycosis. However, it should be noted that the majority of studies on virulence and the association between ketoacidosis and the occurrence of mucormycosis have been conducted with *Rhizopus* species¹⁷. Decreased numbers and impaired function of monocytes and neutrophils are important mucormycosis risk factors, since they are known to inhibit *Mucorales* spore germination. This includes patients with hematological disorders, AIDS, or liver cirrhosis, those who have undergone solid organ transplant, and those being treated with high-dose steroids^{18,19}. Finally, victims of natural disaster are also at risk²⁰ owing to wounds contaminated with water, soil, or debris²¹, such as after the 2004 Indian Ocean tsunami²² or after the 2011 Missouri tornado²³.

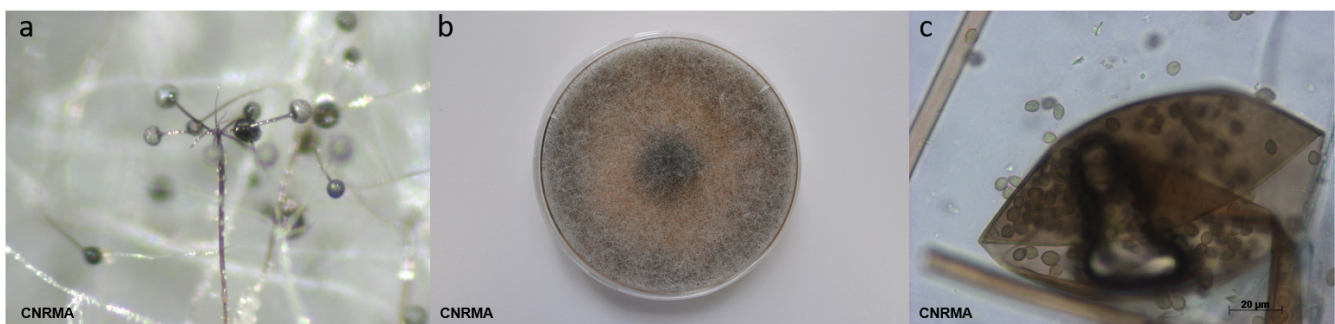

Figure 1. Typical features of *Rhizopus arrhizus*. (a) Sporangiophore branching and rhizoids (stereomicroscope); (b) grey-brownish colony on malt 2% medium; (c) melanized sporangium and sporangiospores.

Computed tomography

The most common radiological pattern of lung mucormycosis on initial computed tomography (CT) scan is a halo sign and then nodule or mass^{13,24}. However, when studied very early and on serial follow-up, sequential morphologic changes could be observed as (i) reversed halo sign (Figure 2) followed by (ii) consolidation or nodule or mass with halo sign and, finally, (iii) central necrosis and air-crescent sign. For pulmonary mucormycosis, a recent study showed that there was a significant increase in the prevalence of reversed halo sign in neutropenic (79%) and non-neutropenic (31%) patients ($P < 0.05$)²⁵.

Major steps in mucormycosis: towards earlier diagnosis (Figure 3)

Mucormycosis diagnosis is challenging, as it is associated with high mortality, especially in hematological patients. Early distinction from invasive aspergillosis is of utmost importance, as antifungal treatment may differ, whereas underlying conditions and clinical presentation are often similar. Until recently, mucormycosis diagnostic tools were based on limited basic microbiology and frequently led to diagnosis delay.

Unlike invasive aspergillosis, the detection of circulating antigen such as galactomannan and β -D-1,3-glucan provides no help for mucormycosis diagnosis. Therefore, samples from the infection site are highly required to diagnose mucormycosis based on the microscopic detection of typical hyphae or on a

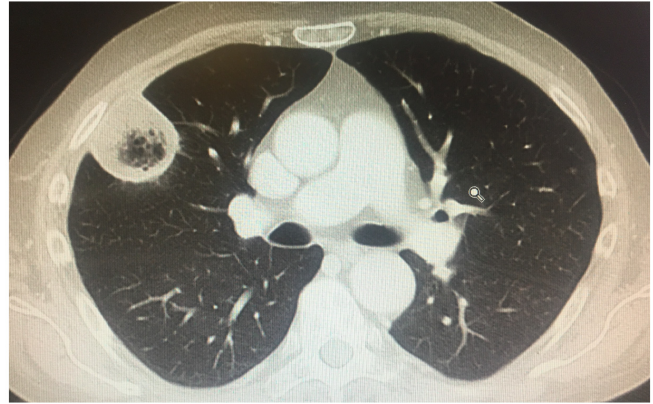


Figure 2. Inversed halo sign. Inversed halo sign.

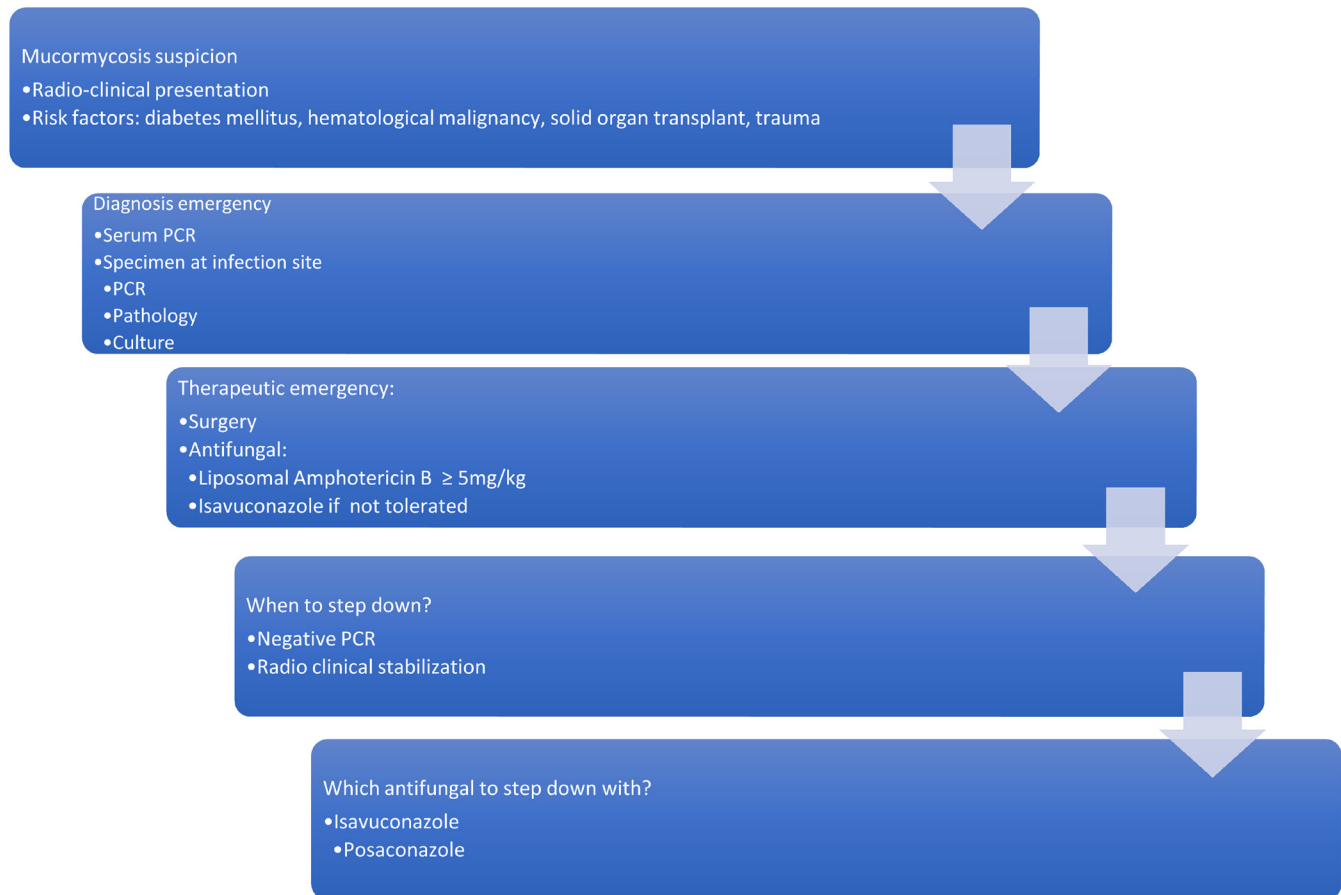

Figure 3. Mucormycosis: from suspicion to treatment. PCR, polymerase chain reaction.

positive culture²⁶. Recently, the development of molecular biology tools has allowed the non-invasive diagnosis of mucormycosis. Million *et al.* designed a quantitative multiplex polymerase chain reaction (qPCR)-based 18S rRNA targeting *Mucor/Rhizopus*, *Lichtheimia*, and *Rhizomucor*. This PCR assay was evaluated with the aim to detect *Mucorales* DNA early in the course of the infection in the blood (serum)²⁷. The authors were able to detect *Mucorales* DNA in serum samples from 90% of patients up to three days before mucormycosis diagnosis²⁷. Negative serum PCR was also associated with better outcome as compared to patients with persistently positive PCR. Furthermore, a study among severely ill burn patients found that circulating *Mucorales* DNA was detected 11 (4.5–15) days before standard diagnosis for invasive wound mucormycosis²⁸. Other studies have evaluated the use of real-time PCR targeting *Mucorales* on tissue or respiratory samples in patients with hematological malignancy suffering from proven and probable mucormycosis^{29–32}.

Consequently, it is currently necessary in patients with hematological malignancies to include the value of reverse halo sign on CT combined with serum qPCR targeting *Mucorales* in the early diagnosis of pulmonary mucormycosis³³.

Several antifungals now available for mucormycosis treatment

Mucormycoses: an indication of emergency surgery

Current guidelines recommend antifungal treatment, surgical debridement, and correction of risk factors^{34,35}. Surgical debridement has to be extensive, involving all necrotic areas for rhino-oculo-cerebral infection, and repeated surgical procedures are recommended to achieve local control and improve outcome³⁶. For pulmonary mucormycosis, the indication and timing of surgical management outside emergency care (hemoptysis) is still unclear³⁷. In a European series of 230 patients, surgical treatment reduced mortality by 79%³⁸, leading to discuss surgery when feasible for any localization, however mandatory for rhino-cerebro-oculo-cerebral and post-traumatic mucormycosis^{36,39}.

Antifungal treatment

Amphotericin B (Amb) and its lipid formulations and posaconazole were the only antifungal drugs available with *in vitro* activity against *mucorales*^{40,41}. The antifungal armamentarium recently enlarged with the development of isavuconazole.

The first-line recommended antifungal agent is liposomal Amb (L-Amb) or Amb lipid complex (ABLC)³⁵. Studies in mice proposed that the efficacy of L-Amb and ABLC was dependent on the dose given and that 10 mg/kg yielded the best outcomes. A prospective French phase II multicenter study (AmBizygo trial) evaluated the efficacy and tolerance of high-dose (10 mg/kg/day) L-Amb in association with surgery when recommended for the treatment of 34 mucormycosis cases. A favorable response was seen in 45% of patients at week 12. However, serum creatinine doubled in 40% of patients, but in 63% of cases, once treatment had ended, creatinine levels normalized after three months⁴². According to this study, ECMM/ESCMID

and ECIL-6 guidelines recommend the use of L-Amb with a daily dosage of at least 5 mg/kg/day for mucormycosis^{34,35}, and dosages at 10 mg/kg/day are strongly supported by ECMM/ESCMID for cerebral infections³⁵. Moreover, because of better diffusion, L-Amb should be favored in central nervous system infections.

The duration of the first-line antifungal treatment is still a matter of debate and should be determined on an individual basis and adjusted based on the underlying condition. Some authors proposed a lipid Amb treatment for at least three weeks, and, when there is clinical and radiological improvement, a consolidation by posaconazole can be started⁴³. However, it could possibly be guided by negative PCR and therefore shortened for some patients.

Isavuconazonium sulfate is a water-soluble pro-drug, which is quickly hydrolyzed to the triazole isavuconazole after oral or intravenous administration. Isavuconazole has high oral bioavailability, linear pharmacokinetics, and a broad antifungal spectrum. The *in vitro* activity of isavuconazole minimum inhibitory concentration (MIC) ranges were 0.125 to 4 mg/L across *L. corymbifera*, *L. ramosa*, *Rhizomucor pusillus*, *Rhizomucor microspores*, and *R. arrhizus* but somewhat higher against *Mucor circinelloides* (1 to 16 mg/L). The MICs were in general one- to three-fold higher than those for posaconazole⁴⁴. In the recently published Vital study, 21 patients were treated with isavuconazole as first-line treatment; 42-day response rate was only 14% and week 12 response was 10% (compared to 45% in the AmBizygo study) with 43% deaths⁴⁵. The results of this study found a mortality rate at day 42 comparable to that observed in the AmBizygo study⁴². In the VITAL study, isavuconazole was well tolerated and toxic effects were an uncommon cause of discontinuation. The place of isavuconazole has not yet been specified in the most recent guidelines³⁴. Finally, a cost-effectiveness study demonstrated the positive economic impact of the use of isavuconazole compared to Amb in the treatment of mucormycosis⁴⁶.

Posaconazole has been shown to have *in vitro* and *in vivo* activity against *mucorales*, but there are no data for the use of first-line posaconazole therapy. Posaconazole, therefore, finds its place in the therapeutic armamentarium for prophylaxis or consolidation after induction treatment with L-Amb. No study on the efficacy of posaconazole intravenous or tablet formulations in mucormycosis treatment were conducted. Finally, mucormycosis cases have been reported in patients undergoing posaconazole prophylaxis despite satisfactory serum concentrations⁴⁷.

However, it seems important to note that there are no current validated MIC breakpoints for any of the available antifungals and thus the determination of susceptibility categories is not possible for the agents of mucormycosis.

Immunostimulating drugs

A case report has recently reported the benefit of a treatment with the checkpoint inhibitor nivolumab and interferon- γ for an

immunocompetent patient with extensive abdominal mucormycosis unresponsive to conventional therapy⁴⁸.

Conclusion

Mucormycosis is a life-threatening fungal infection characterized by host tissue infarction and necrosis that occurs mostly in immunocompromised patients and is associated with an increasing incidence and mortality despite the availability of therapeutic tools. Determining whether the patient has invasive aspergillosis or mucormycosis could be challenging at the bedside. In this context, new tools of molecular biology have been developed to obtain earlier diagnosis and start optimal

medico-surgical treatment. Comparative studies are needed to better optimize induction and consolidation treatment.

Grant information

The author(s) declared that no grants were involved in supporting this work.

Acknowledgements

Thanks to Dea Garcia-Hermoso for reading the manuscript and providing strain photographs.

References



- Roden MM, Zaoutis TE, Buchanan WL, *et al.*: **Epidemiology and outcome of zygomycosis: a review of 929 reported cases.** *Clin Infect Dis.* 2005; **41**(5): 634–53.
[PubMed Abstract](#) | [Publisher Full Text](#)
- Alanio A, Desnos-Ollivier M, Garcia-Hermoso D, *et al.*: **Investigating Clinical Issues by Genotyping of Medically Important Fungi: Why and How?** *Clin Microbiol Rev.* 2017; **30**(3): 671–707.
[PubMed Abstract](#) | [Publisher Full Text](#) | [Free Full Text](#)
- Bitar D, Van Cauteren D, Lanternier F, *et al.*: **Increasing incidence of zygomycosis (mucormycosis), France, 1997-2006.** *Emerg Infect Dis.* 2009; **15**(9): 1395–401.
[PubMed Abstract](#) | [Publisher Full Text](#) | [Free Full Text](#) | **F1000 Recommendation**
- Guinea J, Escribano P, Vena A, *et al.*: **Increasing incidence of mucormycosis in a large Spanish hospital from 2007 to 2015: Epidemiology and microbiological characterization of the isolates.** *PLoS One.* 2017; **12**(6): e0179136.
[PubMed Abstract](#) | [Publisher Full Text](#) | [Free Full Text](#) | **F1000 Recommendation**
- Bitar D, Lortholary O, Le Strat Y, *et al.*: **Population-based analysis of invasive fungal infections, France, 2001-2010.** *Emerg Infect Dis.* 2014; **20**(7): 1149–55.
[PubMed Abstract](#) | [Publisher Full Text](#) | [Free Full Text](#) | **F1000 Recommendation**
- Ribes JA, Vanover-Sams CL, Baker DJ: **Zygomycetes in human disease.** *Clin Microbiol Rev.* 2000; **13**(2): 236–301.
[PubMed Abstract](#) | [Publisher Full Text](#) | [Free Full Text](#)
- Katragkou A, Walsh TJ, Roidides E: **Why is mucormycosis more difficult to cure than more common mycoses?** *Clin Microbiol Infect.* 2014; **20** Suppl 6: 74–81.
[PubMed Abstract](#) | [Publisher Full Text](#)
- Dannaoui E: **Antifungal resistance in mucorales.** *Int J Antimicrob Agents.* 2017; **50**(5): 617–21.
[PubMed Abstract](#) | [Publisher Full Text](#)
- Lanternier F, Dannaoui E, Morizot G, *et al.*: **A global analysis of mucormycosis in France: the RetroZygo Study (2005-2007).** *Clin Infect Dis.* 2012; **54** Suppl 1: S35–43.
[PubMed Abstract](#) | [Publisher Full Text](#) | **F1000 Recommendation**
- Ibrahim AS, Spellberg B, Walsh TJ, *et al.*: **Pathogenesis of mucormycosis.** *Clin Infect Dis.* 2012; **54** Suppl 1: S16–22.
[PubMed Abstract](#) | [Publisher Full Text](#) | [Free Full Text](#)
- Spellberg B, Edwards J Jr, Ibrahim A: **Novel perspectives on mucormycosis: pathophysiology, presentation, and management.** *Clin Microbiol Rev.* 2005; **18**(3): 556–69.
[PubMed Abstract](#) | [Publisher Full Text](#) | [Free Full Text](#)
- Tedder M, Spratt JA, Anstadt MP, *et al.*: **Pulmonary mucormycosis: results of medical and surgical therapy.** *Ann Thorac Surg.* 1994; **57**(4): 1044–50.
[PubMed Abstract](#) | [Publisher Full Text](#)
- Nam BD, Kim TJ, Lee KS, *et al.*: **Pulmonary mucormycosis: serial morphologic changes on computed tomography correlate with clinical and pathologic findings.** *Eur Radiol.* 2018; **28**(2): 788–95.
[PubMed Abstract](#) | [Publisher Full Text](#) | **F1000 Recommendation**
- Diaverti MV, Cawcutt KA, Abidi M, *et al.*: **Gastrointestinal mucormycosis in immunocompromised hosts.** *Mycoses.* 2015; **58**(12): 714–8.
[PubMed Abstract](#) | [Publisher Full Text](#)
- Singh N, Gayowski T, Singh J, *et al.*: **Invasive gastrointestinal zygomycosis in a liver transplant recipient: case report and review of zygomycosis in solid-organ transplant recipients.** *Clin Infect Dis.* 1995; **20**(3): 617–20.
[PubMed Abstract](#) | [Publisher Full Text](#)
- Baldin C, Ibrahim AS: **Molecular mechanisms of mucormycosis-The bitter and the sweet.** *PLoS Pathog.* 2017; **13**(8): e1006408.
[PubMed Abstract](#) | [Publisher Full Text](#) | [Free Full Text](#) | **F1000 Recommendation**
- Spellberg B: **Mucormycosis pathogenesis: Beyond *Rhizopus*.** *Virulence.* 2017; **8**(8): 1481–2.
[PubMed Abstract](#) | [Publisher Full Text](#) | [Free Full Text](#)
- Xhaard A, Lanternier F, Porcher R, *et al.*: **Mucormycosis after allogeneic haematopoietic stem cell transplantation: a French Multicentre Cohort Study (2003-2008).** *Clin Microbiol Infect.* 2012; **18**(10): E396–400.
[PubMed Abstract](#) | [Publisher Full Text](#)
- Pana ZD, Seidel D, Skiada A, *et al.*: **Invasive mucormycosis in children: an epidemiologic study in European and non-European countries based on two registries.** *BMC Infect Dis.* 2016; **16**(1): 667.
[PubMed Abstract](#) | [Publisher Full Text](#) | [Free Full Text](#)
- Benedict K, Park BJ: **Invasive fungal infections after natural disasters.** *Emerg Infect Dis.* 2014; **20**(3): 349–55.
[PubMed Abstract](#) | [Publisher Full Text](#) | [Free Full Text](#) | **F1000 Recommendation**
- Ivers LC, Ryan ET: **Infectious diseases of severe weather-related and flood-related natural disasters.** *Curr Opin Infect Dis.* 2006; **19**(5): 408–14.
[PubMed Abstract](#) | [Publisher Full Text](#)
- Andresen D, Donaldson A, Choo L, *et al.*: **Multifocal cutaneous mucormycosis complicating polymicrobial wound infections in a tsunami survivor from Sri Lanka.** *Lancet.* 2005; **365**(9462): 876–8.
[PubMed Abstract](#) | [Publisher Full Text](#)
- Neblett Fanfair R, Benedict K, Bos J, *et al.*: **Necrotizing cutaneous mucormycosis after a tornado in Joplin, Missouri, in 2011.** *N Engl J Med.* 2012; **367**(23): 2214–25.
[PubMed Abstract](#) | [Publisher Full Text](#) | **F1000 Recommendation**
- Legouge C, Caillot D, Chrétien ML, *et al.*: **The reversed halo sign: pathognomonic pattern of pulmonary mucormycosis in leukemic patients with neutropenia?** *Clin Infect Dis.* 2014; **58**(5): 672–8.
[PubMed Abstract](#) | [Publisher Full Text](#) | **F1000 Recommendation**
- Bourcier J, Heudes PM, Morio F, *et al.*: **Prevalence of the reversed halo sign in neutropenic patients compared with non-neutropenic patients: Data from a single-centre study involving 27 patients with pulmonary mucormycosis (2003-2016).** *Mycoses.* 2017; **60**(8): 526–33.
[PubMed Abstract](#) | [Publisher Full Text](#) | **F1000 Recommendation**
- Garcia-Hermoso D, Alanio A, Lortholary O, *et al.*: **Agents of Systemic and Subcutaneous Mucormycosis and Entomophthoromycosis.** In: *Manual of Clinical Microbiology, 11th.* Pfaller MA, Richter SS, Funke G, Jorgensen JH, Landry ML, Carroll KC, *et al.*, editors, 2015; 2087–108.
[Publisher Full Text](#)
- Millon L, Herbrecht R, Grenouillet F, *et al.*: **Early diagnosis and monitoring of mucormycosis by detection of circulating DNA in serum: retrospective analysis of 44 cases collected through the French Surveillance Network of Invasive Fungal Infections (RESSIF).** *Clin Microbiol Infect.* 2016; **22**(9): 810.e1–810.e8.
[PubMed Abstract](#) | [Publisher Full Text](#) | **F1000 Recommendation**
- Legrand M, Gits-Muselli M, Boutin L, *et al.*: **Detection of Circulating Mucorales DNA in Critically Ill Burn Patients: Preliminary Report of a Screening Strategy**

- for Early Diagnosis and Treatment. *Clin Infect Dis*. 2016; 63(10): 1312–7.
[PubMed Abstract](#) | [Publisher Full Text](#)
29. Alanio A, Garcia-Hermoso D, Mercier-Delarue S, *et al.*: Molecular identification of *Mucorales* in human tissues: contribution of PCR electrospray-ionization mass spectrometry. *Clin Microbiol Infect*. 2015; 21(6): 594.e1–5.
[PubMed Abstract](#) | [Publisher Full Text](#)
30. **F** Springer J, White PL, Kessel J, *et al.*: A Comparison of *Aspergillus* and *Mucorales* PCR Testing of Different Bronchoalveolar Lavage Fluid Fractions from Patients with Suspected Invasive Pulmonary Fungal Disease. *J Clin Microbiol*. 2018; 56(2): pii: e01655-17.
[PubMed Abstract](#) | [Publisher Full Text](#) | [Free Full Text](#) | [F1000 Recommendation](#)
31. Springer J, Lackner M, Ensinger C, *et al.*: Clinical evaluation of a *Mucorales*-specific real-time PCR assay in tissue and serum samples. *J Med Microbiol*. 2016; 65(12): 1414–21.
[PubMed Abstract](#) | [Publisher Full Text](#)
32. Zaman K, Rudramurthy SM, Das A, *et al.*: Molecular diagnosis of rhino-orbito-cerebral mucormycosis from fresh tissue samples. *J Med Microbiol*. 2017; 66(8): 1124–9.
[PubMed Abstract](#) | [Publisher Full Text](#)
33. **F** Caillot D, Valot S, Lafon I, *et al.*: Is It Time to Include CT “Reverse Halo Sign” and qPCR Targeting *Mucorales* in Serum to EORTC-MSG Criteria for the Diagnosis of Pulmonary Mucormycosis in Leukemia Patients? *Open Forum Infect Dis*. 2016; 3(4): ofw190.
[PubMed Abstract](#) | [Publisher Full Text](#) | [Free Full Text](#) | [F1000 Recommendation](#)
34. **F** Tissot F, Agrawal S, Pagano L, *et al.*: ECIL-6 guidelines for the treatment of invasive candidiasis, aspergillosis and mucormycosis in leukemia and hematopoietic stem cell transplant patients. *Haematologica*. 2017; 102(3): 433–44.
[PubMed Abstract](#) | [Publisher Full Text](#) | [Free Full Text](#) | [F1000 Recommendation](#)
35. **F** Cornely OA, Arikan-Akdagli S, Dannaoui E, *et al.*: ESCMID and ECMM joint clinical guidelines for the diagnosis and management of mucormycosis 2013. *Clin Microbiol Infect*. 2014; 20 Suppl 3: 5–26.
[PubMed Abstract](#) | [Publisher Full Text](#) | [F1000 Recommendation](#)
36. Vironneau P, Kania R, Morizot G, *et al.*: Local control of rhino-orbito-cerebral mucormycosis dramatically impacts survival. *Clin Microbiol Infect*. 2014; 20(5): Q336–9.
[PubMed Abstract](#) | [Publisher Full Text](#)
37. Chretien ML, Legouge C, Pagès PB, *et al.*: Emergency and elective pulmonary surgical resection in haematological patients with invasive fungal infections: a report of 50 cases in a single centre. *Clin Microbiol Infect*. 2016; 22(9): 782–7.
[PubMed Abstract](#) | [Publisher Full Text](#)
38. Skiada A, Pagano L, Groll A, *et al.*: Zygomycosis in Europe: analysis of 230 cases accrued by the registry of the European Confederation of Medical Mycology (ECMM) Working Group on Zygomycosis between 2005 and 2007. *Clin Microbiol Infect*. 2011; 17(12): 1859–67.
[PubMed Abstract](#) | [Publisher Full Text](#)
39. Lelievre L, Garcia-Hermoso D, Abdoul H, *et al.*: Posttraumatic mucormycosis: a nationwide study in France and review of the literature. *Medicine (Baltimore)*. 2014; 93(24): 395–404.
[PubMed Abstract](#) | [Publisher Full Text](#) | [Free Full Text](#)
40. **F** Sabatelli F, Patel R, Mann PA, *et al.*: In vitro activities of posaconazole, fluconazole, itraconazole, voriconazole, and amphotericin B against a large collection of clinically important molds and yeasts. *Antimicrob Agents Chemother*. 2006; 50(6): 2009–15.
[PubMed Abstract](#) | [Publisher Full Text](#) | [Free Full Text](#) | [F1000 Recommendation](#)
41. **F** Almyroudis NG, Sutton DA, Fothergill AW, *et al.*: In vitro susceptibilities of 217 clinical isolates of zygomycetes to conventional and new antifungal agents. *Antimicrob Agents Chemother*. 2007; 51(7): 2587–90.
[PubMed Abstract](#) | [Publisher Full Text](#) | [Free Full Text](#) | [F1000 Recommendation](#)
42. Lanternier F, Poiree S, Elie C, *et al.*: Prospective pilot study of high-dose (10 mg/kg/day) liposomal amphotericin B (L-AMB) for the initial treatment of mucormycosis. *J Antimicrob Chemother*. 2015; 70(11): 3116–23.
[PubMed Abstract](#) | [Publisher Full Text](#)
43. Kontoyannis DP, Lewis RE: How I treat mucormycosis. *Blood*. 2011; 118(5): 1216–24.
[PubMed Abstract](#) | [Publisher Full Text](#) | [Free Full Text](#)
44. **F** Lamoth F, Chung SJ, Damonti L, *et al.*: Changing Epidemiology of Invasive Mold Infections in Patients Receiving Azole Prophylaxis. *Clin Infect Dis*. 2017; 64(11): 1619–21.
[PubMed Abstract](#) | [Publisher Full Text](#) | [F1000 Recommendation](#)
45. **F** Marty FM, Ostrosky-Zeichner L, Cornely OA, *et al.*: Isavuconazole treatment for mucormycosis: a single-arm open-label trial and case-control analysis. *Lancet Infect Dis*. 2016; 16(7): 828–37.
[PubMed Abstract](#) | [Publisher Full Text](#) | [F1000 Recommendation](#)
46. **F** Bagshaw E, Kuessner D, Posthumus J, *et al.*: The cost of treating mucormycosis with isavuconazole compared with standard therapy in the UK. *Future Microbiol*. 2017; 12(6): 515–25.
[PubMed Abstract](#) | [Publisher Full Text](#) | [F1000 Recommendation](#)
47. Kang SH, Kim HS, Bae MN, *et al.*: Fatal Breakthrough Mucormycosis in an Acute Myelogenous Leukemia Patient while on Posaconazole Prophylaxis. *Infect Chemother*. 2015; 47(1): 49–54.
[PubMed Abstract](#) | [Publisher Full Text](#) | [Free Full Text](#)
48. Grimaldi D, Pradier O, Hotchkiss RS, *et al.*: Nivolumab plus interferon- γ in the treatment of intractable mucormycosis. *Lancet Infect Dis*. 2017; 17(1): 18.
[PubMed Abstract](#) | [Publisher Full Text](#)

Open Peer Review

Current Referee Status:  

Editorial Note on the Review Process

F1000 Faculty Reviews are commissioned from members of the prestigious F1000 Faculty and are edited as a service to readers. In order to make these reviews as comprehensive and accessible as possible, the referees provide input before publication and only the final, revised version is published. The referees who approved the final version are listed with their names and affiliations but without their reports on earlier versions (any comments will already have been addressed in the published version).

The referees who approved this article are:

Version 1

- 1 **Immaculata Xess** Department of Microbiology, All India Institute of Medical Sciences, Delhi, India
Competing Interests: No competing interests were disclosed.
- 2 **Arunaloke Chakrabarti** Department of Medical Microbiology, Postgraduate Institute of Medical Education and Research, Chandigarh, India
Competing Interests: No competing interests were disclosed.

The benefits of publishing with F1000Research:

- Your article is published within days, with no editorial bias
- You can publish traditional articles, null/negative results, case reports, data notes and more
- The peer review process is transparent and collaborative
- Your article is indexed in PubMed after passing peer review
- Dedicated customer support at every stage

For pre-submission enquiries, contact research@f1000.com

F1000Research