



**HAL**  
open science

# Novel DSP Spectrin 6 Region Variant Causes Neonatal Erythroderma, Failure to Thrive, Severe Herpes Simplex Infections and Brain Lesions

Svetlana Vakkilainen, Laura Puhakka, Paula Klemetti, Kaarina Heiskanen, Mikko Seppänen, Mikko Muona, Céline Posseme, Darragh Duffy, Timo Vaisanen, Outi Elomaa, et al.

## ► To cite this version:

Svetlana Vakkilainen, Laura Puhakka, Paula Klemetti, Kaarina Heiskanen, Mikko Seppänen, et al.. Novel DSP Spectrin 6 Region Variant Causes Neonatal Erythroderma, Failure to Thrive, Severe Herpes Simplex Infections and Brain Lesions. *Acta Dermato-Venereologica*, 2019, 10.2340/00015555-3203 . pasteur-02173489

**HAL Id: pasteur-02173489**

**<https://pasteur.hal.science/pasteur-02173489>**

Submitted on 4 Jul 2019

**HAL** is a multi-disciplinary open access archive for the deposit and dissemination of scientific research documents, whether they are published or not. The documents may come from teaching and research institutions in France or abroad, or from public or private research centers.

L'archive ouverte pluridisciplinaire **HAL**, est destinée au dépôt et à la diffusion de documents scientifiques de niveau recherche, publiés ou non, émanant des établissements d'enseignement et de recherche français ou étrangers, des laboratoires publics ou privés.



Distributed under a Creative Commons Attribution - NonCommercial 4.0 International License

# Novel *DSP* Spectrin 6 Region Variant Causes Neonatal Erythroderma, Failure to Thrive, Severe Herpes Simplex Infections and Brain Lesions

Svetlana VAKKILAINEN<sup>1#</sup>, Laura PUHAKKA<sup>1#</sup>, Paula KLEMETTI<sup>1</sup>, Kaarina HEISKANEN<sup>1</sup>, Mikko SEPPÄNEN<sup>2</sup>, Mikko MUONA<sup>3,4</sup>, Celine POSSEME<sup>5</sup>, Darragh DUFFY<sup>5</sup>, Timo VÄISÄNEN<sup>6,7</sup>, Outi ELOMAA<sup>8</sup>, Maarit PALOMÄK<sup>9</sup>, Harri SAXÉN<sup>1</sup>, Annamari RANKI<sup>10</sup> and Katariina HANNULA-JOUPPI<sup>8,10</sup>

<sup>1</sup>New Children's Hospital, University of Helsinki and Helsinki University Hospital, <sup>2</sup>Rare Disease Center, New Children's Hospital, University of Helsinki and Helsinki University Hospital, <sup>3</sup>Blueprint Genetics, <sup>4</sup>Folkhälsan Research Center, Helsinki, Finland, <sup>5</sup>Immunobiology of Dendritic Cells, Inserm U1223, Institut Pasteur, Paris, France, <sup>6</sup>Department of Pathology, Cancer and Translational Medicine Research Unit, University of Oulu, <sup>7</sup>Department of Pathology, Oulu University Hospital, Oulu, <sup>8</sup>Stem Cells and Metabolism Research Program, University of Helsinki and Folkhälsan Research Center, <sup>9</sup>Department of Radiology, Helsinki Medical Imaging Center, Helsinki University Hospital, and <sup>10</sup>Department of Dermatology and Allergology, University of Helsinki and Helsinki University Hospital, Helsinki, Finland

<sup>#</sup>These authors contributed equally and should be considered as first authors.

***Desmoplakin (DSP)* and *Desmoglein 1 (DSG1)* variants result in skin barrier defects leading to erythroderma, palmoplantar keratoderma and variable other features. Some *DSG1* variant carriers present with SAM syndrome (Severe dermatitis, multiple Allergies, Metabolic wasting) and a SAM-like phenotype has been reported in 4 subjects with different heterozygous *DSP* variants. We report here a patient with a novel *DSP* spectrin region (SR) 6 variant c.1756C>T, p.(His586Tyr), novel features of brain lesions and severe recurrent mucocutaneous herpes simplex virus infections, with a favourable response to ustekinumab. Through a review of reported cases of heterozygous variants in *DSP* SR6 (*n* = 15) and homozygous or compound heterozygous variants in *DSG1* (*n* = 12) and SAM-like phenotype, we highlight phenotypic variability. Woolly hair, nail abnormalities and cardiomyopathy characterize patients with *DSP* variants, while elevated immunoglobulin E and food allergies are frequent in patients with *DSG1* variants. Clinicians should be aware of the diverse manifestations of desmosomopathies.**

**Key words:** desmoglein; desmoplakin; metabolic wasting; SAM syndrome; severe dermatitis.

Accepted Apr 29, 2019; E-published Apr 29, 2019

Acta Derm Venereol 2019; XX: XX-XX.

**Corr:** Svetlana Vakkilainen, New Children's Hospital, University of Helsinki and Helsinki University Hospital, Stenbäckinkatu 9, FIN-00290 Helsinki, Finland. E-mail: svetlana.vakkilainen@hus.fi

**D**esmoplakin and desmogleins form the integral parts of desmosomes, which are adhesive intercellular junctions crucial in tissues prone to mechanical stress (e.g. skin, heart, gastrointestinal mucosa) (1). Desmosomal proteins play a role in cell signalling and skin barrier function.

*Desmoglein 1 (DSG1)* and *Desmoplakin (DSP)* encode critical components of desmosomes, and pathogenic variants in both genes have been implicated in inflammatory skin disorders. *DSG1* variants have been reported recently in patients with designated SAM syndrome

## SIGNIFICANCE

*Desmoplakin (DSP)* and *Desmoglein 1 (DSG1)* gene changes result in skin barrier defects leading to widespread red scaly rash, skin thickening on the palms and soles and variable other features. We report here a patient with a novel *DSP* gene change, novel features of brain lesions and severe viral infections, and a favourable response to treatment with ustekinumab. Woolly hair, nail abnormalities and heart problems characterize patients with *DSP* gene changes, while elevated serum IgE levels and food allergies are frequent in patients with *DSG1* gene changes. Clinicians should be aware of the diverse consequences of *DSP* and *DSG1* gene abnormalities.

(Severe dermatitis, multiple Allergies and Metabolic wasting) with an extremely variable phenotype consisting of severe erythrodermic dermatitis, failure to thrive (FTT), recurrent infections, metabolic wasting, multiple allergies, increased immunoglobulin (Ig) E levels and eosinophilia (2–7).

Two patients with different heterozygous *DSP* variants were reported to have a SAM-like phenotype (8, 9). Autosomal dominant *DSP* variants within the same spectrin 6 (SR6) region also cause erythrokeratoderma and cardiomyopathy (10), and palmoplantar keratoderma (PPK) with woolly hair, cardiomyopathy and arrhythmias (11). Recently, 2 additional patients with heterozygous *DSP* SR6 variants have been reported to display SAM syndrome, together with ectodermal dysplasia and cardiomyopathy (coined SAMEC syndrome) (12).

The lack of epithelial barrier proteins commonly seems to lead to immunological dysregulation. Impaired epithelial barrier function enhances Th2 responses and leads to chronic activation of the immune system (13). *DSG1* deficiency results in increased expression of various genes encoding cytokines involved in allergic manifestations, such as *IL5* and *TNF* (2). In SAMEC, *DSG1* was linked to an inability to retain ERBB2-interacting protein (ERBIN) at the cell membrane, probably hampering NF-κB pathway inhibition and promoting epithelial

inflammation (12). Heterozygous *DSP* variants associate with abnormally high levels of proinflammatory cytokines (interleukin (IL) 6, IL-8, and IL-1 $\beta$ ), NF- $\kappa$ B target gene products, and thymic stromal lymphoprotein in the keratinocytes (12). The dysregulated epidermal immune environment triggers early-onset allergic manifestations beyond the skin, including asthma and allergic rhinoconjunctivitis, as well as eosinophilic oesophagitis and colitis similar to patients with Netherton syndrome (14).

Desmoplakin anchors intermediate filaments to desmosomal plaques and is expressed at high levels in the skin and heart muscle, and at medium levels in bronchi and oesophagus (15). Importantly, individuals with *DSP* and other desmosomal gene variants are at risk of developing cardiomyopathy and lethal arrhythmias, typically at the age of 3–12 years (16), warranting continuous cardiac follow-up.

We report here a patient with a novel *DSP* SR6 region variant (c.1756C>T, p.His586Tyr), presenting with erythrodermic ichthyosis, severe FTT, oesophagitis, recurrent infections, and novel features, such as severe recurrent mucocutaneous herpes simplex virus (HSV) infections, pyogenic granuloma on the tongue, gastritis and brain lesions, further diversifying the *DSP*-related phenotype. We also reviewed all reported patients with heterozygous variants in *DSP* SR6 and with homozygous or compound heterozygous variants in *DSG1* and *SAM/SAMEC*-like phenotype, in order to delineate variable and overlapping clinical features.

## METHODS

Written informed consent was obtained from the patient's parents, including permission to publish the photographs.

The immunological assessment, skin histopathology and immunohistochemistry, hair analysis, oesophagus and gastric biopsies, whole-exome sequencing and variant analysis, protein modelling, as well as literature search and statistical analyses, are described in detail in Appendix S1<sup>1</sup>.

## RESULTS

### Case description

Our patient is the first child of non-consanguineous parents of Arab descent, born at term with normal weight and length. At 2 weeks of age, he developed an intertriginous seborrhoeic eczema-like dermatitis (Fig. 1A). A pustular eruption emerged at age 1.5 months and rapidly evolved into a severely pruritic and seemingly painful ichthyosiform erythroderma (Fig. 1B). His hair was normal at birth, but total alopecia developed at 3 months. His nails were abnormally thin and soft.

He had had relapsing *Staphylococcus aureus* skin infections, *Candida albicans* thrush, recurrent enterococcal

and staphylococcal sepsis since the age of 4 months. At 5 months, he developed severe and relapsing protracted HSV-1 stomatitis with extensive mucocutaneous involvement (Fig. 1C). Extensive infectious, immunological and metabolic evaluations were mostly normal and did not suggest any specific immunodeficiency syndrome.

From age 4 months onwards, he developed difficulties with swallowing and progressive FTT. These necessitated percutaneous gastrostomy and initiation of amino acid-based formula feeding. Cow milk protein intolerance was diagnosed at 7 months by an in-hospital oral provocation challenge and manifested as profuse vomiting, diarrhoea and inconsolable crying within hours of administration of standard formula. At 6 months, his serum IgE levels increased up to 958 kU/l (normal <70 kU/l), but then gradually returned to near normal value (102 kU/l). Eosinophil counts remained normal. In the ImmunoCAP specific IgE assay against 112 allergens, only a low-level reactivity (0.7 ISU, normal >0.3 ISU) to prohevein rHev b 6.01 was detected at 9 months, but at 11 months positivity to peanut (0.37 kU/l) and egg-white (1.03 kU/l) appeared. Profound fluid balance disturbances with hypo- and hypernatremia and rapid dehydration or generalized oedema occurred during erythrodermic flares. Arrhythmia or cardiac abnormalities have, so far, not been detected.

Upper gastrointestinal tract endoscopy was normal at 4 months, but revealed lymphocyte and plasmablast mucosal infiltrates in the stomach at 7 months. After several courses of proton pump inhibitors, his gastric histology normalized at 2 years of age. However, he then exhibited mild oesophagitis with some intraepithelial eosinophils, not numerous enough to fulfil the criteria for eosinophilic oesophagitis.

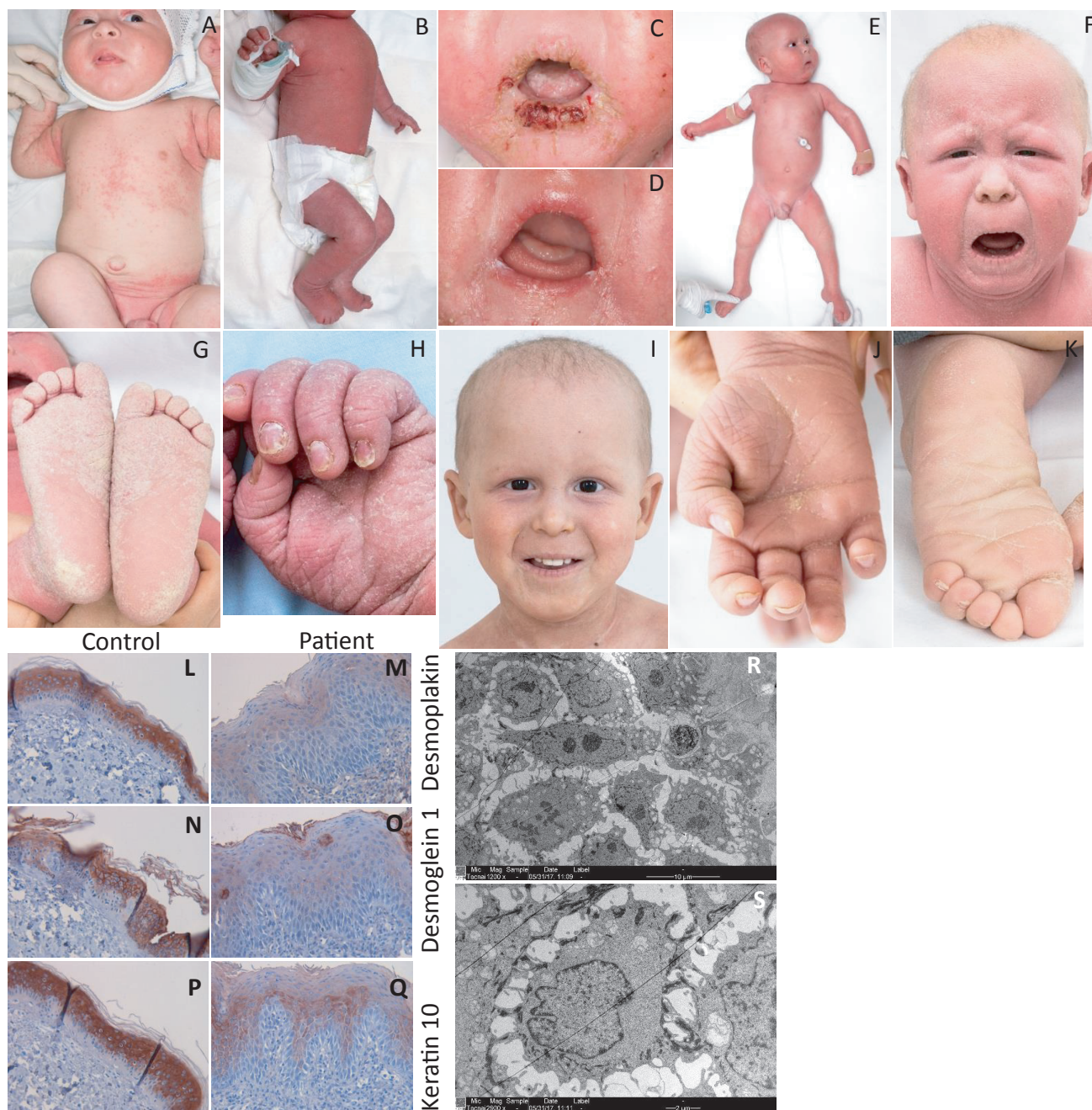Motor development was delayed from the age of 4 months. Brain magnetic resonance imaging (MRI) at 4 months showed symmetrical diffusion restriction in the superior cerebellar peduncles and decussation. Also, red nuclei in mesencephalon, subthalamic region, globi pallidi and optic radiation were involved (Fig. S1<sup>1</sup>). Repeated MRI a month later showed no progression of these changes. His motor development progresses, but remains delayed, with no independent walking at 2 years of age.

At 6 months he developed a firm papular lesion 2.0 cm in diameter on his tongue (Fig. 1D), which resolved spontaneously over months. Biopsy of the lesion revealed a pyogenic granuloma. HSV-1, cytomegalovirus and human papillomavirus (HPV) 11 were found in the lesion by nucleic acid assay, while other viral, bacterial, mycobacterial and fungal investigations were negative.

The patient's skin was treated with basic emollients and courses of topical mild potency corticosteroids. McAleer et al. (8) reported topical tacrolimus, systemic antibiotics, intravenous immunoglobulin (IVIg) therapy and systemic acitretin to be effective in their patient with a *DSP* variant. At 5 months, IVIg therapy for recurrent sepsis was commenced. He has had no bacterial infec-

<sup>1</sup><https://www.medicaljournals.se/acta/content/abstract/10.2340/00015555-3203>





**Fig. 1. Clinical features of the reported patient.** (A) An intertriginous seborrheic like eczema at 2 weeks of age (B) evolved into a ichthyosiform erythroderma at 1.5 months. (C) Severe and relapsing HSV-1 stomatitis at 5 months and (D) a pyogenic granuloma on the tongue at 6 months. (E) Slight alleviation of scaling and erythema and hair regrowth after initiation of acitretin therapy at 7 months. (F) Ichthyotic erythroderma at 18 months with the development of (G) slight palmoplantar keratoderma (PPK) and (H) onychodystrophy. (I–K) Response to ustekinumab treatment at 25 months included hair regrowth and alleviation of skin scaling and PPK. DSP mutation leads to decreased levels of DSP, DSG1 and KRT10. (L) Skin tissue of a normal control shows prominent DSP antibody staining throughout the epidermis in suprabasal cells, while in the patient (M) only a weak staining is seen in the upper epidermis. DSG1 is distinct intercellularly in (N) healthy skin, but almost totally lost (O) in the patient. KRT10 stains intensely in (P) the suprabasal healthy skin, but is weak in the patient's upper epidermis and (Q) diminished in the suprabasal layers. Electron microscopy of the patient's skin biopsy samples shows the loss of intercellular cohesiveness, especially (R) suprabasally and decreased numbers of desmosomes and tonofilaments, as well as (S) the absence of perinuclear tonofilaments. Written permission from the parent.

tions since, while recurrent mucocutaneous HSV-1 flares have necessitated continuous acyclovir prophylaxis. IVIG substitution was stopped at 20 months. Acitretin was started at a low dose of 0.25 mg/kg every other day at 7.5 months (8). Acitretin slightly alleviated scaling, erythema and itch and induced hair regrowth (Fig. 1E).

Due to constant vomiting, acitretin was stopped at 14 months, followed by no significant change in his skin condition nor vomiting. His first tooth erupted at 10 months and his teeth have been normal. At 18 months, he developed ichthyotic erythroderma (Fig. 1F–H), and, additionally, he has developed mild PPK and onycho-

dystrophy. His growth has improved substantially due to optimized enteral nutrition.

Since 2 patients with DSP variants were reported to benefit from ustekinumab therapy, with reduction in itching and in dermatitis severity and improvement in hair thickness (9), we initiated ustekinumab treatment at 22 months in our patient. Ustekinumab (0.75 mg/kg) was given initially at 4 weeks and from then on every 12 weeks, leading to alleviation of pruritus, skin scaling and PPK, as well as better hair growth after the first 2 injections (Fig. 1I–K). Oral intake also improved significantly, and gastrostomy use could be discontinued. Along with clinical improvement, serum levels of IL-17A, IL-17F and IL-23 decreased strikingly, whereas concentrations of IL-12p70 somewhat increased, albeit at very low levels (< 1 pg/ml) (Fig. S2<sup>1</sup>).

**Skin biopsy findings.** Skin biopsy from the pustular eruption at 1.5 months showed eczema with a neutrophilic infiltrate and microabscesses. Biopsy at 3 months from the erythrodermic skin revealed a psoriasiform reaction pattern with a dense ichthyosiform stratum corneum and neutrophilic infiltrates in the epidermis and upper dermis. Filaggrin immunostaining was reduced in the first and absent in the second biopsy, suggesting ichthyosis, while LEKTI immunostaining was normal in both biopsies (data not shown). Hair morphology was normal. Immunohistochemistry demonstrated significant decrease in desmoplakin, desmoglein 1 and keratin 10 (Fig. 1L–Q). Skin electron microscopy revealed decreased numbers of desmosomes and tonofilaments, and perinuclear tonofilaments were absent. The loss of intercellular cohesiveness was especially prominent suprabasally (Fig. 1R–S).

**Genetic work-up.** Ichthyosis and primary immunodeficiency gene panels (Blueprint Genetics, helsinki, Finland) detected no pathogenic variants. Clinical whole-exome sequencing was performed with median sequencing coverage of 132× and 99.1% of target regions were covered with at least 20 reads. Analysis of whole-exome sequence variants revealed a novel heterozygous missense variant in the *DSP* gene: c.1756C>T, p.(His586Tyr) (NM\_004415.2), confirmed with bidirectional Sanger sequencing. Based on Sanger sequencing analysis, the parents were not carriers, thus the variant was *de novo* in the patient. This variant has not been reported in the Exome Aggregation Consortium (ExAC) database or Genome Aggregation Database (gnomAD). The variant is predicted deleterious by in silico tools SIFT and MutationTaster and benign by PolyPhen, the CADD score (PHRED-like scaled C-score) is 24.3, suggesting that the amino acid change is deleterious. The His586 residue is located within one of the spectrin repeat domains, SR6, which is a hotspot for dominant missense variants causing cutaneous disease (10). Historical patient with a similar phenotype carried a *de novo* missense variant in the same amino acid residue p.(His586Pro) (8). Protein modelling with the template-based protein structure

tools RaptorX (17) and Swiss-model (18) did not predict alterations in the protein structure. However, histidine is an amino acid with unique chemical properties not particularly well substituted with any other amino acid.

Clinical whole-exome sequencing also identified a variant of uncertain significance, a novel heterozygous in-frame deletion c.11361\_11387del, p.(Asp3788\_Thr3796del) (NM\_001376.4) in *DYNC1H1*, which encodes the heavy chain of cytoplasmic dynein 1 that acts a motor involved in trafficking of vesicles and organelles along microtubule. The variant deletes 9 highly conserved amino acid residues in the motor domain of DYNC1H1 (19). Sanger sequencing of both parents revealed that the variant has occurred *de novo* in the patient.

#### Literature review on DSP and DSG1 variants and phenotype

The clinical and laboratory characteristics of the patients were compared with heterozygous variants in *DSP* SR6 and with homozygous or compound heterozygous variants in *DSG1* and SAM-like phenotype (**Table I** and **Fig. 2**). SR6 region dominant *DSP* variants have been reported in 15 patients, with clinical features ranging from a constellation of PPK, woolly hair and arrhythmogenic cardiomyopathy at one end of the spectrum (patients 7–13) to a SAM-like disease with erythroderma, ichthyosis, hypotrichosis, recurrent infections, FTT and gastrointestinal manifestations (patients 1–3, 14) at the other end of the spectrum (Table I). Overlapping features of cardiomyopathy, erythroderma, ichthyosis, hypotrichosis, PPK and woolly hair have been reported in another 4 patients with *DSP* variants (patients 4–6, 15, Table I).

Overall, the shared clinical manifestations (*DSP/DSG1*) are as follows: PPK (100%/92%), erythroderma (53%/67%), ichthyosis (53%/50%), FTT (40%/33%), recurrent infections (20%/33%), gastrointestinal problems (27%/17%) and developmental delay (20%/25%) (Fig. 2). Otherwise, clinical features varied considerably. Subjects with *DSG1* variants do not manifest eosinophilia, pustulosis, dental and ophthalmic abnormalities, hoarse voice, cardiomyopathy or arrhythmias. Woolly hair and nail abnormalities were more common in patients with *DSP* variants (14/15 vs. 4/12,  $p=0.003$  and 11/15 vs. 1/12,  $p=0.001$ , respectively), while elevated IgE and food allergies were observed more frequently in patients with *DSG1* variants (10/12 vs. 3/15,  $p=0.002$  and 8/12 vs. 3/15,  $p=0.022$ , respectively).

## DISCUSSION

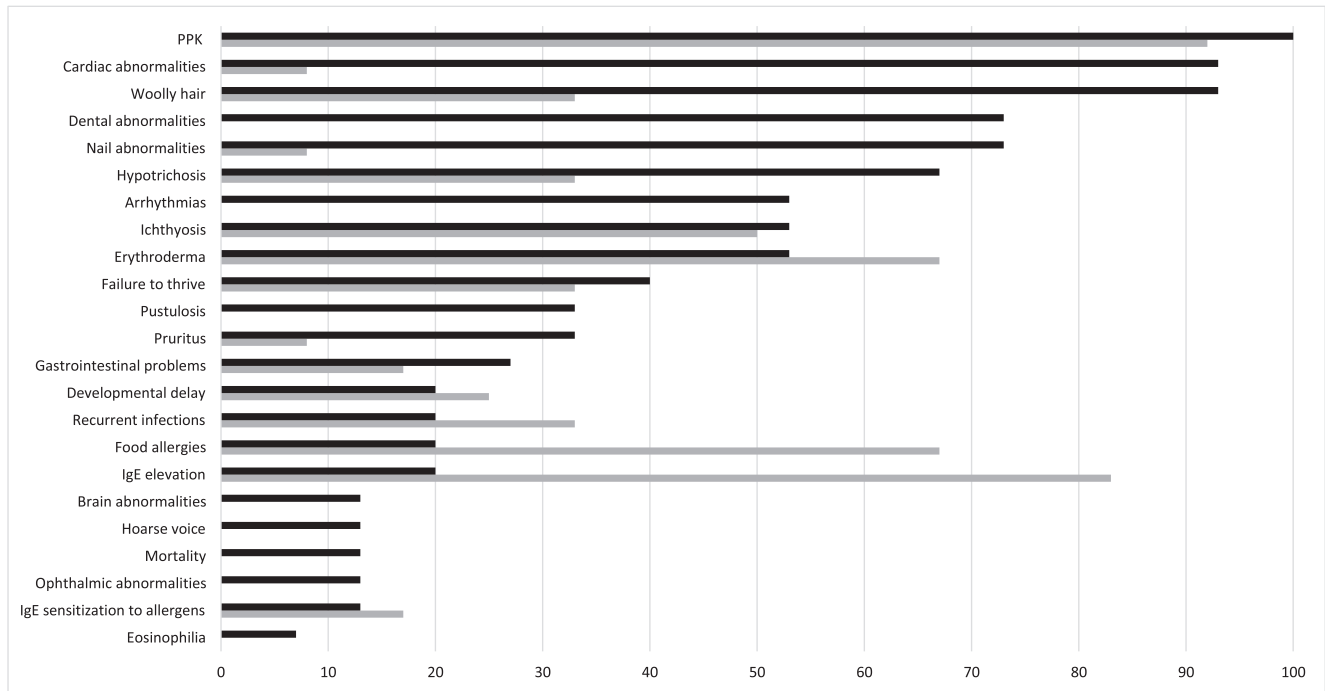
We report here a patient with a novel *DSP* variant c.1756C>T, p.His586Tyr and severe erythrodermic ichthyosis, resembling, but distinct from, SAM, with previously undescribed features of severe recurrent

**Table I. Clinical and laboratory characteristics of patients with heterozygous variants in DSP SR6**

Pat. No./Ref.	I/ Present	2/8	3/9	4/10	5/10	6/10	7/11	8/11	9/20	10/20	11/21	12/21	13/22	14/12	15/12
Variant	c.1756 C>T A>C p.H586Y	c.1757 A>C p.H586P	c.1748 T>C p.L583P	c.1846 A>C p.Q616P	c.1852 A>C p.H618P	c.1864 T>C p.L622P	c.1748 T>C p.L583P	c.1691 C>T p.T564I	c.1691 C>T p.Thr564Ile	c.1691 C>T p.Thr564Ile	c.1790 C>T p.Ser597L	c.1790 C>T p.Ser597L	30 bp insertion in codon 608	c.A1757C p.H586P	c.T1828C p.S610P
Exon number	14	14	14	14	14	14	14	13	13	13	14	14	14	14	14
Age (years)	2	9	10	3	8	10	14.5	22	29	10	21	14	18	13	9
Sex	M	M	F	M	M	F	N/A	F	M	M	M	M	F	M	M
Ichthyosis	+	+	+	+	+	+	-	-	-	-	-	-	-	+	+
Erythroderma	+	+	+	+	+	+	-	-	-	-	-	-	-	+	+
PPK	+	+	+	+	+	+	+	+	+	+	+	+	+	+	+
Pruritus	+	+	-	+	+	+	-	-	-	-	-	-	-	-	-
Pustulosis	+	+	+	-	-	-	+	-	-	-	-	-	+	+	+
Hypotrichosis	+	+	+	+	+	+	+	-	-	-	-	-	+	+	+
Woolly hair	-	+	+	+	+	+	+	+	+	+	+	+	+	+	+
Nail abnormalities	+	+	+	+	+	+	-	-	+	+	+	+	-	+	+
Dental abnormalities	-	+	+	-	-	-	+	+	+	+	+	+	+	+	+
Cardiac abnormalities	-	Aortic stenosis	CMP	LV and RV dilation	LV and right atrial dilatation	LV dilation	Aortic stenosis, ventricular CMP	LV and RV dilation	Dilated CMP	Right ventricle infundibulum dilatation	LV dilatation, heart transplant	Dilated CMP	Biventricular CMP	Biventricular dilated CMP	Left-dominant CMP, heart transplant
Arrhythmias	-	-	-	-	-	-	+	+	+	+	+	+	+	-	+
Recurrent infections	+	+	+	-	-	-	-	-	-	-	-	-	-	-	-
Failure to thrive	+	+	+	+	+	-	-	-	-	-	-	-	-	+	-
Gastrointestinal problems	+	+	+	+	-	-	-	-	-	-	-	-	-	+	-
Developmental delay	+	+	-	-	+	-	-	-	-	-	-	-	-	-	-
Brain abnormalities	+	+	-	-	-	-	-	-	-	-	-	-	-	-	-
IgE elevation	+	+	-	-	-	-	-	-	-	-	-	-	-	+	-
Eosinophilia	+	+	-	-	-	-	-	-	-	-	-	-	-	-	-
IgE sensitization to allergens	-	+	-	-	-	+	-	-	-	-	-	-	-	-	-
Food allergies	-	+	-	-	-	-	-	-	-	-	-	-	-	+	-
Ophthalmic abnormalities	-	-	-	-	large corneal opacities	-	-	-	-	-	-	-	-	-	-
Hoarse voice	+	-	-	-	+	-	-	-	-	-	-	-	-	-	-
Outcome	Alive	Alive	Alive	Died from heart failure	Alive	Alive	Alive	Alive	Alive	Alive	Alive	Alive	Died from heart arrhythmia	Alive	Alive

<sup>a</sup>Symmetrical bilateral diffusion modality changes on magnetic resonance imaging, <sup>b</sup> Mild dilatation of the lateral and third ventricle, with diffuse prominence of the sulci over both cerebral hemispheres on computed tomography, macrocephaly. CMP: cardiomyopathy; Ig: immunoglobulin; LV: left ventricle; RV: right ventricle; VSD: ventricular septal defect.





**Fig. 2.** The prevalence of clinical features in 15 patients with *DSP* (black bars, Table I) and 12 patients with *DSG1* (grey bars, references 2–7) variants.

mucocutaneous HSV-1 infection, oral pyogenic granuloma, gastritis and brain lesions. The patient was treated successfully with ustekinumab, targeting the IL-12 and IL-23 as well as downstream IL-17 pathways and adding to the previously reported favourable experience with this medication in another 2 patients with *DSP* SR6 variants (9). The current patient is thus the third case reported to benefit from ustekinumab therapy.

Patients with SAM present with chronic inflammation of the skin and gastrointestinal epithelium, leading to a dysregulated immune response (9, 12). Our patient showed lymphocytic and plasmablast infiltrates in the gastric mucosa. Coupled with swallowing difficulties and gradually progressing vomiting, as well as further development of mild oesophagitis, these may reflect desmoplakin-related disruption of gastrointestinal mucosa or food intolerance. The severe reaction to cow's milk was out of proportion to his serum IgE levels and resembled food protein-induced enterocolitis syndrome (23).

The aetiology of brain abnormalities in our patient remains unexplained, since *DSP* is not expressed in the central nervous system (The Human Protein Atlas; GTEx Portal) and since *DSP* variants have not been associated with brain tissue pathology. Therefore, factors such as undiagnosed perinatal hypoxia, severe FTT and drastic dysnatraemia may contribute. However, developmental delay has been reported in association with some *DSP* variants (Table I) and its link to desmosomal protein dysfunction warrants further study. Interestingly, our patient had a novel heterozygous *de novo* inframale deletion p.(Asp3788\_Thr3796del) in *DYNClH1*, of which *de novo* variants have been reported in patients with

malformations of cortical development and various other neurological disorders (24, 25). However, the contribution of the *DYNClH1* variant to aetiology of the observed symmetrical bilateral diffusion modality changes in our patient remains unknown.

The self-resolving tongue pyogenic granuloma in our patient was positive for multiple viral nucleic acids. Although HPV is a well-known cause of mouth papillomatous lesions, both HPV and CMV nucleic acids are frequently detected in oral cavities of healthy infants (26, 27). Instead, HSV-2 and HSV-1 have been reported to cause self-resolving pseudotumour on the tongue (28) and pyogenic granuloma (29), consistent with the preceding HSV-1 mucocutaneous infection in our patient. Also, mechanical stress from a recently introduced pacifier may have contributed to lesion formation (30).

IVIg therapy may have reduced the number of bacterial infections in our patient, as well as in the first described individual with SAM due to *DSP* variant, despite the normal pretreatment IgG levels in both. Also, IVIg has demonstrated efficacy in patients with Netherton syndrome (31). This may reflect the need for higher IgG levels in patients with epidermal barrier defects who lose protein continuously via inflamed skin. In addition, specific antibody deficiency has been described in some subjects with Netherton syndrome (32). In our patient, IgG levels decreased despite initiation of IVIg, but stabilized after higher and more frequent IVIg dosing. The beneficial effects of IVIg therapy in our case may thus be explained by age-specific immature antibody production exacerbated by chronic protein loss via skin. Acitretin is

successfully used in the management of ichthyoses (33, 34) and was also partially effective in our patient.

Ustekinumab targets the disrupted balance of IL-23 / Th17 pathway and has been efficient in controlling skin inflammation in 2 patients with *DSP* SR6 variants (9), as well as in our case. We provide novel data on the decrease in serum IL-17A and IL-17F levels after initiation of ustekinumab therapy, adding evidence of its biologic efficacy in patients with *DSP* mutations. The increase in IL-12p70 levels, although in levels below 1 pg/ml, during ustekinumab therapy may reflect a compensatory protective effect of IL-12 in skin inflammation (35). Follow-up studies are needed to test the efficacy, if any, of ustekinumab in preventing the development of cardiomyopathy, a fatal complication seen in the majority of *DSP* SR6 variant patients (Table I).

Patients with SR6 *DSP* variants manifest a spectrum of clinical features, ranging from PPK and cardiomyopathy to SAM-like disease. We add severe HSV-1 infection, brain abnormalities and persistent gastrointestinal problems to the diversity of their phenotype. *DSP* variants should be included in the differential diagnosis of infants with ichthyosiform erythroderma, FTT, recurrent infections and these novel features, to allow rapid diagnosis and early therapy. Based on current literature, the clinical features in SAM, SAMEC and SAM-like phenotypes are highly variable. Clinicians caring for these patients should be familiar with the diverse manifestations of desmosomopathies, as well as the importance of early genetic diagnosis, given that only patients with *DSP* SR6, not *DSG1* variants, are at inevitable risk of developing cardiomyopathy. Further studies on the mechanisms of immune dysregulation in patients with *DSG1* and *DSP* variants would provide background for novel targeted therapies, such as immunosuppressants or immunomodulators.

## ACKNOWLEDGEMENTS

The authors thank Dr Isabelle Meyts for her critical comments concerning this case. DD acknowledges ImmunoQure for provision of L17F monoclonal antibodies.

The study was funded by the Doctoral School in Health Sciences at the University of Helsinki (SV), and Helsinki and Uusimaa joint authority research grant (TYH 2015210, AR, KHJ).

*Conflicts of interest:* MM is employed by Blueprint Genetics.

## REFERENCES

- McGrath JA. Inherited disorders of desmosomes. *Australas J Dermatol* 2005; 46: 221–229.
- Samuelov L, Sarig O, Harmon RM, Rapaport D, Ishida-Yamamoto A, Isakov O, et al. Desmoglein 1 deficiency results in severe dermatitis, multiple allergies and metabolic wasting. *Nat Genet* 2013; 45: 1244–1248.
- Has C, Jakob T, He Y, Kiritsi D, Hausser I, Bruckner-Tuderman L. Loss of desmoglein 1 associated with palmoplantar keratoderma, dermatitis and multiple allergies. *Br J Dermatol* 2015; 172: 257–261.
- Schlipf NA, Vahlquist A, Teigen N, Virtanen M, Dragomir A, Fismen S, et al. Whole-exome sequencing identifies novel autosomal recessive *DSG1* mutations associated with mild SAM syndrome. *Br J Dermatol* 2016; 174: 444–448.
- Cheng R, Yan M, Ni C, Zhang J, Li M, Yao Z. Report of Chinese family with severe dermatitis, multiple allergies and metabolic wasting syndrome caused by novel homozygous desmoglein-1 gene mutation. *J Dermatol* 2016; 43: 1201–1204.
- Dănescu S, Leppert J, Cosgarea R, Zurac S, Pop S, Baican A, et al. Compound heterozygosity for dominant and recessive *DSG1* mutations in a patient with atypical SAM syndrome (severe dermatitis, multiple allergies, metabolic wasting). *J Eur Acad Dermatol Venereol* 2017; 31: e144–e146.
- Taiber S, Samuelov L, Mohamad J, Cohen Barak E, Sarig O, Shalev SA, et al. SAM syndrome is characterized by extensive phenotypic heterogeneity. *Exp Dermatol* 2018; 27: 787–790.
- McAleer MA, Pohler E, Smith FJ, Wilson NJ, Cole C, MacGowan S, et al. Severe dermatitis, multiple allergies, and metabolic wasting syndrome caused by a novel mutation in the N-terminal plakoin domain of desmoplakin. *J Allergy Clin Immunol* 2015; 136: 1268–1276.
- Paller AS, Czarnowicki T, Renert-Yuval Y, Holland K, Huynh T, Sadlier M, et al. The spectrum of manifestations in desmoplakin gene (*DSP*) spectrin repeat 6 domain mutations: Immunophenotyping and response to ustekinumab. *J Am Acad Dermatol* 2018; 78: 498–505.e2.
- Boyden LM, Kam CY, Hernández-Martín A, Zhou J, Craiglow BG, Sidbury R, et al. Dominant de novo *DSP* mutations cause erythrokeratoderma-cardiomyopathy syndrome. *Hum Mol Genet* 2016; 25: 348–357.
- Keller DI, Stepowski D, Balmer C, Simon F, Guenthard J, Bauer F, et al. De novo heterozygous desmoplakin mutations leading to Naxos-Carvajal disease. *Swiss Med Wkly* 2012; 142: w13670.
- Polivka L, Hadj-Rabia S, Bal E, Leclerc-Mercier S, Madrange M, Hamel Y, et al. Epithelial barrier dysfunction in desmoglein-1 deficiency. *J Allergy Clin Immunol* 2018; 142: 702–706.e7.
- Czarnowicki T, Krueger JG, Guttman-Yassky E. Novel concepts of prevention and treatment of atopic dermatitis through barrier and immune manipulations with implications for the atopic march. *J Allergy Clin Immunol* 2017; 139: 1723–1734.
- Paluel-Marmont C, Bellon N, Barbet P, Leclerc-Mercier S, Hadj-Rabia S, Dupont C, et al. Eosinophilic esophagitis and colonic mucosal eosinophilia in Netherton syndrome. *J Allergy Clin Immunol* 2017; 139: 2003–2005.e1.
- Uhlén M, Fagerberg L, Hallström BM, Lindskog C, Oksvold P, Mardinoglu A, et al. Proteomics. Tissue-based map of the human proteome. *Science* 2015; 347: 1260419. Human Protein Atlas. Available from: [www.proteinatlas.org](http://www.proteinatlas.org); <http://www.proteinatlas.org/ENSG00000096696-DSP/tissue>.
- Polivka L, Bodemer C, Hadj-Rabia S. Combination of palmoplantar keratoderma and hair shaft anomalies, the warning signal of severe arrhythmic cardiomyopathy: a systematic review on genetic desmosomal diseases. *J Med Genet* 2016; 53: 289–295.
- Källberg M, Wang H, Wang S, Peng J, Wang Z, Lu H, et al. Template-based protein structure modeling using the RaptorX web server. *Nature Protocols* 2012; 7: 1511–1522.
- Biasini M, Bienert S, Waterhouse A, Arnold K, Studer G, Schmidt T, et al. SWISS-MODEL: modelling protein tertiary and quaternary structure using evolutionary information. *Nucleic Acids Res* 2014; 42(Web Server issue): W252–258.
- Hoang HT, Schlager MA, Carter AP, Bullock SL. *DYNC1H1* mutations associated with neurological diseases compromise processivity of dynein-dynactin-cargo adaptor complexes. *Proc Natl Acad Sci U S A* 2017; 114: E1597–E1606.
- Boulé S, Fressart V, Laux D, Mallet A, Simon F, de Groote P, et al. Expanding the phenotype associated with a desmoplakin dominant mutation: Carvajal/Naxos syndrome associated with leukonychia and oligodontia. *Int J Cardiol* 2012; 161: 50–52.
- Chalabreysse L, Senni F, Bruyère P, Aime B, Ollagnier C, Bozio A, et al. A new hypo/oligodontia syndrome: Carvajal/Naxos



- syndrome secondary to desmoplakin-dominant mutations. *J Dent Res* 2011; 90: 58–64.
22. Norgett EE, Lucke TW, Bowers B, Munro CS, Leigh IM, Kellsell DP. Early death from cardiomyopathy in a family with autosomal dominant striate palmoplantar keratoderma and woolly hair associated with a novel insertion mutation in desmoplakin. *J Invest Dermatol* 2006; 126: 1651–1654.
  23. Nowak-Węgrzyn A, Chehade M, Groetch ME, Spergel JM, Wood RA, Allen K, et al. International consensus guidelines for the diagnosis and management of food protein-induced enterocolitis syndrome: executive summary-Workgroup Report of the Adverse Reactions to Foods Committee, American Academy of Allergy, Asthma & Immunology. *J Allergy Clin Immunol* 2017; 139: 1111–1126.e4.
  24. Poirier K, Lebrun N, Broix L, Tian G, Saillour Y, Boscheron C, et al. Mutations in TUBG1, DYNC1H1, KIF5C and KIF2A cause malformations of cortical development and microcephaly. *Nat Genet* 2013; 45: 639–647.
  25. Laquerriere A, Maillard C, Cavallin M, Chapon F, Marguet F, Molin A, et al. Neuropathological hallmarks of brain malformations in extreme phenotypes related to DYNC1H1 mutations. *J Neuropathol Exp Neurol* 2017; 76: 195–205.
  26. Martinelli M, Zappa A, Bianchi S, Frati E, Colzani D, Amendola A, et al. Human papillomavirus (HPV) infection and genotype frequency in the oral mucosa of newborns in Milan, Italy. *Clin Microbiol Infect* 2012; 18: E197–199.
  27. Stowell JD, Mask K, Amin M, Clark R, Levis D, Hendley W, et al. Cross-sectional study of cytomegalovirus shedding and immunological markers among seropositive children and their mothers. *BMC Infect Dis* 2014; 14: 568.
  28. Husak R, Tebbe B, Goerdts S, Wölfer LU, Zeichardt H, Stöffler-Meilicke M, et al. Pseudotumour of the tongue caused by herpes simplex virus type 2 in an HIV-1 infected immunosuppressed patient. *Br J Dermatol* 1998; 139: 118–121.
  29. El Hayderi L, Paurbally D, Fassotte MF, André J, Arrese JE, Sadzot-Delvaux C, et al. Herpes simplex virus type-I and pyogenic granuloma: a vascular endothelial growth factor-mediated association? *Case Rep Dermatol* 2013; 5: 236–243.
  30. Patil K, Mahima VG, Lahari K. Extralingival pyogenic granuloma. *Indian J Dent Res* 2006; 17: 199–202.
  31. Renner ED, Hartl D, Rylaarsdam S, Young ML, Monaco-Shawver L, Kleiner G, et al. Comèl-Netherton syndrome defined as primary immunodeficiency. *J Allergy Clin Immunol* 2009; 124: 536–543.
  32. Stryk S, Siegfried EC, Knutsen AP. Selective antibody deficiency to bacterial polysaccharide antigens in patients with Netherton syndrome. *Pediatr Dermatol* 1999; 16: 19–22.
  33. Fritsch PO. Retinoids in psoriasis and disorders of keratinization. *J Am Acad Dermatol* 1992; 27: S8–14.
  34. Rajpopat S, Moss C, Mellerio J, Vahlquist A, Ganemo A, Hellstrom-Pigg M, et al. Harlequin ichthyosis: a review of clinical and molecular findings in 45 cases. *Arch Dermatol* 2011; 147: 681–686.
  35. Kulig P, Musiol S, Freiburger SN, Schreiner B, Gyülveszi G, Russo G, et al. IL-12 protects from psoriasiform skin inflammation. *Nat Commun* 2016; 7: 13466.