



HAL
open science

Theiler's virus infection of 129Sv mice that lack the interferon alpha/beta or interferon gamma receptors

Laurence Fiette, Christine Aubert, Ulrike Mfiller, Sui Huang, Michel Aguet,
Michel Brahic, Jean-François Bureau

► To cite this version:

Laurence Fiette, Christine Aubert, Ulrike Mfiller, Sui Huang, Michel Aguet, et al.. Theiler's virus infection of 129Sv mice that lack the interferon alpha/beta or interferon gamma receptors. *Journal of Experimental Medicine*, 1995, 181 (6), pp.2069-2076. 10.1084/jem.181.6.2069 . pasteur-02090452

HAL Id: pasteur-02090452

<https://pasteur.hal.science/pasteur-02090452>

Submitted on 4 Apr 2019

HAL is a multi-disciplinary open access archive for the deposit and dissemination of scientific research documents, whether they are published or not. The documents may come from teaching and research institutions in France or abroad, or from public or private research centers.

L'archive ouverte pluridisciplinaire **HAL**, est destinée au dépôt et à la diffusion de documents scientifiques de niveau recherche, publiés ou non, émanant des établissements d'enseignement et de recherche français ou étrangers, des laboratoires publics ou privés.



Distributed under a Creative Commons Attribution - NonCommercial - ShareAlike 4.0 International License

Theiler's Virus Infection of 129Sv Mice That Lack the Interferon α/β or Interferon γ Receptors

By Laurence Fiette,* Christine Aubert,* Ulrike Müller,‡
Sui Huang,‡ Michel Aguet,‡ Michel Brahic,* and
Jean-Francois Bureau*

From the *Unité des Virus Lents, UA 1157 Centre National de la Recherche Scientifique, Institut Pasteur, 75724 Paris Cedex 15, France; and the ‡Institut für Molekularbiologie I, Höggerberg, Universität Zürich, 8057 Zürich, Switzerland

Summary

The Daniels strain of Theiler's virus causes a persistent infection of the white matter of spinal cord of susceptible mice, with chronic inflammation and primary demyelination. Inbred 129Sv mice are resistant to this infection; they present with mild encephalomyelitis and clear the infection within a matter of days. A very different outcome was observed with inbred 129Sv mice whose receptors for interferon α/β or interferon γ had been inactivated by homologous recombination. The former presented severe encephalomyelitis with acute infection of neurons, particularly in brain and hippocampus, and extensive infection with necrosis of the choroid plexus. Most animals died of this acute disease. The latter, presented the same early encephalomyelitis as the control 129Sv mice. However, they remained persistently infected and developed a very severe late infection of the white matter with extensive primary demyelination. This late disease looked like an exacerbated form of the chronic demyelinating disease observed in susceptible inbred mice such as the SJL/J or FVB strains. Our results show that the two interferon systems play nonredundant roles in the resistance of the 129Sv mouse to the infection by Theiler's virus. They also lend support to the notion that the *Ifg* gene is involved in the resistance/susceptibility of inbred strains of mice to persistent infection by this picornavirus.

The Daniels (DA) strain of Theiler's virus, a murine picornavirus, is responsible for a biphasic neurological disease (1, 2). The first phase is an encephalomyelitis that takes place during the first 2 wk after intracerebral inoculation. At this stage, the virus replicates mostly in neurons and, to some extent, in glial cells of the cerebral cortex, hippocampus, thalamus, and anterior horns of the spinal cord (3). Depending on the inoculum size and the particular clone of DA virus used, this early disease is clinically silent or causes paralysis and death in some of the animals. The virus then disappears from the gray matter and finds its way to the white matter, where it persists in glial cells for the lifetime of the animal (4). The infected cells are macrophage/microglial cells and oligodendrocytes and to a smaller extent astrocytes (5, 6). This persistent infection is associated with chronic meningitis, mononuclear inflammation of the white matter parenchyma, and primary demyelination. Because of its chronicity and the histological appearance of the lesions, this late demyelinating disease is studied as a model for multiple sclerosis.

The mechanism of the demyelination caused by Theiler's virus is only partially understood. The persistent infection of oligodendrocytes may have a direct effect on myelin turnover (7–10). On the other hand, a host of experimental data is in favor of an immune-mediated mechanism. In particular,

a delayed-type hypersensitivity response mediated by CD4⁺ lymphocytes and directed at viral epitopes correlates closely with demyelination (11–13). Cytokines and free radicals secreted by activated macrophages that participate in this delayed-type hypersensitivity response could cause the destruction of the myelin sheaths through a "bystander effect" (14). It should be noted that, regardless of the exact mechanism involved, all available evidence indicates that demyelination requires the persistent infection of the white matter.

Inbred strains of mice differ greatly in their susceptibility to this disease. Two of them, the SJL/J and FVB strains, are extremely susceptible; others, such as the C57BL/6 strain, are totally resistant; the majority of them are of intermediate susceptibility (15). This complex phenotype is obviously under the control of several genes, and it has been known for some time that the H-2D region of the MHC plays an important role (16–19). During the past years, we have showed that a gene located in the H-2D region of the MHC controls the level of viral RNA that persists in the central nervous system (CNS).¹ The *q* haplotype of this region is associated with high levels of viral RNA, and the *d*, *k*, and *s* haplotypes are

¹ Abbreviations used in this paper: CNS, central nervous system; p.i., postinoculation.

associated with intermediate levels. The *b* haplotype confers resistance in a dominant fashion (20). Using FVB (*H-2^d*) mice transgenic for the *H-2D^b* gene, we demonstrated that this gene is responsible for the dominant resistance of the C57BL/6 strain of mouse (21). As mentioned above, non-*H-2* genes are also implicated in susceptibility/resistance to the persistent infection by Theiler's virus. In particular, the fact that the SJL/J mouse is more susceptible than the B10.S mouse, although they both bear the same *H-2^d* haplotype, indicates the existence of these non-*H-2* genes. By screening with polymorphic markers the entire genome of an F1(SJL/J × B10.S) × B10.S backcross, we mapped one of the genes responsible for the susceptibility of the SJL/L mouse close to the IFN- γ locus on the telomeric part of chromosome 10. The gene coding for IFN- γ is a good candidate gene in this region because of the antiviral and immuno modulatory roles of this cytokine. Another gene responsible for the susceptibility of the SJL/J mouse was tentatively mapped close to the *Mbp* locus on chromosome 18 (22).

This work was undertaken to test the role of IFN- γ in the pathogenesis of the disease caused by Theiler's virus, particularly in the persistence of the infection. We also tested the role of the type I interferons that are known to restrict the replication of picornaviruses in tissue cultures (23–25) and to affect the diseases caused by these agents (26, 27). These studies took advantage of recently described inbred 129Sv mice in which the receptors for either IFN- γ or IFN α/β have been inactivated by homologous recombination (28, 29). These strains are designated IFN- γ R^{o/o} and IFN- α/β R^{o/o}, respectively. Parental 129Sv mice are resistant to the chronic infection by Theiler's virus because of their *H-2^b* haplotype. In this article, we describe that IFN- α/β R^{o/o} mice became extremely susceptible to the early gray matter phase of the disease and died of overwhelming encephalitis. In contrast, early disease was not affected in IFN- γ R^{o/o} mice, but these mice were unable to clear the infection. Large amounts of viral antigens persisted in the white matter of brain and spinal cord and caused a very severe late inflammatory and demyelinating disease. A significant number of animals died between the 5th and 6th wk after inoculation. These results demonstrate the importance of both types of interferon in the resistance to Theiler's virus infection, and the remarkable specificity of each type for different phases of this complex disease.

Materials and Methods

Animals. The construction of the IFN- α/β R^{o/o} and IFN- γ R^{o/o} mice has been described in detail elsewhere (28, 29). These mice are inbred 129/Sv animals for which the respective receptors have been inactivated by homologous recombination. Inbred 129/Sv mice were used as controls. All mice used for histopathological studies had "spf" sanitary status. 3–4-wk-old mice were inoculated intracranially with 10⁴ PFU of the DA strain of Theiler's virus and observed at regular time intervals to record clinical signs and mortality.

Histology. The mice were anesthetized with ether, perfused through the left ventricle with PBS followed by 4% paraformaldehyde in PBS. The brain and spinal cord were dissected out, refixed

by immersion, and embedded in paraffin using routine procedures. Serial coronal sections of the brain and longitudinal sections of the spinal cord were prepared and stained with hematoxylin eosin or the Cleveland stain for connective tissue.

Immunohistochemistry. The detection of viral antigens in paraffin sections was performed as described previously (5). Briefly, the sections were reacted with a rabbit hyper immune serum against Theiler's virus capsid proteins, followed by a biotinylated anti-rabbit secondary antibody and an avidin-biotin-horseradish peroxidase complex (Vectastain; Vector Laboratories, Burlingame, CA). The slides were counterstained with Harris hematoxylin or Luxol fast blue.

Semi- and Ultra-thin Sections. Mice were perfused with PBS followed by a mixture of 4% buffered paraformaldehyde and 1% glutaraldehyde. CNS tissues were postfixed in osmium tetroxide and then embedded in Epon. 1- μ m-thick sections were cut and stained with toluidine blue to study demyelination. Ultra-thin sections were cut from demyelinated areas and stained with uranyl acetate and lead citrate.

Quantification of Viral RNA in CNS. The assay has been described in detail elsewhere (20). Briefly, total RNA was extracted from brain or spinal cord. Fivefold dilutions of the RNA solutions were dotted on Hybond C-extra filters (Amersham Corp., Arlington Heights, IL). The filters were hybridized with either a β -actin-specific ³²P-labeled cDNA probe (to control for the integrity of the RNA) or a virus-specific ³²P-labeled cDNA probe, and they were washed and exposed overnight against x-ray-sensitive films.

Results

IFN- α/β R^{o/o} Mice. In a first experiment, eight IFN- α/β R^{o/o} and seven control 129Sv mice were inoculated intracranially with 10⁴ PFU of the DA strain of Theiler's virus. The mice were observed daily for clinical symptoms and mortality. All the mice presented signs of encephalitis, including photophobia, as early as 2–3 d postinoculation (p.i.) (Fig. 1). Six out of eight mice died of this disease by day 10 p.i. (Fig. 2). The two survivors did not show sequelae. In a second experiment, the animals (four IFN- α/β R^{o/o} and four 129Sv mice) were killed 3 d p.i. for histological studies. The brain of the IFN- α/β R^{o/o} mice showed neuronal necrosis and inflammation, mostly in the cortex and the hippocampus. Neutrophilic granulocytes were conspicuous in these lesions (Fig. 3 A). Mild meningitis was also present. However, the most striking observation was inflammation with necrosis of the choroid plexus in the lateral, third, and fourth ventricles (Fig. 3 D). Discrete meningitis and rare inflammatory foci were observed in the spinal cord. In control 129Sv mice, the pathology was limited to some focal neuronal necrosis in the hippocampus and to mild meningitis and rare foci of inflammation in brain and spinal cord. In this case, inflammation was mostly caused by mononuclear cells. The choroid plexuses were normal (Fig. 3 B).

Viral antigens were detected in adjacent sections using immunohistochemistry. The infection was extensive in the cortex, hippocampus, and corpus callosum, as well as in the choroid plexuses (Fig. 3 D) and meninges of IFN- α/β R^{o/o} mice. Viral antigens were also observed in the spinal cord of these mice: in the ependymal cells, the meninges, and in some areas

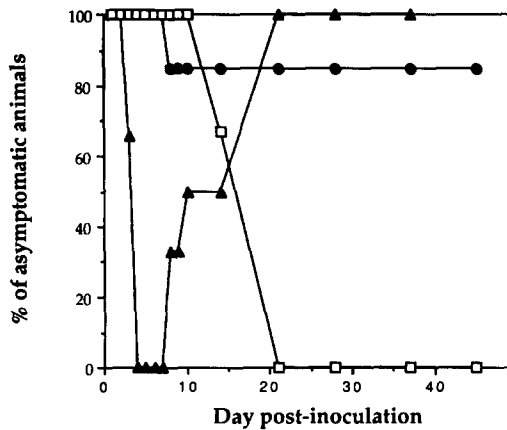


Figure 1. Clinical symptoms as a function of time p.i. Mice were inoculated intracerebrally with 10^4 PFU of the DA strain of Theiler's virus and observed daily for signs of encephalitis. (●): Control mice, (▲): IFN- $\alpha/\beta R^{o/o}$, (□): IFN- $\gamma R^{o/o}$. The number of mice in each group was control = 13, IFN- $\alpha/\beta R^{o/o}$ = 8, and IFN- $\gamma R^{o/o}$ = 6.

of the white matter. Only a small number of antigen-containing cells were found in the gray matter of the brain of control-infected 129Sv mice.

Viral replication was studied 3 d p.i. in the brain of eight IFN- $\alpha/\beta R^{o/o}$ mice by measuring the amount of viral RNA with a dot-blot assay. Five wild-type 129Sv mice were infected and processed in parallel as controls. As shown in Fig. 4, the amount of viral RNA was ~ 625 -fold higher in the brains of the IFN- $\alpha/\beta R^{o/o}$ mice than in those of control mice.

IFN- $\gamma R^{o/o}$ Mice. In a first experiment, six IFN- $\gamma R^{o/o}$ mice were inoculated intracerebrally with 10^4 PFU of the DA strain of Theiler's virus. In contrast to the IFN- $\alpha/\beta R^{o/o}$ mice described above, these animals remained well until the 2nd wk p.i. (Fig. 1). At that time, mild paresis of the hind legs appeared in all animals. Paralysis worsened with time,

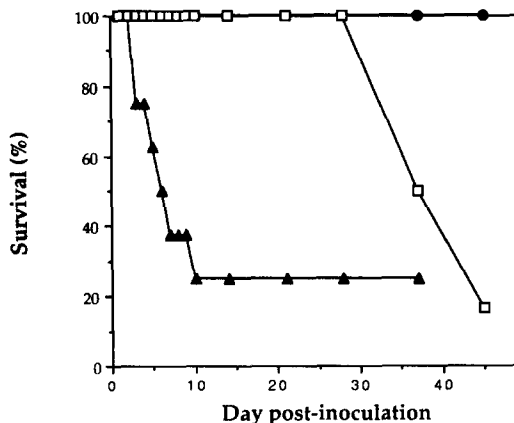


Figure 2. Survival of the animals as a function of time p.i. Mice were inoculated intracerebrally with 10^4 PFU of the DA strain of Theiler's virus and observed daily. (●): Control mice, (▲): IFN- $\alpha/\beta R^{o/o}$, (□): IFN- $\gamma R^{o/o}$. The number of mice in each group was control = 13, IFN- $\alpha/\beta R^{o/o}$ = 8, and IFN- $\gamma R^{o/o}$ = 6.

and by 5–6 wk p.i., the animals were totally paralyzed and had tachypnea (Fig. 1). Out of the six animals, five died of this disease during the 6th wk p.i. (Fig. 2). Five out of six control 129Sv mice remained asymptomatic and one presented with stable residual hind legs paralysis, a sequel of early disease.

In a second experiment, nine IFN- $\gamma R^{o/o}$ and eight control 129Sv mice were inoculated and killed at various times p.i. Routine histology was performed on three IFN- $\gamma R^{o/o}$ and three 129Sv control mice killed 4 d p.i., a time that corresponds to the early disease. In spite of the lack of clinical symptoms, histological signs of acute encephalitis with neuronal necrosis and inflammation were observed in both the IFN- $\gamma R^{o/o}$ and control animals. Viral antigens were detected by immunohistochemistry performed on adjacent sections. Infected cells were found in the gray matter of the brain in association with the lesions described above (Fig. 3 C). A small number of infected cells were also found in the gray matter of the spinal cord.

Viral replication in the brain of five IFN- $\gamma R^{o/o}$ and five control 129Sv mice was studied 3 d p.i., as described above for IFN- $\alpha/\beta R^{o/o}$ mice. As shown in Fig. 4, the levels of viral RNA were low and very similar in the two groups.

36 d p.i., the histopathological findings were strikingly different in the control and the IFN- $\gamma R^{o/o}$ mice (three animals in each group). Inflammatory infiltrates were absent, or they were found only in small numbers, in the gray matter of spinal cord of the control 129Sv mice. The white matter of these mice was normal (Fig. 5 B). In contrast, very severe and extensive lesions were observed in the white matter of IFN- $\gamma R^{o/o}$ mice (Fig. 5 A). They consisted in meningitis, perivascular cuffs, and diffuse parenchymal infiltration by inflammatory cells. Signs of extensive demyelination were conspicuous, particularly in the thoracic and lumbar spinal cord. In these areas, the white matter appeared pale and distorted (Fig. 5 A). Inflammatory cells had the morphology of lymphocytes, plasma cells, and mononuclear phagocytes. Demyelinated areas contained a large number of "foamy" mononuclear phagocytes that could be stained with the F4/80 monoclonal antibody (not shown). In some areas, fibrosis was observed in the meninges and in the adjacent white matter. Less severe lesions coexisted with those described above. They were found mainly in the cervical spinal cord and they consisted of focal inflammation associated with vacuolization of the white matter. Besides the spinal cord, where they predominated, white matter lesions could also be found in cerebellum and, in a milder form, in the brain.

Semi-thin plastic-embedded, transverse sections of spinal cord were prepared from three IFN- $\gamma R^{o/o}$ mice that were killed 28 d p.i. They showed well-demarcated white matter lesions (Fig. 5 C) in which the myelin sheaths were vacuolated and distorted or completely absent. Demyelinated axons appeared well preserved. Large cells laden with myelin debris were conspicuous. Ultra-thin sections were prepared from the same tissue samples. They confirmed the existence of primary demyelination associated with inflammation and the presence of myelin-laden macrophages. No viral paracrystalline arrays were observed in these sections (not shown).

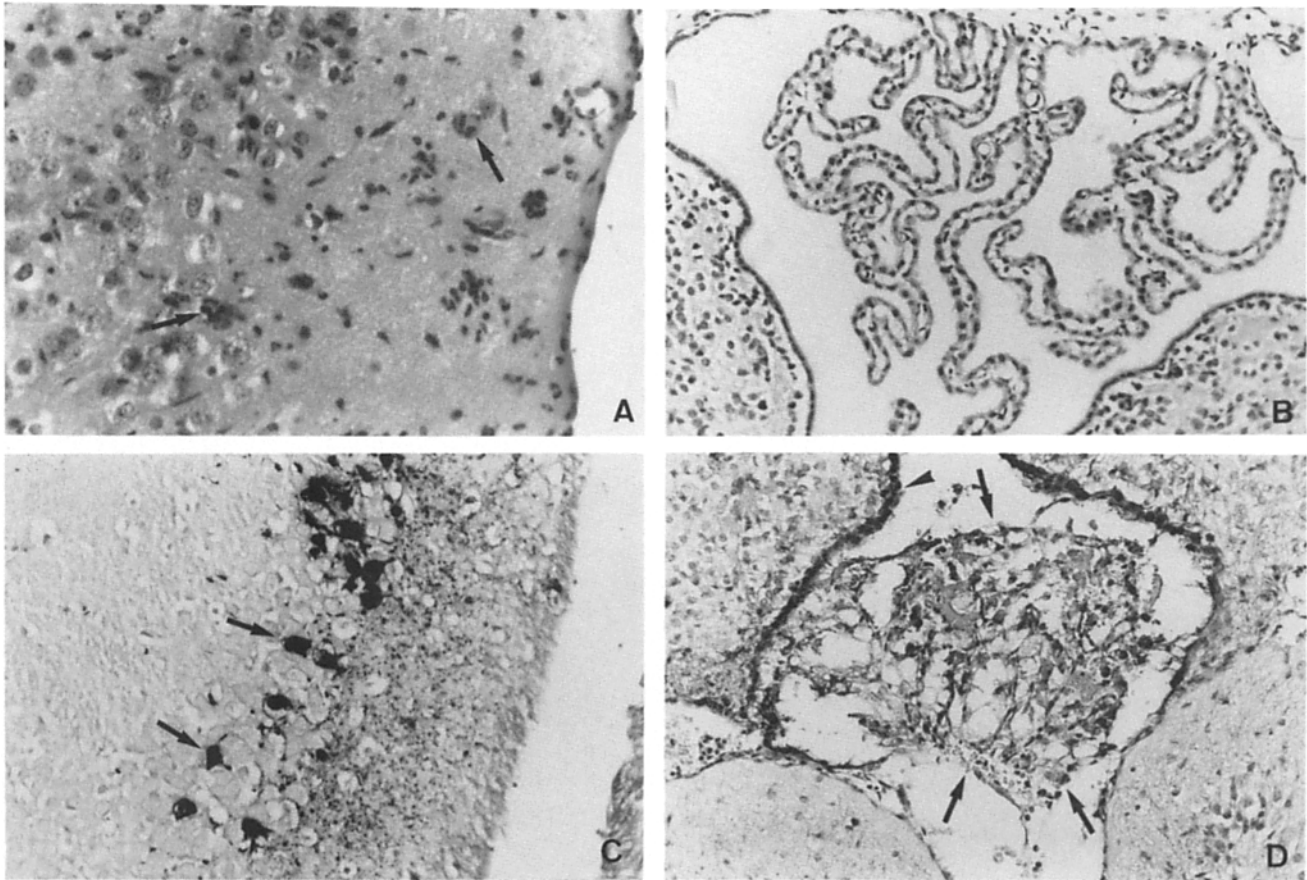


Figure 3. Histopathology found in coronal sections of the brain of control 129Sv, IFN- $\alpha/\beta R^{0/0}$, and IFN- $\gamma R^{0/0}$ mice, respectively, 3, 3, and 4 d after intracerebral inoculation. (A) Inflammation with polymorphonuclear cells (arrows) in the cerebral cortex of an IFN- $\alpha/\beta R^{0/0}$ mouse. The sections were stained with hematoxylin eosin. Original magnification: $\times 787.5$. (B) Choroid plexus of a control 129Sv mouse. The sections were stained with hematoxylin eosin. Original magnification: $\times 500$. (C) Cerebral cortex of an IFN- $\gamma R^{0/0}$ mouse. Viral antigens were detected, by immunocytochemistry, in several neurons (arrows). Counter staining was with hematoxylin. Original magnification: $\times 500$. (D) Inflammation and necrosis in the choroid plexus (arrows) of an IFN- $\alpha/\beta R^{0/0}$ mouse. Viral antigens were detected by immunocytochemistry in the necrotic choroid plexus and in the ependymal cells (arrowhead). Original magnification: $\times 500$.

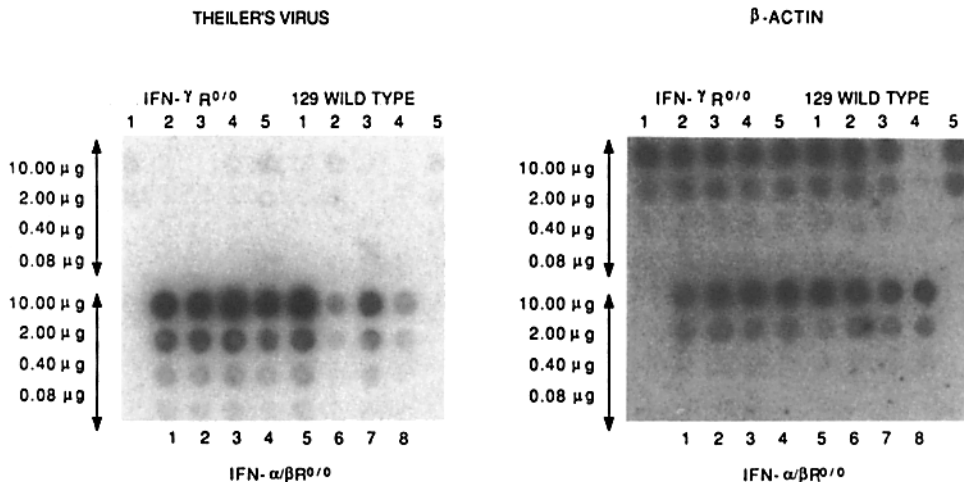


Figure 4. Quantitation of the amount of viral RNA present in the brain of eight IFN- $\alpha/\beta R^{0/0}$, five IFN- $\gamma R^{0/0}$ and five control 129Sv mice 3 d p.i. Serial fivefold dilutions of total RNA extracted from the brain were filtered on two Hybond-C extra filters (Amersham). The filters were hybridized with either a β -actin-specific or a Theiler's virus-specific ^{32}P -labeled cDNA probe. After washing, the filters were exposed to x-ray-sensitive films.

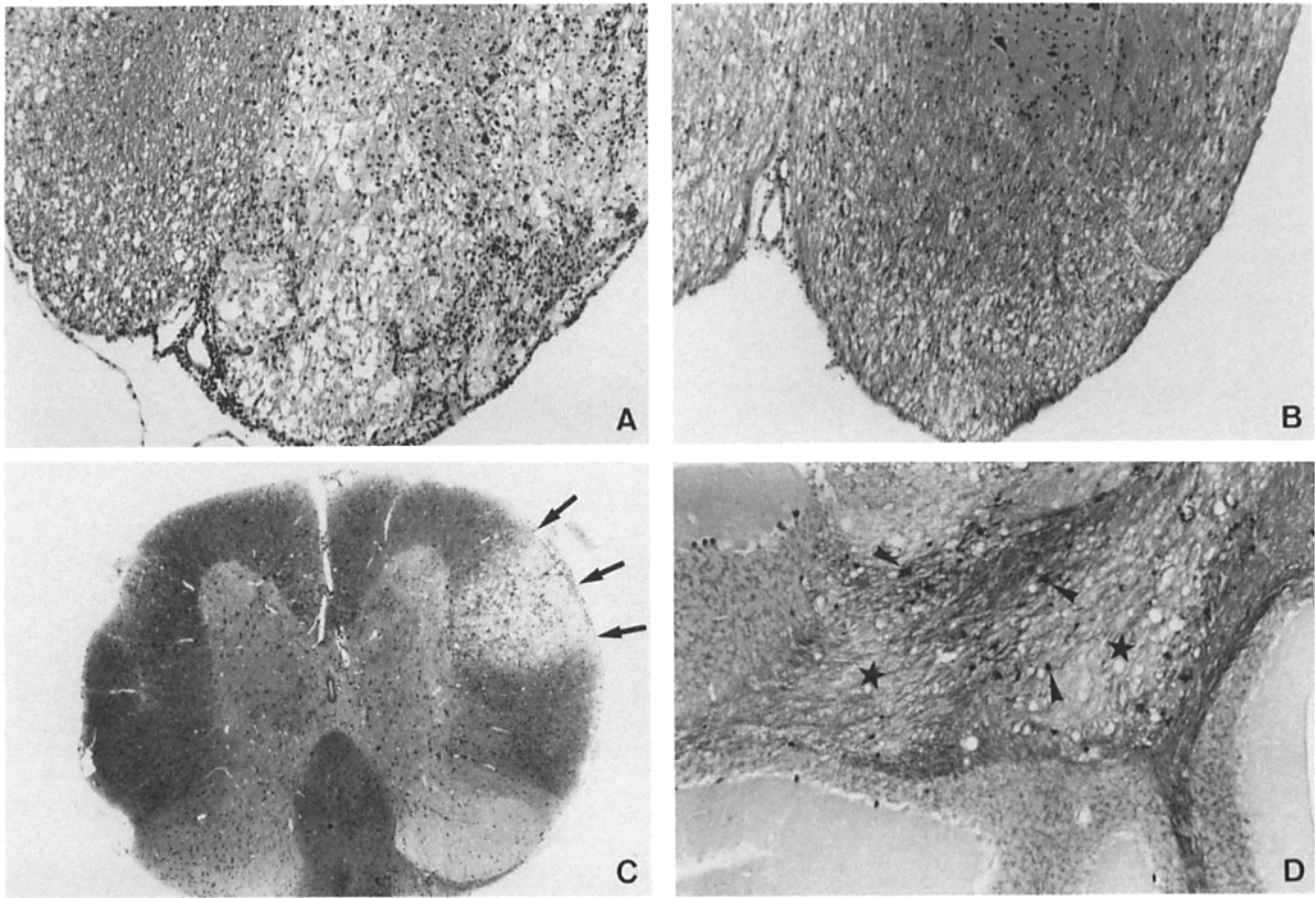


Figure 5. Histopathology found in the CNS of IFN- γ R^{0/0} and control 129Sv mice. (A) Longitudinal section of the spinal cord of an IFN- γ R^{0/0} mouse killed 36 d p.i. The section shows meningoencephalitis, inflammation of the white matter by mononuclear cells, and extensive demyelination. Original magnification: $\times 125$. (B) Longitudinal section of the spinal cord of a control 129Sv mouse killed 36 d p.i. Original magnification: $\times 125$. (C) Semi-thin transverse section of the spinal cord of an IFN- γ R^{0/0} mouse killed 28 d p.i. The arrows point to a focus of severe demyelination. Original magnification: $\times 79$. (D) Detection of viral antigens by immunocytochemistry in the cerebellum of an IFN- γ R^{0/0} mouse at 36 d p.i. The section was counter stained with Luxol fast blue. Infected cells (arrowheads) are surrounding two areas of the white matter with demyelination (stars). Original magnification: $\times 312.5$.

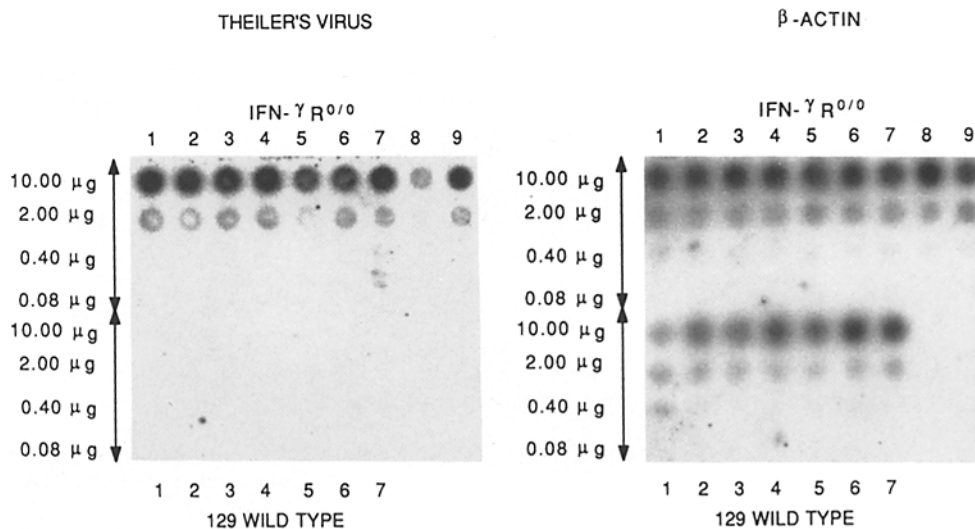


Figure 6. Quantitation of the amount of viral RNA present in the spinal cord of nine IFN- γ R^{0/0} and seven control 129Sv mice 32 d p.i. Serial fivefold dilutions of total RNA extracted from the brain were filtered on two Hybond C-extra filters (Amersham). The filters were hybridized with either a β -actin specific or a Theiler's virus specific ³²P-labeled cDNA probe. After washing, the filters were exposed to x-ray-sensitive films.

We used immunohistochemistry to search for viral antigens 36 d p.i. In control mice, no antigens were found in the brain and only a few antigen-positive cells were observed in the spinal cord. On the contrary, numerous infected cells were found in the white matter, and occasionally in the gray matter, of the spinal cords of IFN- γ R^{o/o} mice. Viral antigens were also present in the lesions of cerebrum and cerebellum. Interestingly, infected cells were present mostly at the margin of the lesions and only rarely in their center (Fig. 5 D).

Viral RNA was quantitated in the spinal cord of nine IFN- γ R^{o/o} mice and seven control 129Sv mice killed 32 d p.i. (Fig. 6). As shown in that figure, viral RNA was detected easily in the spinal cords of the IFN- γ R^{o/o} mice, whereas no viral RNA could be detected in the controls.

Discussion

A gene responsible for the susceptibility of SJL/J mice to the persistent infection by Theiler's virus has been located close to *Ifg*, the gene coding for IFN- γ (22). The *Ifg* gene is a good candidate gene for the control of susceptibility because of the antiviral and immunoregulatory activities of IFN- γ . To examine the putative role of the *Ifg* gene in the control of viral persistence, we determined the effects of inactivating the IFN- γ system on the disease caused by the Theiler's virus. We showed that IFN- γ plays an important role in the resistance of the 129Sv mouse since this mouse became extremely susceptible after inactivation of the gene coding for the IFN- γ receptor. To strengthen this conclusion, it will be important to examine 129Sv mice in which the gene coding for IFN- γ , as opposed to the gene coding for its receptor, has been inactivated since it is theoretically possible that the ligand-binding chain of the IFN- γ receptor, which was inactivated in the IFN- γ R^{o/o} mice, is also involved in transducing the signals given by other cytokines.

The infection of susceptible mice by Theiler's virus is studied chiefly because it causes chronic inflammation and demyelination that resembles the lesions found in multiple sclerosis. The mechanism of demyelination in this model disease is poorly understood, although it most likely involves the immune system. Whatever this mechanism may be, our results show that the IFN- γ system is not required for demyelination.

Our results demonstrate a striking absence of redundancy of the two IFN systems in controlling the infection of CNS by Theiler's virus. To interpret this observation, it is necessary to distinguish between the direct antiviral effect of both

IFN- α/β and IFN- γ , as well as the indirect immunomodulatory effects of IFN- γ . The IFN- α/β response, which takes place within the infected cells, is very rapid and may limit the early spread of the infection. Therefore, it may not be compensated by the IFN- γ response, which is slower since it depends on the activation of the immune system. This would explain that IFN- α/β R^{o/o} mice died of acute early gray matter encephalomyelitis. On the other hand, the antiviral effect of IFN- γ may be more important for the control of the late phase of the disease during which infected cells are surrounded by T lymphocytes. It is also tempting to relate this nonredundancy to the fact that the virus infects mainly neurons during the early stages of the disease, whereas it infects glial cells during the late stages. It might be interesting to examine the expression of the receptors for the two types of IFN on these two categories of CNS cells.

Inactivating the IFN- γ receptor could also allow persistence of the infection through an immune-mediated mechanism. We showed previously that resistance to the late disease was due in great part to class I-restricted responses, presumably CD8⁺ virus specific CTLs (21, 30–33). The inactivation of the IFN- γ system could affect the expression of class I molecules on infected cells or, as suggested recently, the processing of viral proteins by the proteasome (34–36). In either case, recognition by CTLs would be impaired.

We observed an infection of the choroid plexus, ependyma, and meninges associated with polymorphonuclear inflammation only in the IFN- α/β R^{o/o} mice. Interestingly, Penney and Wolinsky made the same observation with newborn ICR mice infected with the WW strain of Theiler's virus (37). This could indicate the existence of a defect of the IFN- α/β system in these new-born mice. The permissiveness of the choroid plexus, ependyma and meninges of IFN- α/β R^{o/o} mice to Theiler's virus replication may favor the diffusion of the infection within the CNS of these mice via the cerebrospinal fluid.

In conclusion, we showed that inactivating the IFN- γ R renders resistant 129Sv mice extremely susceptible to persistent infection in the CNS by Theiler's virus and to late demyelinating disease. This result strengthens the possibility that the *Ifg* gene on chromosome 10 is one of the genes that controls viral persistence. We also showed that the IFN- α/β and IFN- γ systems are nonredundant in this infection. The former controls the early gray matter infection, whereas the latter controls the persistence of the infection in the white matter.

We thank C. Dauguet for performing the electron microscopy, C. Pena-Rossi, A. McAllister, and C. Sotelo for helpful discussions, and M. Gau for preparing the manuscript.

This work was supported by grants from the Institut Pasteur Foundation, the Centre National de la Recherche Scientifique, the Association pour la Recherche sur la Sclérose en Plaques, and the National Multiple Sclerosis Society.

Address correspondence to Pr. Michel Brahic, Unité des Virus Lents, Institut Pasteur, 28 rue du Dr. Roux, 75724 Paris Cedex 15. The present address for Michel Aguet is Genentech, Inc., Molecular Biology Dept., 460 Point San Bruno Blvd., South San Francisco, CA 94080-4990.

Received for publication 27 September 1994 and in revised form 3 February 1995.

References

1. Daniels, J.B., A.M. Pappenheimer, and S. Richardson. 1952. Observations on encephalomyelitis of mice (DA strain). *J. Exp. Med.* 96:22-24.
2. Lipton, H.L. 1975. Theiler's virus infection in mice: an unusual biphasic disease process leading to demyelination. *Infect. Immun.* 11:1147-1155.
3. Stroop, W.G., J.R. Baringer, and M. Brahic. 1981. Detection of Theiler's virus RNA in mouse central nervous system by in situ hybridization. *Lab. Invest.* 45:504-509.
4. Lipton, H.L., J. Kratochvil, P. Sethi, and M.C. Dal Canto. 1984. Theiler's virus antigen detected in mouse spinal cord 2 1/2 years after infection. *Neurology.* 34:1117-1119.
5. Aubert, C., M. Chamorro, and M. Brahic. 1987. Identification of Theiler's virus infected cells in the central nervous system of the mouse during demyelinating disease. *Microb. Pathog.* 3:319-326.
6. Clatch, R.J., S.D. Miller, R. Metzner, M.C. Dal Canto, and H.L. Lipton. 1990. Monocytes/macrophages isolated from the mouse central nervous system contain infectious Theiler's murine encephalomyelitis virus (TMEV). *Virology.* 176:244-254.
7. Ozden, S., C. Aubert, D. Gonzalez-Dunia, and M. Brahic. 1991. In situ analysis of proteolipid protein gene transcripts during persistent Theiler's virus infection. *J. Histochem. & Cytochem.* 39:1305-1309.
8. Roos, R.P., and R. Wollmann. 1984. DA strain of Theiler's murine encephalomyelitis virus induces demyelination in nude mice. *Ann. Neurol.* 15:494-499.
9. Rosenthal, A., R.S. Fujinami, and P.W. Lampert. 1986. Mechanism of Theiler's virus induced demyelination in nude mice. *Lab. Invest.* 54:515-522.
10. Zurbriggen, A., M. Yamada, C. Thomas, and R. Fujinami. 1991. Restricted virus replication in the spinal cords of nude mice infected with a Theiler's virus variant. *J. Virol.* 65:1023-1030.
11. Gerety, S.J., R.J. Clatch, H.L. Lipton, R.G. Goswami, M.K. Rundell, and S.D. Miller. 1991. Class II-restricted T cell responses in Theiler's murine encephalomyelitis virus-induced demyelinating disease. IV. Identification of an immunodominant T cell determinant on the N-terminal end of the VP2 capsid protein in susceptible SJL/J mice. *J. Immunol.* 146:2401-2408.
12. Gerety, S.J., W.J. Karpus, A.R. Cubbon, R.G. Goswami, M.K. Rundell, J.D. Peterson, and S.D. Miller. 1994. Class II-restricted T cell responses in Theiler's murine encephalomyelitis virus-induced demyelinating disease. V. Mapping of a dominant immunopathologic VP2 T cell epitope in susceptible SJL/J mice. *J. Immunol.* 152:908-918.
13. Gerety, S.J., M.K. Rundell, M.C. Dal Canto, and S.D. Miller. 1994. Class II-restricted T cell responses in Theiler's murine encephalomyelitis virus-induced demyelinating disease. *J. Immunol.* 152:919-929.
14. Clatch, R.J., R.W. Melvold, M.C. Dal Canto, S.D. Miller, and H.L. Lipton. 1987. The Theiler's murine encephalomyelitis virus (TMEV) model for multiple sclerosis shows a strong influence of the murine equivalents of HLA-A, B, and C. *J. Neuroimmunol.* 15:121-135.
15. Miller, S., and S. Gerety. 1990. Immunologic aspects of Theiler's murine encephalomyelitis virus (TMEV)-induced demyelinating disease. *Semin. Virology.* 1:263-272.
16. Clatch, R.J., R.W. Melvold, S.D. Miller, and H.L. Lipton. 1985. Theiler's murine encephalomyelitis virus (TMEV) induced demyelinating disease in mice is influenced by the H-2D region: correlation with TMEV specific delayed-type hypersensitivity. *J. Immunol.* 135:1408-1413.
17. Patick, A.K., L.R. Pease, C.S. David, and M. Rodriguez. 1990. Major histocompatibility complex-conferred resistance to Theiler's virus-induced demyelinating disease is inherited as a dominant trait in B10 congenic mice. *J. Virol.* 64:5570-5576.
18. Rodriguez, M., and C.S. David. 1985. Demyelination induced by Theiler's virus: influence of the H-2 haplotype. *J. Immunol.* 135:2145-2148.
19. Rodriguez, M., J.L. Leibowitz, and C.S. David. 1986. Susceptibility to Theiler's virus-induced demyelination. Mapping of the gene within the H-2D region. *J. Exp. Med.* 163:620-631.
20. Bureau, J.F., X. Montagutelli, S. Lefebvre, J.-L. Guénet, M. Pla, and M. Brahic. 1992. The interaction of two groups of murine genes controls the persistence of Theiler's virus in the central nervous system. *J. Virol.* 66:4698-4704.
21. Azoulay, A., M. Brahic, and J.F. Bureau. 1994. FVB mice transgenic for the D^b gene become resistant to persistent infection by Theiler's virus. *J. Virol.* 68:4049-4052.
22. Bureau, J.F., X. Montagutelli, F. Bihl, S. Lefebvre, J.L. Guénet, and M. Brahic. 1993. Mapping loci influencing the persistence of Theiler's virus in the murine central nervous system. *Nature Genet.* 5:87-91.
23. Lopez-Guerrero, J.A., F.X. Pimentel-Muinos, M. Fresno, and M.A. Alonso. 1990. Role of soluble cytokines on the restricted replication of poliovirus in the monocytic U937 cell line. *Virus Res.* 16:225-230.
24. Ramamurthy, V., and R.J. Fleischmann. 1986. Independent regulation of the antiviral states induced by MuIFN- α/β and by MuIFN- γ . *J. Gen. Virol.* 67:2223-2226.
25. Pitkäranta, A., K. Linnavuori, M. Roivainen, and H. Tapani. 1988. Induction of interferon- α in human leukocytes by polioviruses: Wild-type strains are better inducers than attenuated strains. *Virology.* 165:476-481.
26. Gresser, I., M.G. Tovey, M.T. Bandu, C. Maury, and D. Brouty-Boyé. 1976. Role of interferon in the pathogenesis of virus diseases in mice as demonstrated by the use of anti-interferon serum. I. Rapid evolution of encephalomyocarditis virus infection. *J. Exp. Med.* 144:1305-1315.
27. Lutton, C.W., and C.J. Gauntt. 1985. Ameliorating effect of IFN- β and anti-IFN- β on coxsackievirus B3-induced myocarditis in mice. *J. Interferon Res.* 5:137-146.
28. Huang, S., W. Hendriks, A. Althage, S. Hemmi, H. Bluethmann, R. Kamijo, J. Vilcek, R.M. Zinkernagel, and M. Aguet. 1993. Immune response in mice that lack the interferon- γ

- receptor. *Science (Wash. DC)*. 259:1742-1745.
29. Müller, U., U. Steinhoff, L.F.L. Reis, S. Hemmi, J. Pavlovic, R.M. Zinkernagel, and M. Aguet. 1994. Functional role of type I and type II interferons in antiviral defense. *Science (Wash. DC)*. 264:1918-1921.
 30. Fiette, L., C. Aubert, M. Brahic, and C. Pena Rossi. 1993. Theiler's virus infection of $\beta 2$ -microglobulin-deficient mice. *J. Virol.* 67:589-592.
 31. Pullen, L.C., S.D. Miller, M.C. Dal Canto, and B.S. Kim. 1993. Class I-deficient resistant mice intracerebrally inoculated with Theiler's virus show an increased T cell response to viral antigens and susceptibility to demyelination. *Eur. J. Immunol.* 23:2287-2293.
 32. Rodriguez, M., A.J. Dunkel, R.L. Thiemann, J. Leibowitz, M. Zijlstra, and R. Jaenisch. 1993. Abrogation of resistance to Theiler's virus-induced demyelination in H-2^b mice deficient in $\beta 2$ -microglobulin. *J. Immunol.* 151:255-276.
 33. Pena Rossi, C., A. McAllister, L. Fiette, and M. Brahic. 1991. Theiler's virus infection induces a specific cytotoxic T lymphocyte response. *Cell. Immunol.* 138:341-348.
 34. Driscoll, J., M.G. Brown, D. Finley, and J.J. Monaco. 1993. MHC-linked LMP gene products specifically alter peptidase activities of the proteasome. *Nature (Lond.)*. 365:262-267.
 35. Gaczynska, M., K.L. Rock, and A.L. Goldberg. 1993. Gamma-interferon and expression of MHC genes regulate peptide hydrolysis by proteasomes. *Nature (Lond.)*. 365:264-267.
 36. Boes, B., H. Hengel, T. Ruppert, G. Mulhaup, U.H. Koszinowski, and P.M. Kloetzel. 1994. Interferon gamma stimulation modulates the proteolytic activity and cleavage site preference of 20S mouse proteasomes. *J. Exp. Med.* 179:901-909.
 37. Penney, J.B., and J.S. Wolinsky. 1979. Neuronal and oligodendroglial infection by the WW strain of Theiler's virus. *Lab Invest.* 40:324-330.