



**HAL**  
open science

## Combined medico-surgical strategy for invasive sino-orbito-cerebral breakthrough fungal infection with *Hormographiella aspergillata* in an acute leukaemia patient

M. Heiblig, V. Bozzoli, J. Saison, X. Thomas, D. de Croze, A. Traverse-Glehen, A. Cosmidis, C. Chidiac, Tristan Ferry, Alexandre Alanio, et al.

### ► To cite this version:

M. Heiblig, V. Bozzoli, J. Saison, X. Thomas, D. de Croze, et al.. Combined medico-surgical strategy for invasive sino-orbito-cerebral breakthrough fungal infection with *Hormographiella aspergillata* in an acute leukaemia patient. *Mycoses*, 2015, 58 (5), pp.308–312. 10.1111/myc.12305 . pasteur-01405220

**HAL Id: pasteur-01405220**

**<https://pasteur.hal.science/pasteur-01405220v1>**

Submitted on 29 Nov 2016

**HAL** is a multi-disciplinary open access archive for the deposit and dissemination of scientific research documents, whether they are published or not. The documents may come from teaching and research institutions in France or abroad, or from public or private research centers.

L'archive ouverte pluridisciplinaire **HAL**, est destinée au dépôt et à la diffusion de documents scientifiques de niveau recherche, publiés ou non, émanant des établissements d'enseignement et de recherche français ou étrangers, des laboratoires publics ou privés.



Distributed under a Creative Commons Attribution 4.0 International License

# Combined medico-surgical strategy for invasive sino-orbito-cerebral breakthrough fungal infection with *Hormographiella aspergillata* in an acute leukaemia patient

M. Heiblig,<sup>1</sup> V. Bozzoli,<sup>1</sup> J. Saison,<sup>2</sup> X. Thomas,<sup>1</sup> D. De Croze,<sup>3</sup> A. Traverse-Glehen,<sup>3</sup> A. Cosmidis,<sup>4</sup> C. Chidiac,<sup>2</sup> T. Ferry,<sup>2,5</sup> A. Alanio,<sup>6,7</sup> A. L. Bienvenu,<sup>8,9</sup> D. Dupont,<sup>8</sup> S. Ducastelle-Lepretre,<sup>1</sup> M. Michallet<sup>1</sup> and F. Ader<sup>2,5</sup> on behalf of the Lyon HEMINF Study group\*

<sup>1</sup>Service d'Hématologie 1G, Centre Hospitalier Lyon Sud, Hospices Civils de Lyon, Pierre Bénite, France, <sup>2</sup>Service de Maladies Infectieuses et Tropicales, Hôpital de la Croix-Rousse, Hospices Civils de Lyon, Lyon, France, <sup>3</sup>Laboratoire d'Anatomie et de cytopathologie, Centre Hospitalier Lyon Sud, Hospices Civils de Lyon, Pierre Bénite, France, <sup>4</sup>Service d'Otorhinolaryngologie, Centre Hospitalier Lyon Sud, Hospices Civils de Lyon, Pierre Bénite, France, <sup>5</sup>Inserm U1111 Centre International de Recherche en Infectiologie (CIRI), Université Claude Bernard Lyon 1, Lyon, France, <sup>6</sup>Service de Parasitologie-Mycologie, Groupe Hospitalier Lariboisière, Saint Louis Fernand Widal, Université Paris Diderot, Sorbonne Paris Cité, Paris, France, <sup>7</sup>Institut Pasteur, Unité de Mycologie moléculaire, CNRS URA3012, Paris, France, <sup>8</sup>Institut de Parasitologie et Mycologie Médicale, Hospices Civils de Lyon, Lyon, France and <sup>9</sup>Malaria Research Unit, ICBMS, CNRS UMR 5246, Lyon 1 University, Lyon, France

## Summary

*Hormographiella aspergillata* is a rare causative agent of invasive filamentous breakthrough infection, mostly arising after echinocandin exposure. We report a neutropenic patient who developed a severe sino-orbito-cerebral *H. aspergillata* infection while receiving empirical caspofungin, successfully controlled by an aggressive strategy associating surgical debridement and combined high-dose regimen of antifungal drugs.

**Key words:** basidiomycosis, *Hormographiella aspergillata*, acute myeloid leukaemia, allogeneic haematopoietic stem cell transplantation.

## Introduction

Among patients with haematological malignancies, invasive fungal infections (IFI) mostly occur during the profound and durable neutropenia in those with

acute leukaemia and allogeneic stem cell transplantation settings. *Aspergillus* spp. remain the most common cause of fungal pneumonia. The incidence is 5–25% in acute myeloid leukaemia and 4–10% in transplanted patients.<sup>1</sup> *Hormographiella aspergillata*, the asexual form of *Coprinopsis cinerea* (formerly *Coprinus cinereus*), is a member of the Order Agaricales (Phylum Basidiomycota), an ubiquitous fungus likely found in sewage and compost. Although airborne spores are abundantly present in the environment, filamentous basidiomycetes are rarely reported as a cause of IFI in immunocompromised patients. Here, we report a case of sino-orbito-cerebral infection due to *H. aspergillata* in an acute myeloid leukemia (AML) patient empirically treated with caspofungin.

Correspondence: F. Ader, MD, PhD, Service de Maladies Infectieuses et Tropicales, Hôpital de la Croix-Rousse, 103 Grande-Rue de la Croix-Rousse, 69317 Lyon Cedex 04, France.

Tel.: +33 472 071 560. Fax: +33 472 072 441.

E-mail: florence.ader@chu-lyon.fr

\*The Lyon HEMINF Study group: F. Ader, E. Bachy, M. Balsat, F. Barraco, A. L. Bienvenu, G. Billaud, F. Biron, A. Boibieux, C. Chidiac, A. Conrad, S. Ducastelle-Lepretre, O. Dumitrescu, D. Dupont, V. Escuret, T. Ferry, E. Frobert, L. Gilis, A. Grateau, M. Heiblig, H. Labussière-Wallet, M. Le Maréchal, L. Lebras, B. Lina, G. Lina, A. Quintela, P. Miaillhes, A.-S. Michallet, M. Michallet, M.-C. Michallet, G. Monneret, F. Morfin-Sherpa, F. E. Nicolini, T. Perpoint, M. Peyrouse de Montclos, S. Picot, F. Poitevin-Later, A. G. Ranc, S. Roux, G. Salles, J. Saison, A. Sénéchal, M. Sobh, X. Thomas, F. Valour, E. Wattel.

Submitted for publication 25 October 2014

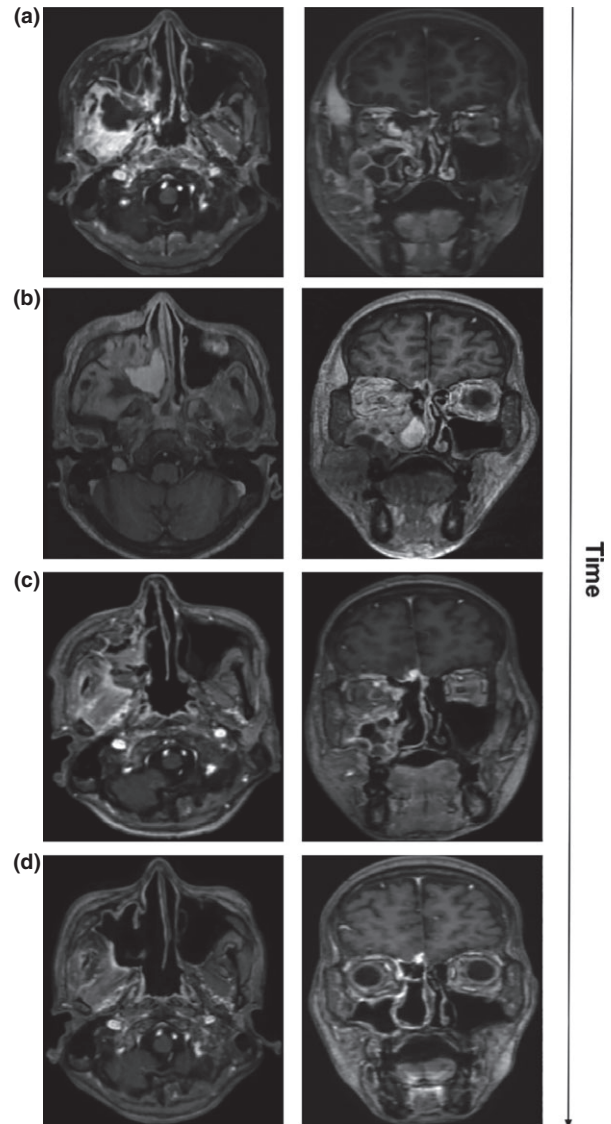
Revised 26 January 2015

Accepted for publication 28 January 2015

## Case report

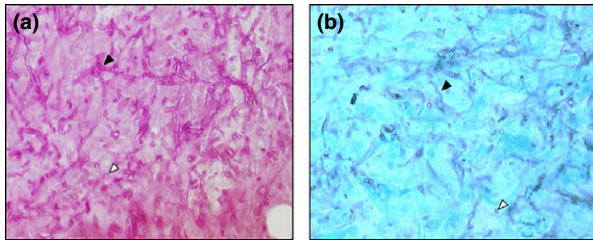
A 19-year-old man had a long-lasting follow-up at our institution for a complex mitochondrial cytopathy complicated by a myelodysplastic syndrome. In 2013, he had developed a refractory anaemia with blast

excess followed by a secondary AML with a persistent neutropenic fever. Upon symptoms of abdominal pain, computed tomography (CT)-scan revealed an indolent appendicular abscess, as well as multiple hepatic abscesses with septic portal thrombophlebitis. The patient underwent laparoscopic surgery for appendicular removal. Empirical broad-spectrum beta-lactam piperacillin-tazobactam was initiated prior to surgery, as well as primary prophylaxis by oral posaconazole according to the centre practice for AML patients. Both blood and per-operative specimen cultures were positive for extended-spectrum beta-lactamase *Escherichia coli*, then treated with targeted combination of meropenem and fosfomycin. Because of persistent post-operative fever under appropriate antibiotic regimen as well as unsatisfactory plasma levels of posaconazole, antifungal treatment was switched on empirical caspofungin with subsequent fever amendment. The latter was maintained throughout the 10-week aplasia phase after the induction chemotherapy initiated shortly after sepsis control. The patient was discharged and clinical symptoms of right acute maxillary and sphenoidal sinusitis appeared, subsequently confirmed by CT-scan. A 10-day course of oral ciprofloxacin was prescribed and the patient was switched back on prophylactic posaconazole. The decision was taken to perform allogeneic haematopoietic stem cell transplantation (allo-HSCT) using an HLA-matched unrelated donor graft. During the intensive conditioning phase, an extensive facial cellulitis appeared, confirmed by magnetic resonance imaging (MRI) showing a left infra-temporal abscess without osteolysis (Fig. 1a). Serum galactomannan was negative and posaconazole serum level was measured below range ( $<700 \mu\text{g l}^{-1}$ ). Liposomal amphotericin B (L-AmB) was then started ( $5 \text{ mg kg}^{-1} \text{ day}^{-1}$ ) and posaconazole interrupted. Allo-HSCT procedure was interrupted and a multidisciplinary approach rapidly led to the decision of carrying out a sinusal surgery of debridement. Histopathological examinations as well as microbial cultures performed on surgical specimens were not contributive. The patient clinical condition deteriorated with anosmia and extensive chemosis. Intravenous voriconazole was added to L-AmB. A second MRI showed an extension with intra-orbitary infiltration, sinus cavernous thrombophlebitis and signs of local meningitis (Fig. 1b). Cerebrospinal fluid (CSF) analysis was normal with a protein level  $<0.4 \text{ g l}^{-1}$ , a glucose CSF/blood ratio at  $0.9 \text{ mmol l}^{-1}$ , a white blood cell count  $<2 \text{ mm}^{-3}$  and an undetectable CSF galactomannan antigen. A second surgery procedure was decided and performed with a larger sinus trepanation and



**Figure 1** MRI sequences of the *Hormoglyphiella* sino-orbito-cerebral infection (all pictures are T1 sequences with gadolinium injection). (a) Right infra-temporal abscess with intra-orbitary and homolateral cavernous sinus extension associated with lepto and pachy-meningitis. (b) Increase in sinus infiltration and rhinencephalus meningitis with a sinus cavernous thrombophlebitis. (c) Diminution of sinus infiltration and stability of the rhinencephalus thickening but extension of the parenchymatous oedema in the setting of neutrophils recovery. (d) Sinusal and encephalic improvements after two surgical resections and anti-fungal combination treatment.

intensive scraping. Histopathological examinations evidenced a filamentous fungus (Fig. 2). Samples were processed according to standard mycology laboratory procedures, e.g. after microscopic examination with Gomori-Grocott silver staining, they were rapidly plated on Sabouraud medium and on Candida ID2



**Figure 2** Periodic acid-Schiff stain (a) and Gomori-Grocott stain (b) performed on a surgical biopsy showed septated (black arrow) and branched hyphae with formation of clews (white arrow) ( $\times 40$ ). Typical features of *Hormographiella aspergillata* are hyaline, septate hyphae combined with macronematous conidiophores. Usually, the conidiophores are overwhelmed by thin-walled adherent conidia.

chromogenic medium (Biomérieux, Craaponne, France). The media were incubated for 7 days at 37 °C. A single colony grew out of the surgical biopsy on day 7 identified as *H. aspergillata*. Indeed, microscopic examination with lactophenol cotton blue revealed vegetative hyaline septate hyphae, and hyaline conidia. Consistently with classical description, conidiophores were slightly differentiated with a basal septum and with an apical part with repeated sympodial branching.<sup>2</sup> Conidia were cylindrical with truncated ends. Unfortunately, *in vitro* antifungal susceptibility testing could not be performed, as the isolate did not grow any further due to tissue saturation with antifungal drugs initiated prior to sequential surgeries. To validate the microscopic-based identification, a PCR-based approach was carried out. Ten slices of 10  $\mu\text{m}$  sections of formalin-fixed paraffin embedded tissue were pooled for DNA extraction with QIAamp DNA mini kits (Qiagen, Courtaboeuf, France), according to the manufacturer's recommendations. Three PCR assays using ITS1-ITS2, ITS5-ITS2 and ITS3-ITS4 primer pairs were performed and the amplification products were sequenced.<sup>3</sup> The ITS1-ITS2 and ITS3-ITS4 assays allowed identification of *H. aspergillata* with 99.2% (score 481.2, GenBank: AF345819.1) and 100% (score 601.6, GenBank: AB097562.1) similarity, respectively, compared to the reference sequences using Mycobank database (<http://www.mycobank.org/BioMICSSequences.aspx?expandparm=f&file=all>). Antifungal drug doses were optimised with L-AmB at 10 mg kg<sup>-1</sup> day<sup>-1</sup> and voriconazole maintained in tight therapeutic ranges. An MRI control assessed the treatment efficiency by local control of the fungal infection (Fig. 1c). Haematological recovery occurred at day 43, resulting in a reduction of sinus infiltration and central nervous system involvement (Fig. 1d).

Unfortunately, complete remission of the underlying haematological condition was not achieved, shortly followed by AML relapse. Antifungal combination was maintained, with a baseline L-AmB dose lowered at 5 mg kg<sup>-1</sup> day<sup>-1</sup> to favour long-term good tolerance profile. A second attempt of allo-HSCT was then decided with prior intensive conditioning. A day prior to the allo-HSCT, the patient deceased from a fulminant septic shock with multi-organ failure, credited to *Enterobacter cloacae* upon blood culture identification. Written informed consent was obtained from the patient's family for publication of this case report and any accompanying images.

## Discussion

Acute leukaemia patients undergoing intensive chemotherapy regimen before allo-HSCT are at an increased risk of IFI. *Aspergillus* spp. and *Candida* spp. are the fungi that are involved most frequently. Invasive aspergillosis-related mortality is still up to 20–30%, depending on the underlying haematological condition, comorbidities prior to transplantation, and the site of infection.<sup>1</sup> In recent years, many new antifungal drugs have become available, including polyene L-AmB, extended-spectrum azoles (voriconazole and posaconazole), and echinocandins. Caspofungin, the first drug of the latter class, was approved for empirical treatment in febrile neutropenic patients and for first-line therapy of systemic candidiasis and second-line therapy of invasive aspergillosis.<sup>4</sup> The tolerance profile of caspofungin and its minor drug interactions favour its use in high-risk neutropenic patients with comorbidities. Posaconazole has been adopted for primary IFI prophylaxis for patients undergoing induction chemotherapy for AML or myelodysplasia and those with graft-vs.-host disease following allo-HSCT after two large-scale, randomised studies have demonstrated a benefit for patients at high risk for contracting IFI.<sup>5</sup> Natural or acquired resistance of some filamentous fungi is an important concern, both in the setting of empirical or primary prophylactic antifungal treatment of haematological patients.

Invasive fungal infections caused by zygomycetes, *Fusarium* spp. and *Scedosporium apiospermum* are breakthrough mould infections associated with a high mortality rate.<sup>6</sup> Mucormycosis occurrence in the haematological malignancy setting independently predicts fatal outcome.<sup>7</sup> Several clusters of cases of *Geotrichum clavatum* infection – a fungus intrinsically resistant to echinocandins – have also been reported in France between 2011 and 2012 in the haematological

malignancy setting.<sup>8</sup> Other breakthrough infections such as basidiomycetes, including *Cryptococcus* spp. and *Trichosporon* spp., have become clinically significant as well. The first case of human *H. aspergillata* infection was reported by The Centraalbureau voor Schimmelcultures (Baarn, The Netherlands) in 1996, which collected *Hormoglyphiella* isolates from *postmortem* organ specimens, strongly suggesting the invasive pattern.<sup>9</sup> Since then, 11 cases of invasive *H. aspergillata* infections have been described, mostly in neutropenic patients due to haematological conditions with an overall related case-fatality rate of 80%.<sup>10,11</sup> Lung is the most frequent site of involvement as CT-scan usually reveals diffuses nodules and halo sign. Skin localisation is the second most frequent site with a presentation of torpid ulcero-necrotic lesions.<sup>10–16</sup> Single cases of endocarditis and endophthalmitis have been reported as well.<sup>17,18</sup> Late-stage complications are massive blood dissemination and CNS infiltration.<sup>10,12,16</sup> Finally, coinfection with another invasive mould was documented in two cases, which could be related to the severely immunocompromised profiles of these patients.<sup>12,13</sup>

The susceptibility of basidiomycetes to available antifungal agents is not well established. They are intrinsically resistant to echinocandins, show variable susceptibility to amphotericin B, and generally susceptible to azoles with the exception of fluconazole.<sup>19,20</sup> As previously described in other studies, the major factor that significantly influenced survival was neutrophil recovery.<sup>10</sup> In a reported case of CNS co-infection by *Rhizomucor variabilis* and *H. aspergillata*, combination of caspofungin and L-AmB were synergistic *in vitro*, but effectiveness of this therapy in patient's neurological status was unclear based on available data.<sup>12</sup> A recent multicentre observational study addressed the safety of antifungal combination therapy showing the absence of undesirable events > grade II WHO in first line with promising survival results (ORR = 73%, IFIs-attributable mortality = 17%).<sup>21</sup> The benefit of combined therapy still has to be demonstrated and is still used as a salvage therapy in severe invasive mould infections.

In mucormycosis, surgery is part of the therapeutic management with the report of improved cure and survival rates in a retrospective analysis of 101 patients with mucormycosis with a 70% rate of rhino-cerebral involvement.<sup>22</sup> Surgical debridement can locally decrease the fungal burden, prevent the extension to adjacent structures but also allow tissue sampling for diagnostic purpose. A study performed on 11 immunocompromised patients with fungal rhino-sinusitis

assessed that early diagnosis and combination of L-AmB and radical resection was associated with improved outcome.<sup>23</sup> Regarding *H. aspergillata*, surgical resection has been performed in one case of necrotic cutaneous lesion.<sup>10</sup> Our patient improved with an optimised medico-surgical approach requiring two surgical resections. It is our belief that prompt surgery should be part of the management of invasive sino-orbital breakthrough fungal infection in the haematological setting.

## Conclusion

Sino-orbito-cerebral breakthrough fungal infections may arise during empirical echinocandin treatment in chronic neutropenia. As prognosis is driven by early treatment, an aggressive surgical debridement in addition of a potent antifungal drug regimen should be rapidly considered in this setting.

## Competing interests

The authors declare that they have no competing interests.

## Author contributions

MH, MM and FA wrote the paper. MH, MM, FA, VB, JS, XT and SDL were the physicians involved in patient clinical course. DCD, ATG, AC, AA, DD, ALB and SDL contributed essential reagents or tools. CC and TF provided a critical revision of the manuscript. All authors have read and approved the final manuscript.

## References

- 1 Neofytos D, Horn D, Anaissie E *et al.* Epidemiology and outcome of invasive fungal infection in adult hematopoietic stem cell transplant recipients: analysis of Multicenter Prospective Antifungal Therapy (PATH) Alliance registry. *Clin Infect Dis* 2009; **48**: 265–73.
- 2 de Hoog GS, Guarro J, Gené J, Figueras MJ. *Atlas of Clinical Fungi*, 3rd edn. Utrecht: CBS, 2009.
- 3 Alanio A, Romand S, Penso-Assathiany D, Foulet F, Botterel F. *Microsporium praecox*: molecular identification of a new case and review of the literature. *Mycopathologia* 2011; **171**: 61–65.
- 4 Maertens J, Raad I, Petrikos G *et al.* Caspofungin Salvage Aspergillosis Study Group. Efficacy and safety of caspofungin for treatment of invasive aspergillosis in patients refractory to or intolerant of conventional antifungal therapy. *Clin Infect Dis* 2004; **39**: 1563–71.
- 5 Maertens J, Marchetti O, Herbrecht R *et al.* Third European Conference on Infections in Leukemia. European guidelines for antifungal management in leukemia and hematopoietic stem cell transplant recipients: summary of the ECIL 3-2009 update. *Bone Marrow Transplant* 2011; **46**: 709–18.
- 6 Lass-Flörl C. The changing face of epidemiology of invasive fungal disease in Europe. *Mycoses* 2009; **52**: 197–205.
- 7 Petrikos G, Skiada A, Lortholary O, Roilides E, Walsh TJ, Kontoyiannis DP. Epidemiology and clinical manifestations of mucormycosis. *Clin Infect Dis* 2012; **54**(Suppl. 1): 23–34.

- 8 Picard M, Cassaing S, Letocart P *et al.* Concomitant cases of disseminated *Geotrichum clavatum* infections in patients with acute myeloid leukemia. *Leuk Lymphoma* 2014; **55**: 1186–8.
- 9 De Hoog GS, Kuijpers AFA, van den Tweel K. Zeldzame schimmels: doodgewoon? *Ned Tijdschr Med Microbiol* 1998; **5**: 32–35.
- 10 Suarez F, Olivier G, Garcia-Hermoso D *et al.* Breakthrough *Hormographiella aspergillata* infections arising in neutropenic patients treated empirically with caspofungin. *J Clin Microbiol* 2011; **49**: 461–5.
- 11 Conen A, Weisser M, Hohler D, Frei R, Stern M. *Hormographiella aspergillata*: an emerging mould in acute leukaemia patients? *Clin Microbiol Infect* 2011; **17**: 273–7.
- 12 Abuali MM, Posada R, Del Toro G *et al.* *Rhizomucor variabilis* var. *regularior* and *Hormographiella aspergillata* infections in a leukemic bone marrow transplant recipient with refractory neutropenia. *J Clin Microbiol* 2009; **47**: 4176–9.
- 13 Nenoff P, Friedrich T, Schwenke H *et al.* Rare fatal simultaneous mould infection of the lung caused by *Aspergillus flavus* and the basidiomycete *Coprinus* sp. in a leukemic patient. *J Med Vet Mycol* 1997; **35**: 65–69.
- 14 Lagrou K, Massonet C, Theunissen K *et al.* Fatal pulmonary infection in a leukaemic patient caused by *Hormographiella aspergillata*. *J Med Microbiol* 2005; **54**: 685–8.
- 15 Surmont I, Van Aelst F, Verbanck J, De Hoog GS. A pulmonary infection caused by *Coprinus cinereus* (*Hormographiella aspergillata*) diagnosed after a neutropenic episode. *Med Mycol* 2002; **40**: 217–9.
- 16 Verweij PE, van Kasteren M, van de Nes J *et al.* Fatal pulmonary infection caused by the basidiomycete *Hormographiella aspergillata*. *J Clin Microbiol* 1997; **35**: 2675–8.
- 17 Bartz-Schmidt KU, Tintelnot K, Steffen M *et al.* Chronic basidiomycetous endophthalmitis after extracapsular cataract extraction and intraocular lens implantation. *Graefes Arch Clin Exp Ophthalmol* 1996; **234**: 591–3.
- 18 Speller DCE, MacIver AG. Endocarditis caused by a *Coprinus* species: a fungus of the toadstool group. *J Med Microbiol* 1971; **4**: 370–4.
- 19 Arendrup MC, Boekhout T, Akova M, Meis JF, Cornely OA, Lortholary O; ESCMID EFISG study group and ECMM. ESCMID and ECMM joint clinical guidelines for the diagnosis and management of rare invasive yeast infections. *Clin Microbiol Infect* 2014; **20**(Suppl. 3): 76–98.
- 20 Gené J, Guillamón JM, Guarro J, Pujol I, Ullig K. Molecular characterization, relatedness and fungal susceptibility of the basidiomycetous *Hormographiella* species and *Coprinus cinereus* from clinical and environmental sources. *Antonie Van Leeuwenhoek* 1996; **70**: 49–57.
- 21 Candoni A, Caira M, Cesaro S *et al.* Multicentre surveillance study on feasibility, safety and efficacy of antifungal combination therapy for proven or probable invasive fungal diseases in haematological patients: the SEIFEM real-life combo study. *Mycoses* 2014; **57**: 342–50.
- 22 Lantermier F, Dannaoui E, Morizot G *et al.* French Mycosis Study Group. A global analysis of mucormycosis in France: the RetroZygo Study (2005–2007). *Clin Infect Dis* 2012; **54**(Suppl. 1): 35–43.
- 23 Anselmo-Lima WT, Lopes RP, Valera FC, Demarco RC. Invasive fungal rhinosinusitis in immunocompromised patients. *Rhinology* 2004; **42**: 141–4.