



Whole exome sequencing identifies mutations in Usher syndrome genes in profoundly deaf Tunisian patients.

Zied Riahi, Crystel Bonnet, Rim Zainine, Saida Lahbib, Yosra Bouyacoub, Rym Bechraoui, Jihène Marrakchi, Jean-Pierre Hardelin, Malek Louha, Leila Lagueche, et al.

► To cite this version:

Zied Riahi, Crystel Bonnet, Rim Zainine, Saida Lahbib, Yosra Bouyacoub, et al.. Whole exome sequencing identifies mutations in Usher syndrome genes in profoundly deaf Tunisian patients.. PLoS ONE, 2015, 10 (3), pp.e0120584. 10.1371/journal.pone.0120584 . pasteur-01221041

HAL Id: pasteur-01221041

<https://pasteur.hal.science/pasteur-01221041>

Submitted on 27 Oct 2015

HAL is a multi-disciplinary open access archive for the deposit and dissemination of scientific research documents, whether they are published or not. The documents may come from teaching and research institutions in France or abroad, or from public or private research centers.

L'archive ouverte pluridisciplinaire **HAL**, est destinée au dépôt et à la diffusion de documents scientifiques de niveau recherche, publiés ou non, émanant des établissements d'enseignement et de recherche français ou étrangers, des laboratoires publics ou privés.



Distributed under a Creative Commons Attribution 4.0 International License

RESEARCH ARTICLE

Whole Exome Sequencing Identifies Mutations in Usher Syndrome Genes in Profoundly Deaf Tunisian Patients

Zied Riahi^{1,2}, Crystel Bonnet³, Rim Zainine⁴, Saida Lahbib¹, Yosra Bouyacoub^{1,5}, Rym Bechraoui⁴, Jihène Marrakchi⁴, Jean-Pierre Hardelin⁶, Malek Louha⁷, Leila Lagueche⁸, Salim Ben Yahia⁹, Moncef Kheirallah⁹, Leila Elmati⁸, Ghazi Besbes⁴, Sonia Abdelhak^{1*}, Christine Petit^{3,6,10}

1 Institut Pasteur de Tunis, LR11IPT05, Biomedical Genomics and Oncogenetics Laboratory, 1002, Tunis, Tunisia, **2** Faculté des Sciences de Tunis, Université de Tunis El Manar, 2092 El Manar I Tunis, Tunisia, **3** Institut de la Vision, INSERM UMRS 1120, UPMC- Paris 6, Paris, France, **4** La Rabta Hospital, Otorhinolaryngology Diseases, Tunis, Tunisia, **5** Université de Monastir, Institut Supérieur de Biotechnologie, Monastir, Tunisia, **6** Institut Pasteur, Unité de Génétique et Physiologie de l'Audition, Paris, France, **7** Laboratoire de Biochimie et de Biologie Moléculaire, Hôpital Armand Trousseau, APHP, Paris, France, **8** Department B of Ophthalmology, Hedi Rais Institute of Ophthalmology, Tunis, Tunisia, **9** Université de Monastir, Faculty of Medicine, Fattouma Bourguiba University Hospital, Department of Ophthalmology, 5000, Monastir, Tunisia, **10** Collège de France, Paris, France

* sonia.abdelhak@pasteur.rns.tn



OPEN ACCESS

Citation: Riahi Z, Bonnet C, Zainine R, Lahbib S, Bouyacoub Y, Bechraoui R, et al. (2015) Whole Exome Sequencing Identifies Mutations in Usher Syndrome Genes in Profoundly Deaf Tunisian Patients. PLoS ONE 10(3): e0120584. doi:10.1371/journal.pone.0120584

Academic Editor: Knut Stieger, Justus-Liebig-University Giessen, GERMANY

Received: October 6, 2014

Accepted: January 24, 2015

Published: March 23, 2015

Copyright: © 2015 Riahi et al. This is an open access article distributed under the terms of the [Creative Commons Attribution License](https://creativecommons.org/licenses/by/4.0/), which permits unrestricted use, distribution, and reproduction in any medium, provided the original author and source are credited.

Data Availability Statement: In Tunisia, genetic data are considered as personal private data, for these reasons we have submitted the minimal dataset as supporting files but we are not allowed to submit the full raw data. The full raw data may be made available upon request by other investigators and after approval of our IRB.

Funding: This work was supported by the Tunisian Ministry of Public Health, the Ministry of Higher Education and Scientific Research (LR11IPT05), the E.C. Grant agreement N° 295097 for FP7 project GM-NCD-Inco (www.genomedika.org), ZR is

Abstract

Usher syndrome (USH) is an autosomal recessive disorder characterized by combined deafness-blindness. It accounts for about 50% of all hereditary deafness blindness cases. Three clinical subtypes (USH1, USH2, and USH3) are described, of which USH1 is the most severe form, characterized by congenital profound deafness, constant vestibular dysfunction, and a prepubertal onset of retinitis pigmentosa. We performed whole exome sequencing in four unrelated Tunisian patients affected by apparently isolated, congenital profound deafness, with reportedly normal ocular fundus examination. Four biallelic mutations were identified in two USH1 genes: a splice acceptor site mutation, c.2283-1G>T, and a novel missense mutation, c.5434G>A (p.Glu1812Lys), in *MYO7A*, and two previously unreported mutations in *USH1G*, i.e. a frameshift mutation, c.1195_1196delAG (p.Leu399Alafs*24), and a nonsense mutation, c.52A>T (p.Lys18*). Another ophthalmological examination including optical coherence tomography actually showed the presence of retinitis pigmentosa in all the patients. Our findings provide evidence that USH is underdiagnosed in Tunisian deaf patients. Yet, early diagnosis of USH is of utmost importance because these patients should undergo cochlear implant surgery in early childhood, in anticipation of the visual loss.

recipient of a Mobidoc Fellowship under the Programme d'Appui au Système de recherche et d'Innovation (PASRI-Europe Aid) and BNP Paribas foundation. The funders had no role in study design, data collection and analysis, decision to publish, or preparation of the manuscript.

Competing Interests: The authors have declared that no competing interests exist.

Introduction

Deafness is the most common birth defect and the most frequent sensorineural disorder [1]. It affects 1.9 per 1000 infants at birth, and its prevalence is 2.7 per 1000 in four year old children [2]. More than 50% of congenital deafness cases have a genetic cause, of which about one third corresponds to syndromic deafness [3]. More than 400 syndromes including deafness have been described [4]. Usher syndrome (USH) is an autosomal recessive disorder characterized by combined deafness-blindness, and accounts for approximately 50% of all hereditary deafness-blindness cases [5]. The prevalence of USH is estimated at 3 to 6/100,000 [6]. Three clinical subtypes (USH1, USH2, and USH3) are distinguished according to the severity and progression of deafness, presence or absence of vestibular dysfunction, and age at onset of the visual loss due to retinitis pigmentosa (RP) [7]. USH1 is the most severe form, characterized by congenital profound deafness, constant vestibular dysfunction, and a pre-pubertal onset of RP. Six USH1 genes have been identified: *MYO7A*, *CDH23*, *PCDH15*, *USH1C*, *USH1G*, and *CIB2*, encoding myosin VIIA, cadherin-23, protocadherin-15, harmonin, sans, and calcium- and integrin-binding protein 2, respectively [8,9]. Since next generation sequencing techniques currently allow rapid and cost-effective identification of the causative mutations in deaf patients [10,11], we carried out whole exome sequencing (WES) analysis in four unrelated Tunisian patients affected by apparently isolated, congenital profound deafness, who did not carry a bi-allelic mutation in the most commonly involved gene *GJB2*. Much to our surprise, we thereby identified bi-allelic mutations in USH1 genes in the four patients.

Patients and Methods

Patients

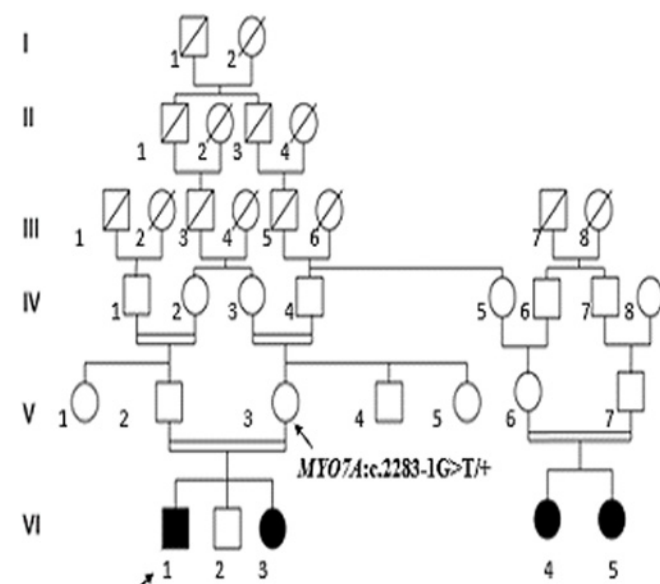
Four unrelated Tunisian families including one or several deaf individuals (DF11, DF25, DF99, and DF103) were studied (Fig. 1). The patients were referred from the Otorhinolaryngology Department at La Rabta University hospital in Tunis. They underwent the following clinical investigations and audiological evaluation: tympanometry, auditory brainstem response, computed tomography of the temporal bones, magnetic resonance imaging of the inner ear, ocular fundus examination, cardiac and renal ultrasonography. All the patients had bilateral profound deafness. Clinical examination and familial information were unremarkable, and did not reveal symptoms or malformations that would suggest a syndromic form of deafness. Written informed consent was obtained from the parents of all participants to the study.

Ethics statement

This study has obtained the ethics approval (IPT/ LR11-05/Etude/05/2013) from the institutional review board of Pasteur Institute (Tunis- Tunisia- Registration number IRB00005445, FWA00010074). This study was conducted according to the principles of the declaration of Helsinki. Patients were anonymized and the corresponding code was conserved in a confidential file.

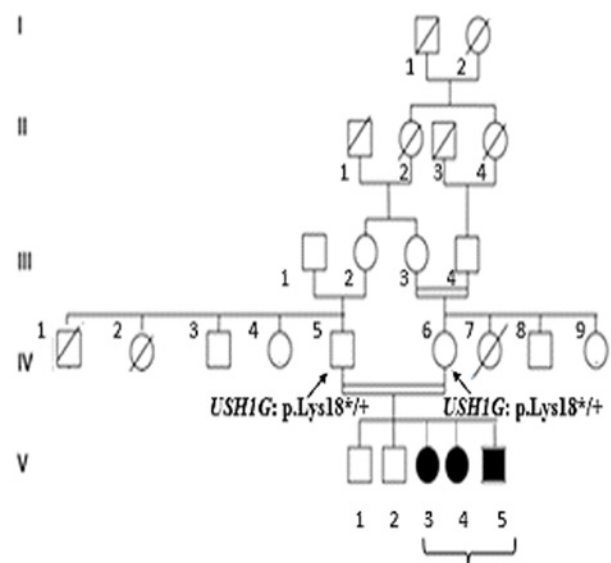
Prescreening of *GJB2* mutations and whole exome sequencing

Genomic DNA was extracted from peripheral blood samples using the standard salting-out method [12]. First, the entire coding region of *GJB2* and flanking splice acceptor site was analyzed by Sanger sequencing in one patient of each family, i.e. DF11-VI.1, DF25-V.3, DF99-IV.1, and DF103-III.2, aged 6, 20 (with severe intellectual deficiency), 4 and 1 years, respectively [13]. These patients then underwent WES on Illumina HiSeq2000 platform (Illumina: Evry, France) using Agilent Sure Select Human All Exon v2 enrichment kit. Image



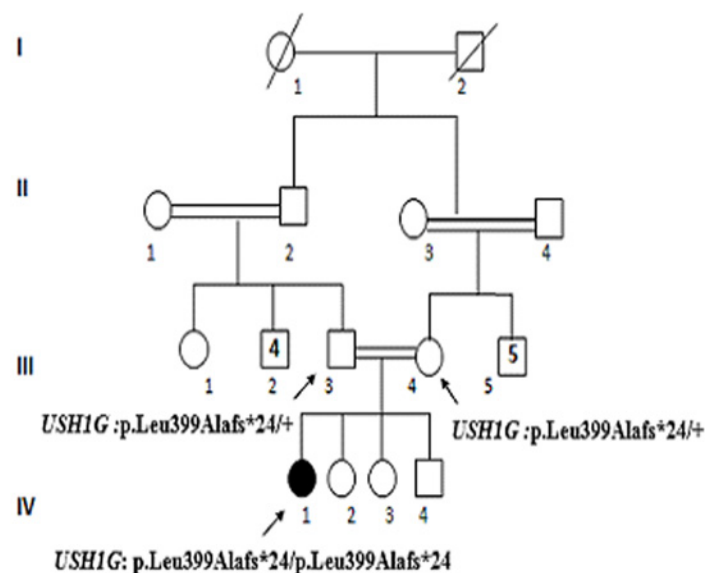
MYO7A:c.2283-1G>T/c.2283-1G>T

Family DF11

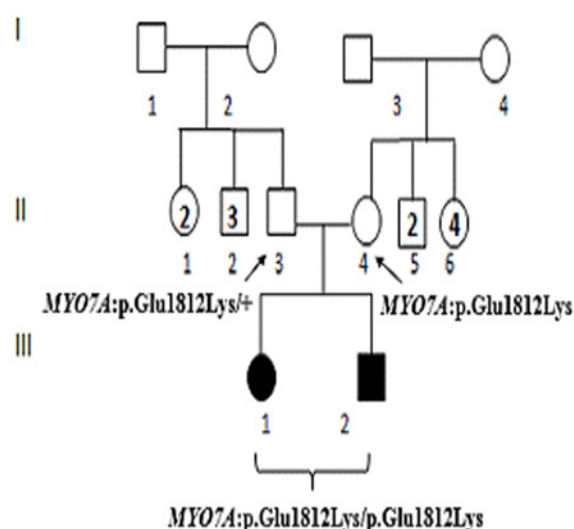


USH1G:p.Lys18*/p.Lys18*

Family DF25



Family DF99



Family DF103

Fig 1. Pedigrees of the four Tunisian patients analyzed by whole exome sequencing. Squares and circles denote males and females, respectively. Filled symbols indicate deaf individuals. Arrows indicate the individuals analyzed by WES.

doi:10.1371/journal.pone.0120584.g001

analysis and base calling were performed using the Illumina Real-Time Analysis Pipeline version 1.14 with default parameters. Bioinformatic analysis was based on the Illumina pipeline (CASAVA 1.8) which aligns reads to the human reference genome (hg19) with the alignment algorithm ELANDv2 (it performs multispeed and gapped alignments). Genetic variation was annotated with the IntegraGen in-house pipeline [10,14]. We achieved an average percentage of 95% of covered CCDS (Consensus Coding DNA Sequence) at 10X and 90% at 25X. The mutations identified in *MYO7A* and *USH1G* were confirmed by Sanger sequencing of the corresponding exons, using primers designed with Primer3 (<http://primer3.ut.ee/>) (sequences are available on request).

Results and Discussion

According to familial information, all the patients started to walk later than normal, at about two years of age, and had balance problems, indicating vestibular dysfunction. Because of the association of profound congenital deafness and vestibular dysfunction, suggesting USH, ocular fundus examination was carried out in the patients, but abnormal findings were not reported.

Screening for mutations in *GJB2*, the gene most frequently involved in autosomal recessive deafness in Tunisia [13], by Sanger sequencing, showed that patient DF99-IV.1 carried the c.35delG mutation in the heterozygous state, whereas the other three patients were homozygous for the normal allele. WES was therefore carried out in the four patients. Based on familial history and parental consanguinity, we hypothesized that the causal mutations would be present at the homozygous state at least in three patients, and possibly at the compound heterozygous state in patient DF103-III.2, who was born to presumably unrelated parents. In the bioinformatic analysis of the results, we first excluded all the sequence variants reported in dbSNP132, 1000 genomes, Hapmap, and Exome Variant Server databases. In the second step, we focused on variants present in the coding exons and flanking splice sites. From the SNV and indel files, we selected nonsense, frame-shifting (indels), missense, and splice site mutations, as they were more likely to be pathogenic. Only the variants with a read depth greater than 5 were retained. An average of 71967 SNV and 5544 indels were found for each patient. After the filtering steps, these variants were reduced to 4 SNVs and 0 indel for patient DF25-V.3, 7 SNVs and 2 indels for patient DF11-VI.1, 12 SNVs and 2 indels for DF99-IV.1 and 2 SNVs and 1 indel for patient DF103-III.2 (S1 Table). No mutations were identified in the compound heterozygous state in any of these patients.

Much to our surprise, the bi-allelic mutations predicted to be pathogenic were all located in two *USH1* genes. In patient DF11-VI.1, a splice site mutation (c.2283-1G>T) was identified in *MYO7A* (NM_001127180). This mutation has previously been reported in *USH1* patients from Algeria, Morocco and France [15], but not from Tunisia. According to Alamut 2.3 software (<http://www.interactive-biosoftware.com>), it is predicted to abolish the splice acceptor site of intron 19 and to create a cryptic acceptor site 1 bp upstream of the original site, which could result in skipping of exon 20 in the mature transcript. In patient DF103-III.2, a previously unreported missense mutation, c.5434G>A (p.Glu1812Lys), was identified in exon 39 of the same gene (*MYO7A*: NM_000260). This mutation is predicted to have a deleterious effect on the protein by SIFT (<http://sift.jcvi.org/>) and Mutation Taster (<http://www.mutationtaster.org/>). In patients DF25-V.3 and DF99-IV.1, a nonsense mutation, c.52A>T (p.Lys18*), and a frameshift mutation, c.1195_1196delAG (p.Leu399Alafs*24), were identified in exon 1 and 2 of *USH1G* (NM_173477), respectively. According to Alamut 2.3, these truncating mutations are expected to result in the absence of synthesized protein due to mRNA nonsense mediated

decay. None of the pathogenic identified mutations were described in ExAC project (last update 29 October 2014) (<http://exac.broadinstitute.org/>)

The presence of the mutations in the heterozygous state was shown by Sanger sequencing in all the clinically unaffected parents, except the father of patient DF11-VI.1, whose DNA was not available. We were also able to confirm the presence of the mutations, in the homozygous state, in the affected siblings of patients DF25-V.3 and DF103-III.2.

The four studied cases were a part of a group of 10 deaf families negative for *GJB2* mutations with a positive history of hearing loss which underwent WES: eight biallelic mutations were identified in 8 families (80% of resolved cases); four of them correspond to new mutations in genes responsible for isolated deafness [10], four had mutations in genes involved in Usher syndrome (this study) and two families were not resolved.

Because mutations in *MYO7A* and *USH1G* are associated with USH1, the patients underwent another ophthalmological examination, including optical coherence tomography (OCT) imaging (Fig. 2), and bilateral peripheral RP was diagnosed in all the patients examined, i.e., DF11-VI.1, DF11-VI.3, DF25-V.3, DF25-V.4, DF25-V.5, DF99-IV.1, DF103-III.1, and DF103-III.2.

The fact that previous routine ocular fundus examination did not detect the abnormal retinal pigmentation in any of the affected children is likely due to the presence of minor undetectable anomalies at the time when these children were first examined or to the fact that ophthalmologists are not familiar with peripheral alterations of the retina as they usually focus on the central retina and to the difficulty of making a good fundus examination in children because of absent cooperativity. Other efficient ophthalmological tests such as electroretinography and OCT imaging are needed for USH diagnosis in early childhood, but the availability of the corresponding equipment is generally limited to tertiary health centers. However, it is of utmost importance to raise awareness about the possibility that congenital deafness reveals USH, because early diagnosis of this dual sensory disorder is crucial and urges on cochlear implant in the affected children. In this respect, combining advanced ophthalmological evaluation, including funduscopy with careful examination of the peripheral retina and electroretinogram in selected cases, together with molecular diagnosis by targeted USH exome sequencing [16] or WES (this study) could be a powerful strategy.

Supporting Information

S1 Table. List of the bi-allelic mutations retained from the whole exome sequences after the filtering steps.

(PDF)

Acknowledgments

We would like to thank the patients and their families for their collaboration. We are grateful to the technical staff at Armand Trousseau Hospital in Paris for their assistance.

Author Contributions

Conceived and designed the experiments: SA CP. Performed the experiments: ZR CB YB SL. Analyzed the data: ZR CB. Contributed reagents/materials/analysis tools: ML. Wrote the paper: ZR. Contributed in the critical revision of the manuscript for important intellectual content: JPH CB SA CP. Clinical evaluations of patients: RB JM SBY MK RZ GB LE LL.

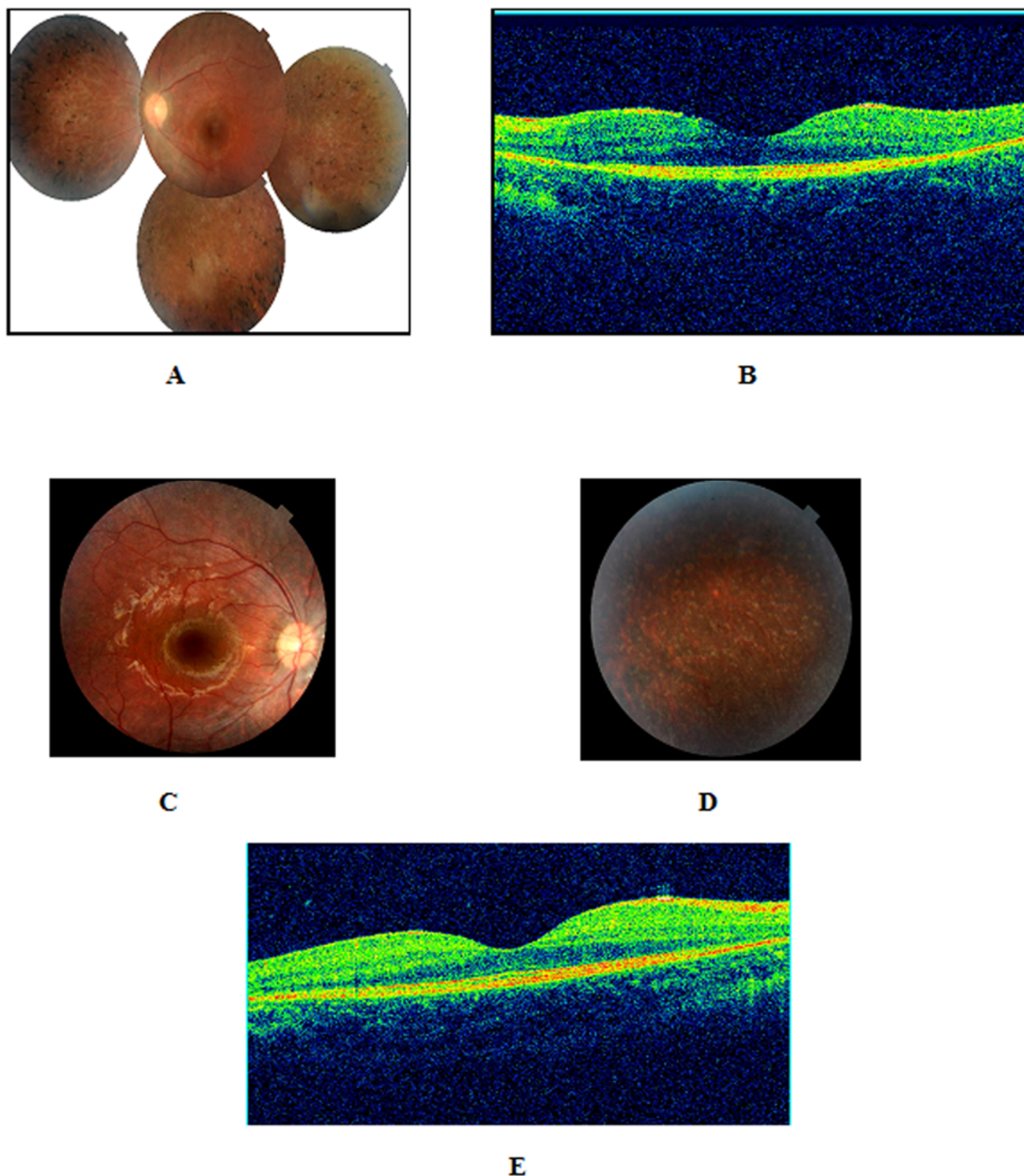


Fig 2. Retinal phenotypes of patients with mutations in Usher genes. **A**, Composite color fundus photograph of the left eye of a four-year-old girl (DF103-III-2) showing diffuse narrowing of the retinal arteries and hyperpigmentation in a bone-spicule configuration in the midperipheral retina. **B**, B-scan OCT imaging of the same eye showing a mild foveal atrophy (central macular thickness = 160 micrometers). **C**, Color fundus photograph of the posterior pole of the right eye of a six-year-old boy (DF103-III-1) with early stage retinitis pigmentosa shows no obvious abnormalities which may explain the misdiagnosis of the disease in some cases. **D**, Color fundus photograph of the peripheral retina showing a "salt and pepper" appearance without the classical bone-spicule pigmentation. **E**, The fovea has a normal thickness on optical coherence tomography (180 micrometers).

doi:10.1371/journal.pone.0120584.g002

References

1. Hilgert N, Smith RJ, Van Camp G. Forty-six genes causing nonsyndromic hearing impairment: which ones should be analyzed in DNA diagnostics?. *Mutat Res*. 2009; 681: 189–196. doi: [10.1016/j.mrrev.2008.08.002](https://doi.org/10.1016/j.mrrev.2008.08.002) PMID: [18804553](https://pubmed.ncbi.nlm.nih.gov/18804553/)
2. Morton CC, Nance WE. Newborn hearing screening—a silent revolution. *N Engl J Med*. 2006; 354: 2151–2164. PMID: [16707752](https://pubmed.ncbi.nlm.nih.gov/16707752/)
3. Woo HM, Park HJ, Baek JI, Park MH, Kim UK, et al. Whole-exome sequencing identifies MYO15A mutations as a cause of autosomal recessive nonsyndromic hearing loss in Korean families. *BMC Med Genet*. 2013; 14: 72. doi: [10.1186/1471-2350-14-72](https://doi.org/10.1186/1471-2350-14-72) PMID: [23865914](https://pubmed.ncbi.nlm.nih.gov/23865914/)
4. Smith RJH, Shearer AE, Hildebrand MS, Van Camp G. Deafness and Hereditary Hearing Loss Overview. In: Pagon RA, Adam MP, Bird TD, Dolan CR, Fong CT et al., editors. *GeneReviews*. 1993; Seattle (WA).
5. Bonnet C, El-Amraoui A. Usher syndrome (sensorineural deafness and retinitis pigmentosa): pathogenesis, molecular diagnosis and therapeutic approaches. *Curr Opin Neurol*. 2012; 25: 42–49. doi: [10.1097/WCO.0b013e32834ef8b2](https://doi.org/10.1097/WCO.0b013e32834ef8b2) PMID: [22185901](https://pubmed.ncbi.nlm.nih.gov/22185901/)
6. Kimberling WJ, Hildebrand MS, Shearer AE, Jensen ML, Halder JA, et al. Frequency of Usher syndrome in two pediatric populations: Implications for genetic screening of deaf and hard of hearing children. *Genet Med*. 2010; 12: 512–516. doi: [10.1097/GIM.0b013e328181e5afb8](https://doi.org/10.1097/GIM.0b013e328181e5afb8) PMID: [20613545](https://pubmed.ncbi.nlm.nih.gov/20613545/)
7. Saihan Z, Webster AR, Luxon L, Bitner-Glindzicz M. Update on Usher syndrome. *Curr Opin Neurol*. 2009; 22: 19–27. PMID: [19165952](https://pubmed.ncbi.nlm.nih.gov/19165952/)
8. Millan JM, Aller E, Jaijo T, Blanco-Kelly F, Gimenez-Pardo A, Ayuso C. An update on the genetics of usher syndrome. *J Ophthalmol*. 2011; 417217. doi: [10.1155/2011/417217](https://doi.org/10.1155/2011/417217) PMID: [21234346](https://pubmed.ncbi.nlm.nih.gov/21234346/)
9. Riazuddin S, Belyantseva IA, Giese AP, Lee K, Indzhukulian AA, et al. Alterations of the CIB2 calcium- and integrin-binding protein cause Usher syndrome type 1J and nonsyndromic deafness DFNB48. *Nat Genet*. 2012; 44: 1265–1271. doi: [10.1038/ng.2426](https://doi.org/10.1038/ng.2426) PMID: [23023331](https://pubmed.ncbi.nlm.nih.gov/23023331/)
10. Riahi Z, Bonnet C, Zainine R, Louha M, Bouyacoub Y, et al. Whole exome sequencing identifies new causative mutations in tunisian families with non-syndromic deafness. *PLoS One*. 2014; e99797. doi: [10.1371/journal.pone.0099797](https://doi.org/10.1371/journal.pone.0099797) PMID: [24926664](https://pubmed.ncbi.nlm.nih.gov/24926664/)
11. Bonnet C, Louha M, Loundon N, Michalski N, Verpy E, et al. Biallelic nonsense mutations in the otogelin-like gene (OTOGL) in a child affected by mild to moderate hearing impairment. *Gene*. 2013; 527: 537–540. doi: [10.1016/j.gene.2013.06.044](https://doi.org/10.1016/j.gene.2013.06.044) PMID: [23850727](https://pubmed.ncbi.nlm.nih.gov/23850727/)
12. Miller SA, Dykes DD, Polesky HF. A simple salting out procedure for extracting DNA from human nucleated cells. *Nucleic Acids Res*. 1988; 16: 1215. PMID: [3344216](https://pubmed.ncbi.nlm.nih.gov/3344216/)
13. Riahi Z, Hammami H, Ouragini H, Messai H, Zainine R, et al. Update of the spectrum of GJB2 gene mutations in Tunisian families with autosomal recessive nonsyndromic hearing loss. *Gene*. 2013; 525: 1–4. doi: [10.1016/j.gene.2013.04.078](https://doi.org/10.1016/j.gene.2013.04.078) PMID: [23680645](https://pubmed.ncbi.nlm.nih.gov/23680645/)
14. Delmaghani S, Aghaie A, Michalski N, Bonnet C, Weil D, Petit C. Defect in the gene encoding the EAR/ EPTP domain-containing protein TSPEAR causes DFNB98 profound deafness. *Hum Mol Genet*. 2012; 21: 3835–3844. doi: [10.1093/hmg/dds212](https://doi.org/10.1093/hmg/dds212) PMID: [22678063](https://pubmed.ncbi.nlm.nih.gov/22678063/)
15. Roux AF, Faugere V, Vache C, Baux D, Besnard T, et al. Four-year follow-up of diagnostic service in USH1 patients. *Invest Ophthalmol Vis Sci*. 2011; 52: 4063–4071.
16. Bonnet C, Grati M, Marlin S, Levilliers J, Hardelin JP, et al. Complete exon sequencing of all known Usher syndrome genes greatly improves molecular diagnosis. *Orphanet J Rare Dis*. 2011; 6: 21. doi: [10.1186/1750-1172-6-21](https://doi.org/10.1186/1750-1172-6-21) PMID: [21569298](https://pubmed.ncbi.nlm.nih.gov/21569298/)